

Kluver-Bucy Syndrome Following Recovery from Transtentorial Herniation

Eugene Rossitch, Enrique J. Carrazana, Richard Ellenbogen & Eben Alexander

To cite this article: Eugene Rossitch, Enrique J. Carrazana, Richard Ellenbogen & Eben Alexander (1989) Kluver-Bucy Syndrome Following Recovery from Transtentorial Herniation, British Journal of Neurosurgery, 3:4, 503-506, DOI: [10.3109/02688698909002837](https://doi.org/10.3109/02688698909002837)

To link to this article: <http://dx.doi.org/10.3109/02688698909002837>



Published online: 06 Jul 2009.



Submit your article to this journal [↗](#)



Article views: 2



View related articles [↗](#)

SHORT REPORT

Kluver-Bucy Syndrome Following Recovery from Transtentorial Herniation

EUGENE ROSSITCH, JR* ENRIQUE J. CARRAZANA,** RICHARD ELLENBOGEN* & EBEN ALEXANDER III*

Divisions of Neurosurgery and Neurology** Brigham and Women's Hospital Harvard Medical School Boston, Massachusetts, U.S.A.*

Abstract

Kluver-Bucy syndrome is an uncommon constellation of behavioral abnormalities resulting from bilateral temporal lobe damage. The syndrome is rare in humans. In this paper we present a patient who developed the Kluver-Bucy syndrome following recovery from an intracerebral haemorrhage and transtentorial herniation.

Key words: *Kluver-Bucy syndrome, temporal lobe, transtentorial herniation*

Introduction

A century ago, Brown and Schafer described behavioral changes occurring after bilateral temporal lobectomy in primates¹. However, it was through work of Kluver and Bucy that a new constellation of symptoms now known as the Kluver-Bucy syndrome (KBS) was identified^{2,3}.

In primates, the complete expression of the syndrome consists of the following:

1. 'Psychic blindness' which is defined as the inability to use visual clues to appreciate the significance of different objects.
2. An increase in the frequency and diversity of sexual activity.
3. Changes in emotional behaviour.
4. Oral tendencies— the animals continuously examine objects by placing them in their mouth.
5. 'Hypermetamorphosis'— an excessive tendency to take notice of and to react to every visual stimulus.

6. Increased appetite.

7. Placidity.

8. Memory difficulties may also develop— Kluver and Bucy observed that monkeys had difficulty learning form-board tasks.

The first identification of a human KBS was made in 1955 by Terzian and Dalle Ore in a seizure patient treated with bilateral temporal lobectomies⁴. Over 100 cases of 'partial' or 'complete' KBS have now been reported in adults following bilateral damage to the temporal lobes. Etiologies have included herpes encephalitis⁵⁻⁷, head trauma^{6,8}, Alzheimer's Disease⁶, Pick's Disease^{6,9}, adreno-leukodystrophy¹⁰, acute intermittent porphyria¹¹, and Huntington's Chorea¹². In children, there have been only seven reported cases of KBS^{5,13-16}. The most common etiology in this group is hypoxia. One of us recently reported the case of a child with a partial KBS and bitemporal arachnoid cysts¹⁷. We now report a case of KBS that occurred following recovery from an

intracerebral haemorrhage and transtentorial herniation.

Case Report

E.G. is a 42-year-old Hispanic male who was brought to our institution following a generalised seizure. In the emergency room, he was bradycardic and hypertensive with a blood pressure of 220/140. Neurologic examination revealed an unresponsive male who did not move his left side even to painful stimulation. A brain CT scan showed a large, primary intracerebral haemorrhage located with its center in the right putamen (Fig. 1a). There was marked mass effect with effacement of the suprasellar and quadrigeminal plate cisterns. A small amount of blood was visualised in the third and fourth ventricles. Carotid angiography revealed no aneurysm or arteriovenous malformation.

In spite of hyperventillation and manitol, the patient deteriorated over the next 24 h and developed fixed, dilated pupils bilaterally. A repeat CT scan showed increasing dilation of the left temporal horn. The basilar cisterns were no longer visualised (Fig. 1b). From this scan, the diagnosis of impending transtentorial herniation was made.

E.G. was immediately taken to the operating room where he underwent a right frontal craniotomy for evaluation of the haematoma and placement of a ventricular catheter. The patient tolerated the procedure well and had an uncomplicated postoperative course.

One month following the haemorrhage, E.G. was alert and aware of his surroundings. Neurologic examination was remarkable for a left homonymous hemianopsia, a dense left hemiparesis and left hyperreflexia. Language modalities were intact although at times the content of his speech was bizarre. Interestingly, the patient's speech was soft and monotonous, having lost the musical quality of the Central American accent. Short-term memory was impaired (the patient was unable to repeat a simple three-sentence story), but long-term memory seemed relatively intact. At this time,

a follow-up CT scan was performed and is shown in Fig. 1c.

In general, the patient was placid and unconcerned, rarely showing any signs of emotion. He had a very short attention span and was easily distracted. E.G. did not seem to pay special attention to anyone, apparently he was unable to recognise relatives or friends. The patient ate voraciously and tended to place all objects within reach into his mouth (e.g. bedsheets, curtains, spoons, faeces, fingers). E.G. made numerous inappropriate sexual advances towards the nurses taking care of him. These advances were limited to persons of the opposite sex. The patient almost constantly pulled on his foley catheter or stroked his genitals. Masturbation was a frequent occurrence.

The unusual behaviour persisted at the time of discharge to a rehabilitation center two months after admission.

Discussion

The expression of KBS in humans is somewhat different than in animals. As expected, symptoms such as psychic blindness, hypermetamorphosis, hyperorality and aberrant sexuality are manifested differently in humans. Psychic blindness in humans includes the inability to distinguish significant persons such as family members from strangers. Hyperorality often takes the form of hyperphagia, bulimia, or ingestion of inedible objects. Hypermetamorphosis in humans consists of extreme distractibility and frequent exploratory behaviour. Alterations in sexual behaviours are also expressed differently in monkeys and humans. In humans, true copulation or masturbation is infrequent. Rather, sexual overtures and attempted physical contact are more prominent. Finally, complete KBS is rarely observed in humans.

Bilateral temporal lobe damage in humans is usually associated with severe disorders of language, memory, and learning¹⁸. Not surprisingly, memory and language dysfunction occurs commonly in patients with KBS. This defect is obviously not as easy to detect in

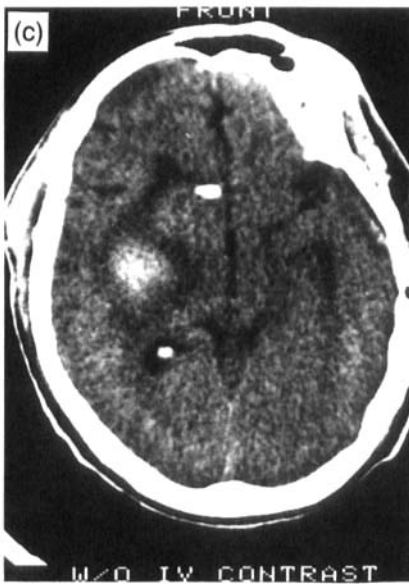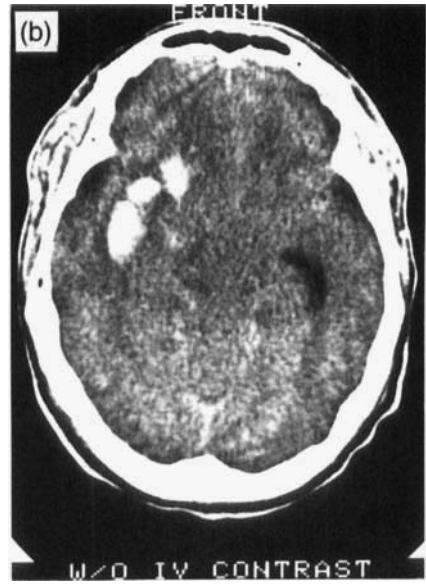

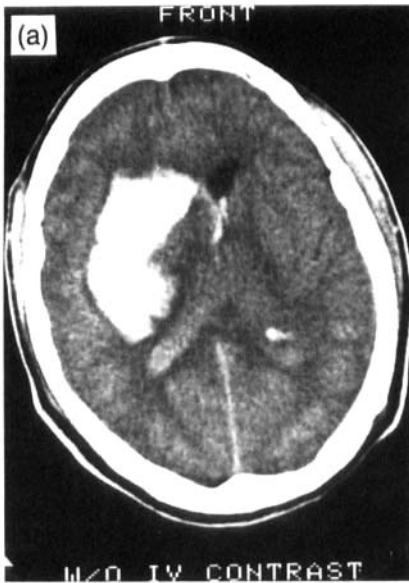
FIG. 1(a) The brain CT scan performed on admission showing a large, primarily intracerebral haemorrhage located with its centre in the right putamen. There is marked mass effect with effacement of the suprasellar and quadrigeminal plate cisterns. (b) A repeat CT scan performed approximately 24 h later after the patient's condition deteriorated. From this scan, the diagnosis of impending transtentorial herniation was made. (c) Follow-up CT scan obtained five weeks after initial presentation.

recognition of persons and objects, a pattern of oral exploration, hyperbulimia, alteration of sexuality, and stereotyped motor mannerisms. In addition, the patient exhibited memory difficulties. In most other reports of human KBS, there is only partial expression of the syndrome. For example, in the paper by Lilly *et al.*⁶, cases were included if they manifested simultaneously, a minimum of only three KBS elements. Our patient appears to exhibit the full syndrome.

monkeys, however, the animals observed by Kluver and Bucy had difficulty learning form-board tasks, suggesting memory difficulties. Our patient had impaired short-term memory as well as some problems with language.

In 1975, Marlowe *et al.*⁷ reported a case of human KBS that was unique in that the patient exhibited all components of the syndrome as defined in the experimental animal: placid demeanor with flat affect, impaired

Transtentorial herniation is the end result of downward displacement of the hemispheres, compressing and then displacing the midbrain through the tentorial notch¹⁹. In our patient, the rapid evacuation of the hematoma probably prevented the brain stem damage that is seen in completed transtentorial herniation. However, it appears that his temporal lobes were damaged by the process as evidenced by his

memory and language difficulties as well as the development of the full Kluver-Bucy syndrome.

Address for correspondence: Eben Alexander III, M.D., Division of Neurosurgery, Brigham and Women's Hospital, 75 Francis Street, Boston, Massachusetts 02115, U.S.A.

References

- 1 Brown S, Schafer EA. An investigation into the functions of the occipital and temporal lobes of the monkey's brain. *Philos Trans R Soc Lond (Biol)* 1989; 179:303-27.
- 2 Kluver H, Bucy PC. An analysis of certain effects of bilateral temporal lobectomy in the rhesus monkey, with special reference to "psychic blindness". *J Psychol* 1938; 5:33-54.
- 3 Kluver H, Bucy PC. Preliminary analysis of functions of the temporal lobes in monkeys. *Arch Neurol Psychiatry* 1939; 42:979-1000.
- 4 Terzian H, Dolle Ore G. Syndrome of Kluver and Bucy reproduced in man by bilateral removal of the temporal lobes. *Neurology (Minneapolis)* 1955; 5:373-80.
- 5 Chutorian AM, Antunes J. Kluver-Bucy syndrome and herpes encephalitis: Case report. *Neurosurgery* 1981; 8:388-90.
- 6 Lilly R, Cummings JL, Benson F, Frankel M. The human Kluver-Bucy syndrome. *Neurology (Cleveland)* 1983; 33:1141-5.
- 7 Marlowe W, Mancall E, Thomas J. Complete Kluver-Bucy syndrome in man. *Cortex* 1975; 11:53-9.

- 8 Gerstenbrand F, Poewe W, Archner F, Saltuari L. Kluver-Bucy syndrome in man: Experience with post-traumatic cases. *Neurosci Biobehav Rev* 1983; 7:413-17.
- 9 Cummings JL, Duchon LW. Kluver-Bucy syndrome in Picks disease: Clinical and pathological correlations. *Neurology* 1981; 31:1415-22.
- 10 Powers JM, Schaumburg HH, Gaffney Cl. Kluver-Bucy syndrome caused by adreno-leukodystrophy. *Neurology* 1980; 30:1131-2.
- 11 Guidotti TL, Charnes ME, Lamon JM. Acute intermittent porphyria and the Kluver-Bucy syndrome. *J Hopkins Med J* 1979; 145:233-5.
- 12 Janati A. Kluver-Bucy syndrome in Huntington's chorea. *J Nerv Ment Dis* 1985; 173:632-5.
- 13 Hooshmand H, Sepdbam T, Vries JK. Kluver-Bucy syndrome: Successful treatment with carbamazepine. *JAMA* 1974; 229:1782.
- 14 Longman J, Valente MI. Disturbios neuropsiquiatricos por lesões bilaterais do lobo temporal. Síndrome de Kluver e Bucy. *Arq Neuropsiquiatr* 1957; 15:40-57.
- 15 Tonsgard JH, Harwicke N, Levine SC. Kluver-Bucy syndrome in children. *Pediatr Neurol* 1987; 3:162-5.
- 16 Sawa M, Ueki Y, Arita M, Harada T. Preliminary report on the amygdalorodectomy on the psychotic patient with interpretation of oral-emotional manifestations in schizophrenics. *Folia Psychiatr Neurol Japan* 1954; 7:309-29.
- 17 Rossitch E, Oakes, WJ. Kluver-Bucy syndrome in a child with bilateral arachnoid cysts: Report of a case. *Neurosurgery* 1989; 24:110-2.
- 18 Milner B, Penfield W. The effect of hippocampal lesions on recent memory. *Trans Am Neural Assoc* 1955; 80:42-4.
- 19 Scheinker IM. Transtentorial herniation of the brain stem; a characteristic clinicopathologic syndrome; pathogenesis of hemorrhages in the brain stem. *Arch Neurol Psychiatry* 1945; 53:289-98.