

The Effect of Nebulized Glycopyrrolate on Posterior Drooling in Patients with Brain Injury

Two Cases of Different Brain Lesions

Zee-Ihn Lee, MD, PhD, Kwang Jae Yu, MD, Dae Hee Lee, MD, Seong Kyung Hong, MD, Seung Beom Woo, MD, Jong Min Kim, MD, and Donghwi Park, MD

Abstract: Posterior drooling, which can lead to substantial respiratory morbidity, including unexplained lung diseases and recurrent pneumonia, is an important issue in the rehabilitation unit. There are various treatment options for posterior drooling, including pharmacologic therapy, oral motor or behavioral therapy, biofeedback, local glandular injection of botulinum toxin, irradiation, and surgery. Among them, nebulized glycopyrrolate has the following advantages: It is noninvasive and is relatively free of central adverse effects because it does not cross the blood-brain barrier unlike other anticholinergics. Although there has been one case report regarding the effectiveness of nebulized glycopyrrolate for drooling in a motor neuron patient, there have not been any reports on its effectiveness for posterior drooling. Herein, we report two cases (an 82-year-old male bilateral hemiplegic stroke patient and a 1-year-old female cerebral palsy infant with bilaterally spastic hemiplegia of posterior drooling treated with nebulized glycopyrrolate) and identify salivary aspiration and the effect of nebulized glycopyrrolate using radionuclide salivagram. Considering its advantages and effectiveness, nebulized glycopyrrolate should be considered as one of the reliable methods to manage posterior drooling in patients with impaired cognition or swallowing difficulties, such as severe brain injury.

Key Words: Posterior Drooling, Salivagram, Glycopyrrolate, Salivary Aspiration, Dysphagia

(*Am J Phys Med Rehabil* 2017;00:00–00)

Drooling is the unintentional loss of saliva from the mouth, known as anterior drooling.¹ However, it is important to distinguish anterior drooling from posterior drooling. The latter refers to saliva that is spilled over the tongue through the faucial isthmus.¹ Posterior drooling can lead to substantial respiratory morbidity, including unexplained lung diseases and recurrent pneumonia. Hence, it is an important issue in the rehabilitation unit.^{2,3} In particular, patients with neurologic diseases who have been in a bedridden state for an extended period of time can be at greater risk for the development of chronic salivary aspiration and pulmonary complications.^{4,5} Continuous secretion of saliva and aspiration, in contrast to aspiration only during swallowing, is difficult to manage, even with modifications to food consistencies or complete cessation of oral feeding altogether.⁵

There are various treatment options for posterior drooling, including anticholinergics or patches, oral motor or behavioral therapy, biofeedback, local glandular injection of botulinum toxin, irradiation, and surgery.⁶ Recently, botulinum toxin injection was introduced as one of the treatment options for posterior drooling.^{1,5} However, it is an invasive procedure that has been associated with rare complications, such as swallowing difficulty and pain at the injection site. Although anticholinergic medication has been the primary drug of choice, its inability to restrict antimuscarinic activities has limited its use.⁷ Moreover, the applicability of oral anticholinergic agents in patients with swallowing difficulty is also a limitation. To overcome these limitations, noninvasive and parenteral anticholinergics, such as transdermal and nebulized anticholinergics, have been investigated for applicability in patients with drooling.^{8,9} Among them, nebulized glycopyrrolate (glycopyrronium bromide) has been shown to be advantageous owing to its noninvasiveness and relative freedom from central adverse effects, as there is no crossing of the blood-brain barrier, unlike other anticholinergics, such as scopolamine and atropine.^{8,10} Although there has been one previous case report regarding the effectiveness of nebulized glycopyrrolate for drooling in a motor neuron patient,⁸ there have not been any reports, to the best of our knowledge, about its effectiveness for posterior drooling via a radionuclide salivagram.

In the following two cases, glycopyrrolate was administered via a nebulizer to patients with posterior drooling. We detected salivary aspiration and evaluated the effect of nebulized glycopyrrolate using radionuclide salivagram. These cases

From the Department of Rehabilitation Medicine, Daegu Fatima Hospital, Daegu, South Korea.

All correspondence and requests for reprints should be addressed to: Donghwi Park, MD, Department of Rehabilitation Medicine, Daegu Fatima Hospital, 99 Ayang-ro, Dong-gui, Daegu 41199, South Korea.

No commercial party having a direct financial interest in the results of the research supporting this article has or will confer a benefit on the authors or on any organization with which the authors are associated.

Financial disclosure statements have been obtained, and no conflicts of interest have been reported by the authors or by any individuals in control of the content of this article.

Supplemental digital content is available for this article. Direct URL citations appear in the printed text and are provided in the HTML and PDF versions of this article on the journal's Web site (www.ajpmr.com).

Copyright © 2017 Wolters Kluwer Health, Inc. All rights reserved.

ISSN: 0894-9115

DOI: 10.1097/PHM.0000000000000669

were approved by the institutional review board at our institution, and all authors have read and approved the paper. In addition, this study conforms to all CARE guidelines and reports the required information accordingly (Supplementary Checklist, <http://links.lww.com/PHM/A365>).

CASE 1

An 82-year-old male bilateral hemiplegic patient with subarachnoid hemorrhage and subsequent several cerebral infarctions had been having recurrent saliva aspiration and recurrent pneumonia for 9 months, nasogastric tube feeding. He showed poor cooperation and had a tracheostomy tube. Moreover, he did not have any episode of esophageal peristalsis alteration, such as gastroesophageal reflux and vomiting. Radionuclide salivagram was conducted to detect salivary aspiration. A drop of saline solution (0.1 mL), containing 1.0 mCi of technetium 99m sulfur colloid (Techn; Fujifilm RI pharma Co, Japan), was placed on the tongue of the patient while he was in supine position.¹¹ Sequential images were obtained after 1 and 5 minutes, and then at 10-minute intervals thereafter for a total duration of 60 minutes. Pulmonary aspiration of saliva, determined by the presence of radiotracer activity in the trachea or both bronchi, was evaluated.³ On the initial salivagram, abnormal radionuclide uptake was observed in the trachea and bilateral bronchial tree (Fig. 1A). After diagnosis of pulmonary aspiration of saliva, nebulized glycopyrrolate (0.2 mg/mL ampoules; Tabinul, Hana Pharm, Seoul, South Korea) was started to manage saliva aspiration. Nebulized glycopyrrolate was started with a dose of 0.2 mg once daily. Two days after the application of nebulized glycopyrrolate, the dose of glycopyrrolate was increased to 0.2 mg twice per day. Four

days after the application of nebulized glycopyrrolate, the dose of glycopyrrolate was increased to 0.4 mg twice per day. After the treatment with nebulized glycopyrrolate, the numbers of suction (from 10 to 12/day to 2 to 3/day) was significantly decreased. Moreover, a visual analog scale (VAS) of caregiver for the amount of drooling was also decreased from 9 to 1.5 (Table 1). Two weeks after the application of nebulized glycopyrrolate, the frequency and severity, as indicated by the drooling scoring system, improved from profuse, constant drooling to mild, occasional drooling.¹² Moreover, he experienced no urinary problems or any other anticholinergic adverse effects. A follow-up salivagram, which was performed 3 weeks after the treatment, showed no extraesophageal uptake of radiotracer for saliva aspiration. The increased uptake of radiotracer on both bronchi had disappeared in the follow-up salivagram compared with the initial study (Fig. 1B). In addition, VAS and the number of suction per day were maintained the same as 2 weeks after treatment.

CASE 2

A 1-year-old female cerebral palsy infant with bilaterally spastic hemiplegia had salivary aspiration and recurrent pneumonia. She was born at 37 weeks and 3 days, and her body weight at birth was 1950 g. Magnetic resonance imaging (MRI) of the brain at birth showed hypoxic ischemic encephalopathy due to perinatal asphyxia. She had difficulty turning over by herself and had percutaneous endoscopic jejunostomy feeding and tracheostomy, and her Gross Motor Function Classification System (GMFCS) score was 5. She had drooling and frequent tracheal suction, which occurred more than 15 times on average during the day and 10 times on




FIGURE 1. Sequential images of a radionuclide salivagram throughout a period of 1 hour. A, Initial radionuclide salivagram of case 1. Presence of radioactivity in the esophageal area, as well as the bilateral bronchi and trachea, demonstrating positivity for posterior drooling on the salivagram (arrow). B, Follow-up radionuclide salivagram of case 1. There was no extraesophageal uptake of radiotracer on the follow-up salivagram after the application of nebulized glycopyrrolate.

TABLE 1. Changes in VAS and the number of suction between before-treatment and 2 weeks follow-up after treatment in case 1 and 2 patients

	Before Treatment		After Treatment	
	VAS	No. Suctions	VAS	No. Suctions
Patient 1	9	10–12/day	1.5	2–3/day
Patient 2	10	25/day	2	1–2/day

average during the night, which severely interfered with her sleep.

In the initial radionuclide salivagram (Fig. 2) using the aforementioned method, we observed radioactivity in the esophageal area as well as the trachea and bilateral bronchial tree, which indicated aspiration of saliva. After the diagnosis of pulmonary aspiration of saliva, she was given a nebulized glycopyrrolate (Tabinul, 0.2 mg/1-mL ampoules) treatment with a dose of 0.1 mg once per night. At the start of the treatment, her body weight was 10.0 kg. After the treatment, the frequency of suction had decreased remarkably during her sleep, at most, only once or twice per night. Two weeks after the application of nebulized glycopyrrolate, the frequency and severity, as indicated by the drooling scoring system, improved from profuse, constant drooling to mild, occasional drooling.¹² The VAS of caregiver for drooling also decreased from 10 to 2 (Table 1). She also experienced no urinary problems or any other anticholinergic adverse effects. However, a follow-up salivagram was not performed because her parents did not consent to any additional radionuclide salivagram.

DISCUSSION

Radionuclide salivagram has been used to detect passive aspiration of saliva, especially in patients with oral feeding

difficulties or poor cooperation.¹³ After sublingual instillation of a small amount of radiolabeled colloid, serial images are evaluated for the presence of radiotracer uptake in the tracheobronchial tree, which suggests aspiration.³ For these reasons, salivagram can be used in patients with recurrent aspiration pneumonia, despite parenteral feeding.

The safety of inhaled glycopyrrolate has been supported extensively in previous clinical studies.^{8,14} Glycopyrrolate is a long-acting muscarinic antagonist with a slow receptor dissociation time; it is kinetically selective for M1 and M3 receptors.¹⁵ The effect of glycopyrrolate is exerted by blocking the anticholinergic muscarinic receptors on the salivary glands.¹⁰ Unlike other anticholinergic drugs used for sialorrhea, such as atropine, scopolamine, biperiden, and amitriptyline, the quaternary structure of glycopyrrolate prevents it from passing through the blood-brain barrier.^{8,10} This characteristic of glycopyrrolate may have advantages in minimizing the central adverse effects, such as preservation of cognitive function.¹⁶ In addition, the slow dissociation property of glycopyrrolate contributes to the long-lasting effect on the salivary glands.^{17,18} Moreover, its ability to rapidly be absorbed also contributes to its efficacy on treating posterior drooling. In a previous study, the mean delivery time for nebulized glycopyrrolate was shown to be less than 2 minutes, and nebulized glycopyrrolate was rapidly absorbed with the peak plasma concentration of 15 to 30 minutes.¹⁷ Nebulized glycopyrrolate may have been rapidly effective because (1) the nebulizer allowed for a rapid absorption of the drug in a given area with rich blood supply and lymphatic vessels, like the buccal area and (2) glycopyrrolate had a direct effect on the salivary glands. In a previous report about nebulized glycopyrrolate in patients with anterior drooling, a dose of 0.4 mg twice daily was applied. Although there was no recommended maximum dose for nebulized glycopyrrolate in children, most clinical studies and case series published to date have used intravenous or intramuscular glycopyrrolate in

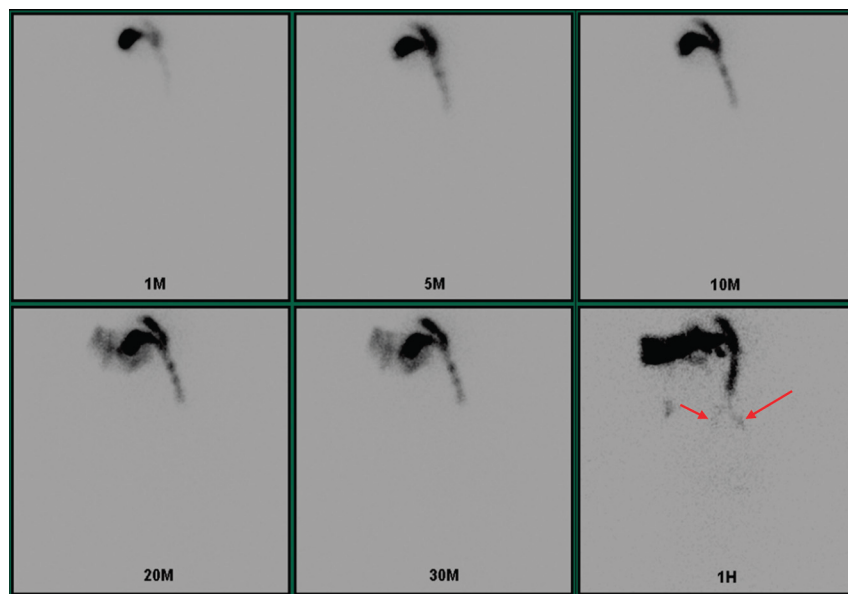


FIGURE 2. Sequential images of a radionuclide salivagram throughout a period of 1 hour. Initial radionuclide salivagram of case 2. Presence of radioactivity in the esophageal area, as well as the bilateral bronchi and trachea, demonstrating positivity for posterior drooling on the salivagram (arrows).

a range of 4.0 to 6.0 µg/kg, and some authors have even used a dose as high as 10.0 µg/kg in children.¹⁹ In our case, 100 µg of nebulized glycopyrrolate was used in a child weighing 10.0 kg. Considering that 8.0 µg/kg of intramuscular glycopyrrolate raises the peak plasma concentration to as high as 3.47 ± 1.48 µg/mL in children²⁰ and 100 µg of nebulized glycopyrrolate raises the peak plasma concentration to as high as 0.162 ± 0.082 µg/mL,¹⁷ we determined that 100 µg of nebulized glycopyrrolate would be safe for our 1-year-old infant weighing 10.0 kg. No adverse effects were observed in both of our cases during the nebulized glycopyrrolate treatment. Although a previous study reported that the half-life of 0.1 mg (1/2 ampoule), 0.2 mg (1 ampoule), and 0.4 mg (2 ampoules) of nebulized glycopyrrolate was 3.3 ± 1.2 hours, 3.4 ± 1.3 hours, and 4.8 ± 3.0 hours,¹⁷ respectively, further studies may be necessary to estimate the long-term effects of nebulized glycopyrrolate on posterior drooling.

In both of our cases, nebulized glycopyrrolate was well tolerated, and the caregivers noticed an improvement in symptoms within 30 minutes of application. Moreover, the effects lasted almost an entire day. Although a follow-up radionuclide salivagram was not performed in the second case, the effectiveness of nebulized glycopyrrolate on posterior drooling in patients with severe brain injury was observed, as both cases resulted in the improvement of posterior drooling symptoms. Considering its advantages and effectiveness, nebulized glycopyrrolate should be considered as one of the reliable methods for the management of posterior drooling in patients with impaired cognition or swallowing difficulties, such as severe brain injury.

REFERENCES

- Jongerius PH, van Hulst K, van den Hoogen FJ, et al: The treatment of posterior drooling by botulinum toxin in a child with cerebral palsy. *J Pediatr Gastroenterol Nutr* 2005;41:351-3
- Boesch RP, Daines C, Willging JP, et al: Advances in the diagnosis and management of chronic pulmonary aspiration in children. *Eur Respir J* 2006;28:847-61
- Park HW, Lee WY, Park GY, et al: Salivagram after gland injection of botulinum neurotoxin A in patients with cerebral infarction and cerebral palsy. *PMR* 2012;4:312-6
- Nobrega AC, Rodrigues B, Melo A: Is silent aspiration a risk factor for respiratory infection in Parkinson's disease patients? *Parkinsonism Relat Disord* 2008;14:646-8
- Reddihough D, Erasmus CE, Johnson H, et al: Botulinum toxin assessment, intervention and aftercare for paediatric and adult drooling: international consensus statement. *Eur J Neurol* 2010;17(suppl):109-21
- Meningaud JP, Pitak-Arnop P, Chikhani L, et al: Drooling of saliva: a review of the etiology and management options. *Oral Surg Oral Med Oral Pathol Oral Radiol Endod* 2006;101:48-57
- Eiland LS: Glycopyrrolate for chronic drooling in children. *Clin Ther* 2012;34:735-42
- Strutt R, Fardell B, Chye R: Nebulized glycopyrrolate for drooling in a motor neuron patient. *J Pain Symptom Manage* 2002;23:2-3
- Mato Montero A, Limeres Posse J, Tomas Carmona I, et al: Control of drooling using transdermal scopolamine skin patches. A case report. *Med Oral Patol Oral Cir Bucal* 2008;13:E27-30
- Arbouw ME, Movig KL, Koopmann M, et al: Glycopyrrolate for sialorrhea in Parkinson disease: a randomized, double-blind, crossover trial. *Neurology* 2010;74:1203-7
- Akbunar AT, Kiristioğlu I, Alper E, et al: Diagnosis of orotracheal aspiration using radionuclide salivagram. *Ann Nucl Med* 2003;17:415-6
- Thomas-Stonell N, Greenberg J: Three treatment approaches and clinical factors in the reduction of drooling. *Dysphagia* 1988;3:73-8
- Heyman S, Respondek M: Detection of pulmonary aspiration in children by radionuclide "salivagram". *J Nucl Med* 1989;30:697-9
- van Noord JA, Buhl R, Laforce C, et al: QVA149 demonstrates superior bronchodilation compared with indacaterol or placebo in patients with chronic obstructive pulmonary disease. *Thorax* 2010;65:1086-91
- Haddad EB, Patel H, Keeling JE, et al: Pharmacological characterization of the muscarinic receptor antagonist, glycopyrrolate, in human and guinea-pig airways. *Br J Pharmacol* 1999;127:413-20
- Swartz CM, Saheba NC: Comparison of atropine with glycopyrrolate for use in ECT. *Convuls Ther* 1989;5:56-60
- Leaker BR, Barnes PJ, Jones CR, et al: Efficacy and safety of nebulized glycopyrrolate for administration using a high efficiency nebulizer in patients with chronic obstructive pulmonary disease. *Br J Clin Pharmacol* 2015;79:492-500
- Hansel TT, Neighbour H, Erin EM, et al: Glycopyrrolate causes prolonged bronchoprotection and bronchodilatation in patients with asthma. *Chest* 2005;128:1974-9
- Desalu I, Kushimo OT, Bode CO: A comparative study of the haemodynamic effects of atropine and glycopyrrolate at induction of anaesthesia in children. *West Afr J Med* 2005;24:115-9
- Ali-Melkkila T, Kaila T, Kanto J: Glycopyrrolate: pharmacokinetics and some pharmacodynamic findings. *Acta Anaesthesiol Scand* 1989;33:513-7