

Delayed-Onset Central Pain due to Degeneration of Ischemic Transcallosal Fibers After Corpus Callosum Hemorrhage

Sung Ho Jang, MD, Chul Hoon Chang, MD, Young Jin Jung, MD, and Han Do Lee, MS

Aims: A patient developed delayed-onset central pain due to degeneration of the spinothalamic tract resulting from degeneration of the ischemic transcallosal fibers, in the aftermath of a corpus callosum (CC) hemorrhage. The detection and diagnosis of these lesions using diffusion tensor tractography are described.

Methods: A 59-yr-old man underwent conservative management for hemorrhages in the CC and lateral ventricle that resulted from hitting his head against a wall while falling. He began to feel pain in his right upper and lower extremities approximately 1½ yrs after the initial injury. The pain was characterized as constant tingling, numb, and cool sensation without allodynia or hyperalgesia (visual analogue scale score, 5).

Results: Disruption of transcallosal fibers in the genu and isthmus of the CC was observed on diffusion tensor tractography 1 mo after the initial injury. By 3 yrs, the diffusion tensor tractography showed that transcallosal fibers in the isthmus (67.8%–77.9%) of the CC had disappeared, and the left spinothalamic tract had become thinner.

Conclusion: The results suggest that central pain can occur without direct injury of the spinothalamic tract and point up the need for evaluation of the spinothalamic tract and transcallosal fibers in patients with a CC lesion who complain of central pain.

Key Words: Spinothalamic Tract, Diffusion Tensor Imaging, Transcallosal Fibers, Corpus Callosum

(*Am J Phys Med Rehabil* 2017;00:00–00)

Central pain is caused by a lesion or dysfunction arising in the central nervous system and presents with the characteristics of neuropathic pain.¹ The diagnosis of central pain is important because the management strategy differs from other pains. Introduction of diffusion tensor tractography (DTT), derived from diffusion tensor imaging (DTI), enables three-dimensional reconstruction of the spinothalamic tract (STT).^{2,3} Injury of the STT is a pathogenetic mechanism of central pain after brain injury.^{4–6} The corpus callosum (CC) is the largest white matter fiber bundle connecting the two hemispheres of the brain by transcallosal fibers (TCFs).⁷ Injury to the TCFs can result in disconnection syndromes depending on the CC location of the lesion.^{8–11} Typical clinical features of a postcentral gyrus disconnection include tactile dysnomia and hemispatial neglect.¹¹ However, to the best of the authors' knowledge, there is no published research on central pain after pathology of the TCFs connecting the postcentral gyrus, the main origin of the STT.

This report describes a patient who developed delayed-onset central pain owing to degeneration of the STT resulting

from degeneration of the ischemic TCFs, in the aftermath of a CC hemorrhage. The detection and diagnosis of these lesions using DTT are described.

CASE REPORT

Ethics Statement

This subject provided signed, informed consent and the authors' institutional review board approved the study protocol (approval number: YUH-15-0425-D7).

Patient Description

A 59-yr-old, right-handed man underwent conservative management (control of intracranial pressure) for hemorrhages in the CC and lateral ventricle that resulted from hitting his head against a wall while falling at the department of neurosurgery of a university hospital (Fig. 1A). The patient had a history of stent insertion for coronary artery stenosis 2 yrs before. He began comprehensive rehabilitative management 2 wks after the fall at the rehabilitation department of the same university hospital. At the beginning of rehabilitation, he showed mild cognitive impairment (Mini-Mental State Examination, 25) and motor weakness of all four extremities (Manual Muscle Test: 3/3) (Table 1). However, his somatosensory function was normal, as determined by the subscales for tactile sensation (20 [full score: 20]) and kinesthetic sensation (24 [full score: 24]) of the Nottingham Sensory Assessment.¹² After 2 mos of rehabilitation, he recovered as follows: Mini-Mental State Examination, 30; Manual Muscle Test, 4/4, and he could walk independently. His motor weakness recovered to a sub-normal state (Manual Muscle Test, 4⁺/4⁺) at 6 mos after onset and was maintained at that state.

From the Departments of Physical Medicine and Rehabilitation (SHJ, HDL) and Neurosurgery (CHC, YJJ), College of Medicine Yeungnam University, Taegu, Republic Korea.

All correspondence and requests for reprints should be addressed to: Han Do Lee, MS, Department of Physical Medicine and Rehabilitation, College of Medicine, Yeungnam University 317-1, Daemyungdong, Namku, Taegu 705-717, Republic of Korea.

This work was supported by the National Research Foundation (NRF) of Korea Grant funded by the Korean Government (MSIP) (2015R1A2A2A01004073). Financial disclosure statements have been obtained, and no conflicts of interest have been reported by the authors or by any individuals in control of the content of this article.

Supplemental digital content is available for this article. Direct URL citations appear in the printed text and are provided in the HTML and PDF versions of this article on the journal's Web site (www.ajpmr.com).

Copyright © 2017 Wolters Kluwer Health, Inc. All rights reserved.
ISSN: 0894-9115

DOI: 10.1097/PHM.0000000000000693

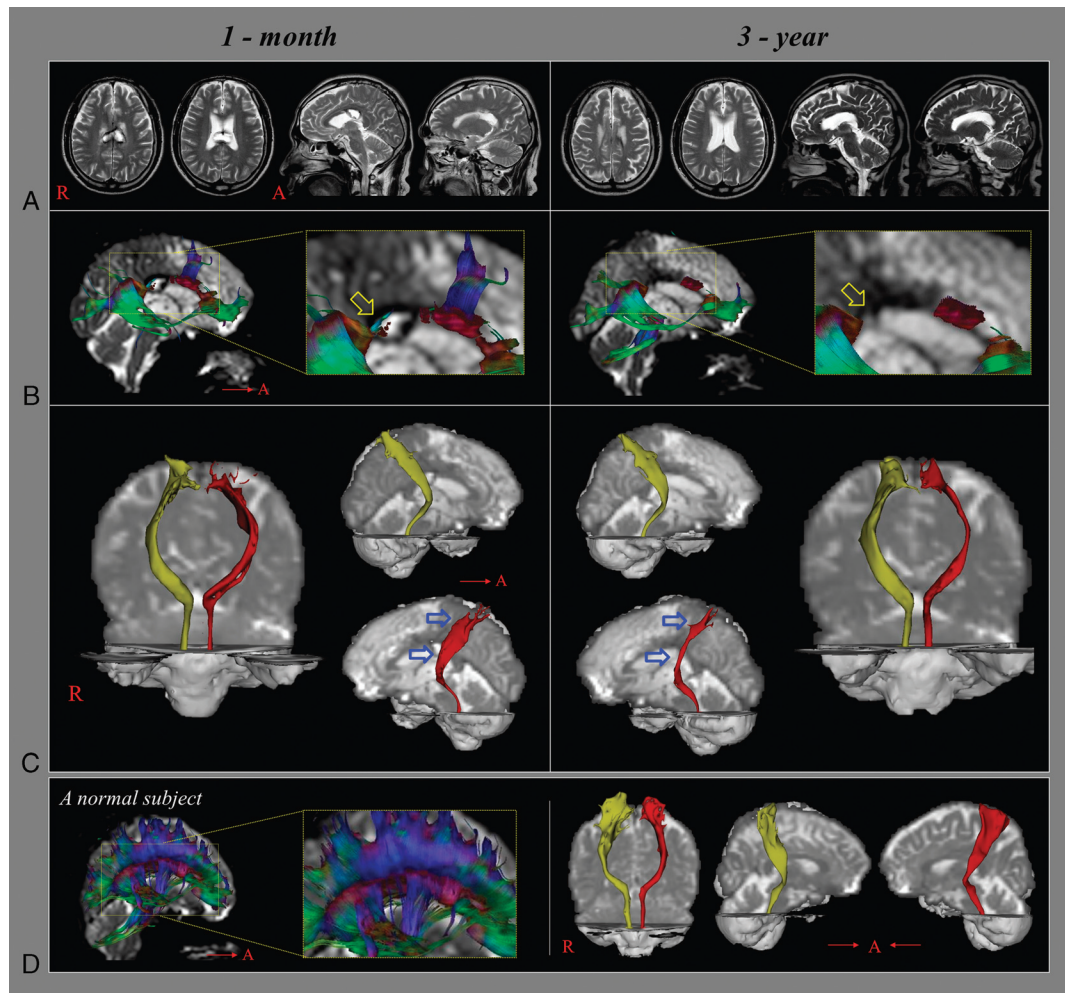


FIGURE 1. A, T2-weighted brain MR images at 1 mo and 3 yrs after onset show hematoma and leukomalactic lesion in the body and isthmus of the CC. B, C, Results of DTI for the spinothalamic tract (STT). Disruption of TCFs in the genu and isthmus of the CC was observed on 1-mo DTI. In contrast, on 3-yr DTI, TCFs in the isthmus (67.8%–77.9%) of the CC had disappeared, and the left STT (arrows) had become thinner. D, DTI for the STT in a normal subject (58-yr-old man).

He began to feel pain in his right upper and lower extremities at approximately 1½ yrs after the initial injury. The pain was characterized as constant tingling, numb, and cool sensation without allodynia or hyperalgesia (visual analogue scale score, 5).¹³ However, his cognition, motor, and somatosensory function did not change. He was prescribed gabapentin (900 mg/day) at that point, and his pain was controlled to a tolerable level. This prescription continued for 3 yrs when a second DTI was scanned.

Diffusion Tensor Imaging

DTI data were acquired two times (1 mo after initial injury [hematoma volume, 1.49 mV] and 3 yrs later [hematoma volume, 0 mV] after onset) using a six-channel head coil on a 1.5 T Philips Gyroscan Intera (Philips, Best, the Netherlands) with single-shot echo-planar imaging. For each of the 32 non-collinear diffusion sensitizing gradients, 67 contiguous slices were acquired parallel to the anterior commissure-posterior commissure line. Imaging parameters were as follows: acquisition matrix, 96 × 96; reconstructed to matrix, 192 × 192; field of view, 240 × 240 mm²; repetition time, 10,398 msec; echo

time, 72 msec; parallel imaging reduction factor (SENSE factor), 2; echo-planar imaging factor, 59; b = 1000 s/mm²; number of excitations, 1; and a slice thickness of 2.5 mm.

TABLE 1. Change in clinical characteristics of the patient

	2 wks	2 mos	6 mos	1.5 yrs
MMSE	25	30	30	30
MMT	3/3	4/4	4+/4+	4+/4+
NSA				
Touch	20/20	20/20	20/20	20/20
Proprioceptive	24/24	24/24	24/24	24/24

MMSE indicates Mini-Mental State Examination; MMT, Manual Muscle Test (0: no contraction; 1: palpable contraction, but no visible movement; 2: movement without gravity; 3: movement against gravity; 4: movement against a resistance lower than the resistance overcome by the healthy side; 5: movement against a resistance equal to the maximum resistance overcome by the healthy side); NSA, Nottingham Sensory Assessment.

Fiber Tracking

1. For reconstruction of the CC

Fiber tracking was performed using the fiber assignment continuous tracking algorithm implemented within the DTI task card software (Philips Extended MR WorkSpace 2.6.3). Each of the DTI replications was intra-registered to the baseline “b0” images to correct for residual eddy-current image distortions and head motion effect, using a diffusion registration package (Philips Medical Systems). A region of interest was placed on the entire CC of the sagittal image and a color map was used for the reconstruction of CC fibers. Fiber tracking was performed using a fractional anisotropy of less than 0.3 and a trajectory angle threshold of greater than 45 degrees.

The locations of disappeared portions of TCFs were measured on the midsagittal slice of the CC in the anteroposterior direction. The relative distance of the disappeared portion of TCFs was measured, and locations were calculated in pixel units using the following equation⁷:

$$\text{Antero-posterior distance (\%)} = \frac{\text{Distance between the most anterior point of the CC and disappeared portion (most anterior and posterior point) of TCFs}}{\text{Distance of total CC}} \times 100$$

2. For reconstruction of the STT

Analysis of diffusion-weighted imaging data was performed using the Oxford Centre for Functional Magnetic Resonance Imaging of the Brain Software Library (FSL; www.fmrib.ox.ac.uk/fsl). Affine multiscale two-dimensional registration was used for correction of head motion effect and image distortion due to eddy current. Fiber tracking was performed using a probabilistic tractography method based on a multifiber model and applied using tractography routines implemented in Functional Magnetic Resonance Imaging of the Brain Diffusion (5000 streamline samples, 0.5 mm step lengths, curvature thresholds = 0.2). The STTs were placed by selection of fibers passing through regions of interest. A seed region of interest was placed on the posterolateral medulla on an axial slice and a target region of interest was placed on the primary somatosensory cortex on an axial slice. The threshold of two streamlines was applied for the results of fiber tracking.

Disruption of TCFs in the genu and isthmus of the CC was observed on the DTT 1 mo after the initial injury. In contrast, 3 yrs later, the DTT revealed that TCFs in the isthmus (67.8%–77.9%) of the CC had disappeared, and the left STT had become thinner (Fig. 1B).

DISCUSSION

TCFs and STTs were examined using DTT in a patient with CC hemorrhage on two occasions 3 yrs apart. The DTT taken 3 yrs after the initial injury revealed that the ischemic TCFs (67.8%–77.9%) had disappeared and the left STT had become thinner compared with the DTT taken at 1 mo after injury. Because the location of the disappeared TCFs corresponded to the TCFs (73.48 ± 6.43) linking the post-central gyrus,⁷ the authors believe that the thinning of the left STT was ascribed to secondary degeneration after the degeneration of the TCFs in the isthmus. Furthermore, development of

central pain, which started at 1.5 yrs after onset, seemed to be associated with degeneration of the left STT. The authors think that two factors might contribute to the phenomenon of lack of change of somatosensory function despite degeneration of the STT. First, although the left STT degenerated, it was mild and the integrity of the STT was well preserved. This suggests that subclinical damage to the STT might be sufficient to induce central pain. Recent studies also have reported that the importance of integrity of the STT and the somatosensory function was not abnormal although the STT revealed degeneration or injury in patients with brain injury who showed preserved integrity of the STT.^{5,14,15} Second, the degeneration was apparently progressive for a prolonged period. This could partially explain the lack of somatosensory loss of this patient. The authors believe that this degeneration might occur through a chemical injury mechanism of hematoma in the CC: a blood clot itself can cause extensive damage to neural tissue by release of potentially damaging substances, such as free iron, which can generate free radicals or inflammatory cytokines.^{16–18} However, there is also a possibility that ischemic TCFs could be injured mechanically: a direct mass effect by hematoma can reduce cerebral perfusion pressure and cause secondary ischemic injury to ischemic TCFs.^{16,17} This study's results seem consistent with a recent report of a patient who showed delayed degeneration of the corticospinal tract by peri-lesional degeneration starting 4 yrs after onset of intracerebral hemorrhage.¹⁹

However, this study is limited, as it is a single case study. In addition, limitations of DTI should be considered: the fiber tracking technique is operator dependent and regions of fiber complexity and crossing can prevent full reflection of the underlying fiber architecture by DTI.²⁰

In conclusion, a patient with CC hemorrhage is reported who developed delayed-onset central pain due to subsequent degeneration of the STT after degeneration of the ischemic TCFs. This study's results suggest that central pain can occur without direct injury of the STT, and emphasize the need of evaluation of the STT and TCFs in patients with CC lesion when a patient complains of central pain. To the best of the authors' knowledge, this is the first study to demonstrate central pain resulting from secondary degeneration of the STT after ischemic TCFs.

SUPPLEMENTARY CHECKLIST

CARE Checklist: <http://links.lww.com/PHM/A381>

REFERENCES

- Nampiaparampil DE: Prevalence of chronic pain after traumatic brain injury: a systematic review. *JAMA* 2008;300:711–9
- Haines DE, Ard MD: *Fundamental Neuroscience*. ed 2 New York, NY: Churchill Livingstone; 2002
- Hong JH, Kwong HG, Jang SH: Probabilistic somatotopy of the spinothalamic pathway at the ventroposterolateral nucleus of the thalamus in the human brain. *AJNR Am J Neuroradiol* 2011;32:1358–62
- Seo JP, Jang SH: Traumatic thalamic injury demonstrated by diffusion tensor tractography of the spinothalamic pathway. *Brain Inj* 2013;27:749–53
- Seo JP, Jang SH: Injury of the spinothalamic tract in a patient with mild traumatic brain injury: diffusion tensor tractography study. *J Rehabil Med* 2014;46:374–7
- Kim JH, Ahn SH, Cho YW, et al: The relation between injury of the spinothalamic tract and central pain in chronic patients with mild traumatic brain injury. *J Head Trauma Rehabil* 2015;30:E40–6
- Seo JP, Jang SH: Anatomical location of transcallosal sensorimotor fibers in the human brain: diffusion tensor tractography study. *Transl Neurosci* 2013;4:363–7

8. Watson RT, Heilman KM: Callosal apraxia. *Brain* 1983;106(Pt 2):391–403
9. Bogousslavsky J, Caplan LR: *Stroke Syndromes*. ed 2. Cambridge New York: Cambridge University Press; 2001
10. Bourekas EC, Varakis K, Bruns D, et al: Lesions of the corpus callosum: MR imaging and differential considerations in adults and children. *AJR Am J Roentgenol* 2002;179:251–7
11. Jea A, Vachhrajani S, Widjaja E, et al: Corpus callosotomy in children and the disconnection syndromes: a review. *Childs Nerv Syst* 2008;24:685–92
12. Lincoln NB, Jackson JM, Adams SA: Reliability and revision of the Nottingham Sensory Assessment for Stroke Patients. *Physiotherapy* 1998;84:358–65
13. Miller MD, Ferris DG: Measurement of subjective phenomena in primary care research: the visual analogue scale. *Fam Pract Res J* 1993;13:15–24
14. Jang SH, Kwon HG: Degeneration of an injured spinothalamic tract in a patient with mild traumatic brain injury. *Brain Inj* 2016;30:1026–8
15. Jang SH, Son SM, Lee DY, et al: Relationship between somatosensory function and the spinothalamic pathway in chronic stroke patients. *Somatosens Mot Res* 2013;30:197–200
16. Chua CO, Chahboune H, Braun A, et al: Consequences of intraventricular hemorrhage in a rabbit pup model. *Stroke* 2009;40:3369–77
17. Yeo SS, Choi BY, Chang CH, et al: Periventricular white matter injury by primary intraventricular hemorrhage: a diffusion tensor imaging study. *Eur Neurol* 2011;66:235–41
18. Yeo SS, Choi BY, Chang CH, et al: Evidence of corticospinal tract injury at midbrain in patients with subarachnoid hemorrhage. *Stroke* 2012;43:2239–41
19. Jang SH, Seo JP: Delayed leg weakness due to peri-lesional neural degeneration in a patient with intracerebral haemorrhage: case report. *Acta Neurol Belg* 2016;116:91–3
20. Yamada K, Sakai K, Akazawa K, et al: MR tractography: a review of its clinical applications. *Magn Reson Med Sci* 2009;8:165–74