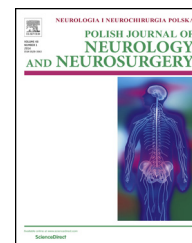


Available online at [www.sciencedirect.com](http://www.sciencedirect.com)

ScienceDirect

journal homepage: <http://www.elsevier.com/locate/pjnns>

## Case report

# Neuropsychological characteristics of encephalopathy in Susac's Syndrome – Case report



Magdalena Roessler-Górecka<sup>\*</sup>, Tadeusz Mendel,  
Justyna Wiśniowska, Joanna Seniów

2nd Department of Neurology, Institute of Psychiatry and Neurology, Warsaw, Poland

## ARTICLE INFO

## Article history:

Received 5 September 2016

Accepted 4 January 2017

Available online 10 January 2017

## Keywords:

Susac's Syndrome

Vasculopathy

Encephalopathy

Cognitive-behavioral dysfunction

Magnetic resonance imaging

## ABSTRACT

Susac's Syndrome (SS) is a rare, autoimmune angiopathy characterized by hearing loss, retinal artery occlusions and encephalopathy, which is usually expressed in multifocal neurological signs and symptoms, confusion state and cognitive impairment. There have been few descriptions of neuropsychological assessment of SS.

We present a case study of 29-year-old woman who developed full SS. During the post-acute stage of disease, she was admitted to neurorehabilitation ward to improve her cognitive-behavioral and motor functioning. The initial assessment revealed attention, memory and executive dysfunctions, as well as behavioral changes including impulsivity, affective dysregulation and reduced self-awareness of disease deficits.

After five weeks recovery process supported by rehabilitation program, improvement was observed, although some cognitive-behavioral deficits were still present in the follow-up assessment.

© 2017 Polish Neurological Society. Published by Elsevier Sp. z o.o. All rights reserved.

## 1. Introduction

Susac's Syndrome (SS) is an autoimmune disease first described in 1979 by an American neurologist John Susac. It is a rare underdiagnosed endotheliopathy. Clinically, the full syndrome includes a triad of symptoms: encephalopathy, branch retinal artery occlusion (BRAOs) and hearing loss [1]. Typical findings in magnetic resonance imaging (MRI), are lesions localized in the central portion of the corpus callosum and in another sites of white and deep gray matter, as well as leptomeninges enhancement [1,2]. All components of the

clinical triad do not have to appear at the same time and it may take years for all of them to evolve [2]. SS occurs mainly in female population, especially between 20 and 40 years old. It can be diagnosed on the base of clinical triad listed above, confirmed by cerebrospinal fluid analysis, MRI and PET characteristics, audiometry and retinal fluorescein angiography. Brain pathology demonstrates microinfarcts with loss of neurons, axons, and myelin in both white and deep gray matter [3]. The presence of anti-endothelial cell antibodies (AECAs) may have a pathogenic role in the disease [4]. The clinical course of SS can be fluctuating, but usually self-limited and monophasic. However, aggressive and sustained immu-

<sup>\*</sup> Corresponding author at: 2nd Department of Neurology, Institute of Psychiatry and Neurology, Sobieskiego 9, 02-957 Warsaw, Poland. Tel.: +48 22 458 28 22; fax: +48 22 842 40 23.

E-mail addresses: [roessler@ipin.edu.pl](mailto:roessler@ipin.edu.pl) (M. Roessler-Górecka), [mendel@ipin.edu.pl](mailto:mendel@ipin.edu.pl) (T. Mendel), [justyna.wisniowska@psych.uw.edu.pl](mailto:justyna.wisniowska@psych.uw.edu.pl) (J. Wiśniowska), [seniowj@ipin.edu.pl](mailto:seniowj@ipin.edu.pl) (J. Seniów).  
<http://dx.doi.org/10.1016/j.pjnns.2017.01.001>

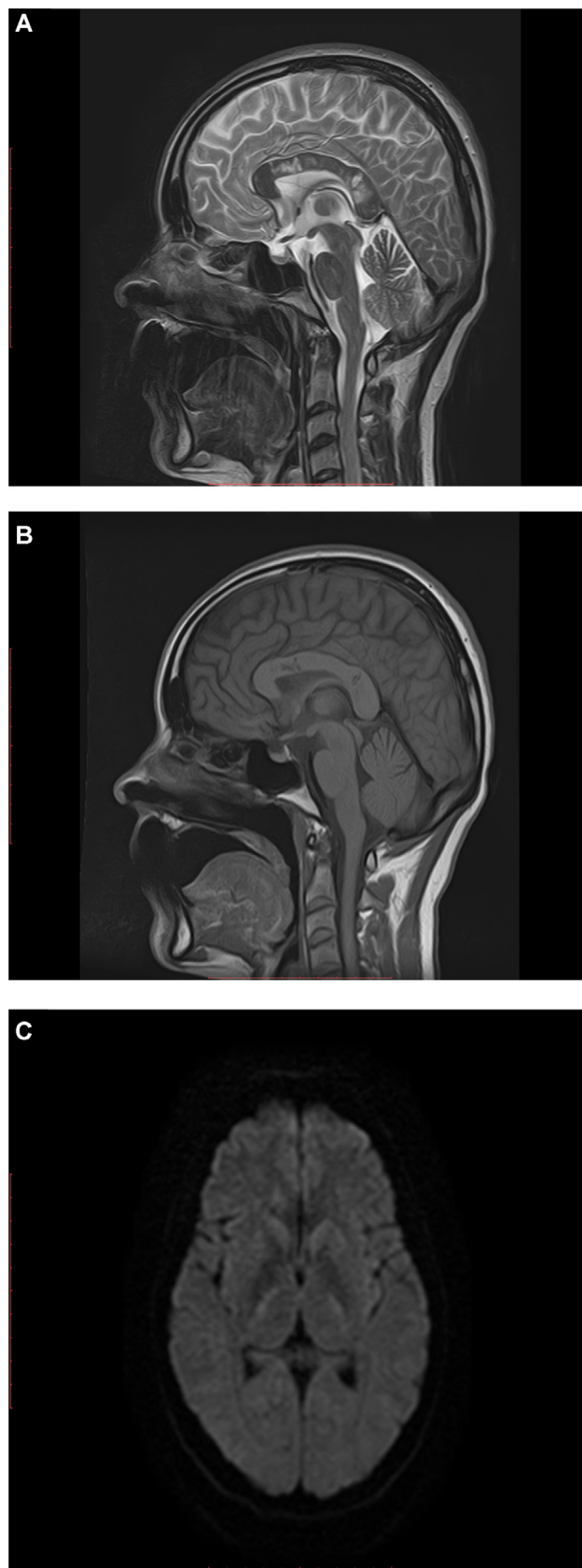0028-3843/© 2017 Polish Neurological Society. Published by Elsevier Sp. z o.o. All rights reserved.

nosuppressive treatment is needed to minimize potential irreversible neurological symptoms, hearing and vision loss. Symptoms usually last between six months to five years, but can reappear after many years, therefore SS requires lifelong monitoring [5,6]. Encephalopathy in SS results from an acute or subacute multifocal brain damage and may be subclinical or dominating in the clinical picture. Its severity does not correlate with the severity of initial neurological symptoms, and tends to be mild in the majority [7]. It occurs in 60–70% of SS patients and can manifest itself as major deficits in various cognitive domains, at the beginning of the disease co-occurring with confusion and/or personality changes, bizarre behavior, mood disturbances, and even psychotic symptoms; features of abulia can also be present and may progress to a stage where verbal and nonverbal communication is no longer possible [8]. However, until today, only five articles have described in detail neuropsychological dysfunctions in SS [9]. Cognitive impairments and their severity probably vary in individual patients: some studies have described mainly psycho-motor slowness, while others indicated more specific symptoms in domain of memory, attention, and executive functioning. Recently, comprehensive neuropsychological assessment was provided by Le Monda et al. [9]. In this case report a patient examined two years after the SS's onset, presented some cognitive inefficiencies, including visuo-constructive disability, difficulty of encoding of a wordlist and limited set-shifting. There was, however, no evidence of significant memory disturbance.

We present a case study of 29-year-old woman who developed full SS and underwent a detailed neuropsychological assessment and rehabilitation, so it can contribute to the existing literature on this rare syndrome. In the presented case, the cognitive-behavioral disturbances only partly resemble these described by Le Monda et al. [9], which also suggests the possible individual differences in the neuropsychological profile of encephalopathy in SS.

## 2. Case report

A 29 year old, right-handed woman began to suffer from migraine-like headaches in June 2015. According to the family interview, after a few weeks a progressive cognitive decline, behavioral disturbances (personality changes, apathy) as well as subacute hearing loss, tinnitus, dizziness, vertigo, visual blurring, fatigue, dysarthria, unsteady gait, ataxia, leg weakness and falls appeared. A few weeks later, double vision, further hearing loss and dysphagia occurred. The patient was hospitalized in a neurology department. Neurological examination revealed preserved consciousness, full auto- and alloorientation, central nerve VII right paresis, slight hearing loss bilaterally, slight spastic paraparesis of low extremities (more pronounced on the right side – 4 points in Medical Research Council scale for muscle strength (MRC scale), Babinski sign on the right side, gait instability and visual acuteness twenty twenty (correct). Two months since the first disease symptoms, final diagnosis of encephalopathic form of SS was established. For the diagnosis of the SS a significant examination was – among others – MRI, which showed typical findings. Sagittal T2 FLAIR revealed a multiple typical



**Fig. 1** – MRI revealed the presence of *snowball* lesions in the corpus callosum (A) - FLAIR, *punched out holes* in the corpus callosum (B) - T1, *strings of pearls* in posterior part of the capsula interna (C) - DWI.

“snowballs” – shaped lesions in the central portion of the corpus callosum; sagittal T1 – a callosal “holes”; Axial DWI – “string of pearls” – like lesions in the posterior limb of the internal capsule (Fig. 1). Audiometry demonstrated bilateral sensorineural hearing loss, more pronounced on the right side. Retinal fluorescein angiography revealed branch retinal artery occlusion, vessels wall hyperfluorescence and “leakage” of dye. The patient was treated seven daily 1 g IV pulses of methylprednisolone, followed immediately by oral prednisone 60 mg daily. Heparin in therapeutic doses was also administered for one month. After four weeks hospitalization in the neurology department, the patient was admitted to a rehabilitation ward for attempts to improve her cognitive-behavioral and motor functioning. During a five-week recovery process supported by rehabilitation program, including physiotherapeutic and neuropsychological therapies, the patient's clinical state gradually improved, spastic paraparesis withdrew and gait returned to normal state. The patient was discharged on a daily dose of 40 mg of prednisone and 75 mg of salicylic acid.

### 2.1. Neuropsychological assessment

Neuropsychological assessment was conducted on admission to neurorehabilitation ward and repeated just after completion of the therapeutic program. From the family interview it was known that the patient had no significant difficulties with intellectual/cognitive functioning before the current disease. In childhood her psychomotor development was proper. She has graduated from a secondary school (economics), with good grades. For the past eight years she was living in Great Britain, successfully working as a manager of guesthouse employees. She came back to Poland because of health problems. The patient was married and had no children. During the clinical interview, she complained about some minor attention and memory difficulties and denied any significant mood or behavioral changes. She cooperated well during the psychological assessment. According to brief cognitive screening test (Addenbrooke's Cognitive Examination-III – ACE-III [10]) the criteria of dementia were not met (the patient received borderline test score, see Table 1). In the next step, the patient's intellectual functioning was assessed by Wechsler Adult Intelligence Scale-revised (WAIS-R), which can reveal more subtle deficits than cognitive screening scales, give information about the overall level of intellectual functioning, the presence or absence of significant intellectual disability, and provide clues to altered functions [11]. In that measurement tool the patient scored in the borderline range according to expected norms for age (see Table 1). She had major difficulties and slow reactions at analysing and processing information, especially concerning visual tasks. Performance at most verbal tasks in WAIS-R (without time limit), was within low average, however the ability to recall general information (knowledge acquired premorbidly: WAIS-Information) was mildly compromised. Slow learning and low ability to solve a task demanding visual-motor interaction was also noticed (e.g. Digit Symbol). Particular cognitive weaknesses emerged at the tasks in which complex problem solving, working memory and logical reasoning were especially required (e.g. Arithmetic, Picture Arrangement). Selected neuropsychological tests were performed in further assessment (see Table 1), as well as

numerous non-standardized clinical tasks. The ecological, behavioral tests (e.g. Rivermead Behavioural Memory Test (RBMT-III), Test of Everyday Attention (TEA), Behavioural Assessment of Dysexecutive Syndrome (BADS) were also used, however because of lack of Polish norms, their scores could be interpreted mainly clinically. Results of the examination indicated following moderate dysfunctions:

- poor visuoconstruction ability (mostly due to slow processing and impaired planning – e.g. in Rey Complex Figure Test (copy),
- attention deficits (impaired sustained, selective and divided attention, as well as attentional switching – TEA, Trail Making Test),
- executive dysfunction (impaired planning, set shifting and new problem solving ability, tendency toward impulsive, inappropriate reactions and limited use of feedback – BADS, Wisconsin Card Sorting Test, Tower of London),
- mild memory disturbance (diminished effectiveness of learning new information with delayed recall, limited face recognition after short delay, short-term visual memory (e.g. RBMT-III, Benton Visual Retention Test, California Verbal Learning Test, Rey Complex Figure Test (recall),
- reduced efficiency of logical reasoning (diminished abstraction and generalization as well as inferring cause-and-effect relationships (e.g. Wisconsin Card Sorting Test, Picture Arrangement).

Visual perception, examined by clinical agnosia tasks (e.g. objects detection and recognition), was correct. Speech was not overtly impaired, although some slight change in articulation was reported by the patient and her family; occasional mild word-finding difficulties were also noted during conversations. The patient was partly aware of her disease deficits, however, according to the individual interview and Dysexecutive Questionnaire (DEX) scores, she underestimated some executive dysfunctions (e.g. difficulties in planning ability, impulsiveness) and their influence on her everyday functioning. The patient's husband reported some behavioral changes in natural situations, including emotional lability, tendencies toward socially inappropriate reactions, affective dysregulation with occasional inadequate euphoria.

Neuropsychological rehabilitation was implemented, including psychoeducation (about the nature and consequences of the disease) and individual cognitive-behavioral therapeutic training (60–90 min daily). The last was focused mainly on attention, planning, organizing and problem solving abilities, as well as memory strategies (concerning encoding and retrieval of information). The computer-based training (Reha Com, Cogni Plus systems) as well as conventional cognitive exercises with elements of psychological, emotional support were implemented.

Clinical improvement was noticed and follow-up assessment, conducted after five weeks (5 months after the disease onset), revealed better performance at almost all memory tasks, however there were persisting difficulties with face memorizing and detailed current orientation in time and space, as well as with semantic information retrieval. Recognition of verbal information has also improved, but at the same time, a tendency toward false positive errors has

**Table 1 – The results of initial neuropsychological assessment and the follow up after 5 weeks of neuropsychological rehabilitation (main scores).**

Neuropsychological test	Pre-test	Post-test
The Addenbrooke's Cognitive Examination-III (raw scores/maximum)	87/100 (borderline)	92/100 (normal)
Attention	14/18(below average)	17/18 (average)
Memory	25/26 (average)	25/26 (average)
Verbal Fluency	10/14 (low average)	9/14 (below average)
Language	23/26 (low average)	25/26 (average)
Visuospatial Abilities	15/16 (average)	16/16 (average)
<i>Wechsler Adults Intelligence Scale-Revised</i>		
Full-Scale IQ	77 (below average)	
Verbal IQ	89 (average)	
Performance IQ	62 (below average)	
<i>Verbal Tests standard stores</i>		
Information	7 (below average)	
Digit Span	10 (average)	
Vocabulary	8 (average)	
Arithmetic	5 (low score)	
Comprehension	11 (average)	
Similarities	8 (average)	
<i>Performance Tests standard stores</i>		
Picture Completion	5 (low score)	
Picture Arrangement	5 (low score)	
Block Design	4 (very low score)	
Object Assembly	4 (very low score)	
Digit Symbol	3 (very low score)	
<i>Rey Complex Figure Test (percentiles)</i>		
Copy	≤1 (very low score)	≥16% (normal score)
Immediate Recall	3 (very low score)	79 (above average)
<i>Benton Visual Retention Test (results and expected scores)</i>		
Number Correct Score	5 (8) (low score)	5 (2) (low score)
Number Errors Score	8 (8) (normal)	6 (2) (low score)
<i>Trial Making Test (percentiles)</i>		
Part A	75 (<10) (very low score)	48.3 (10–25) (below average)
Part B	243(<10)(very low score)	155 (<10) (very low score)
<i>California Verbal Learning Test (sten scores)</i>		
Total Trials 1–5	4 (low average)	5 (average)
List B Recall	3 (low score)	10 (high score)
Short – Delay Free Recall	4 (low average)	5 (average)
Short – Delay Cued Recall	6 (average)	3 (low score)
Long – Delay Free Recall	6 (average)	6 (average)
Long – Delay Cued Recall	5 (average)	6 (average)
Free Recall Intrusions	10 (high score)	10 (high score)
Recognition Hits	4 (low average)	5 (average)
Recognition Faults	10 (high score)	4 (low average)
<i>Wisconsin Card Sorting Test (percentiles)</i>		
Total Number of Incorrect Responses	5 (low score)	34 (low average)
Perseverative Responses	1 (very low score)	7 (low score)
Perseverative Errors	1 (very low score)	21 (low average)
Non-Perseverative Errors	47 (average)	42 (average)
Percentage Conceptual Level Responses	6 (low score)	45 (average)
Number of Categories Achieves	6–10 (low score)	11–16 (moderately low score)
Learning to Learn	2–5 (low score)	>16 (normal)

emerged. Attention tests scores showed some improvement at most aspects, however not in terms of divided attention and its switching. These problems could have probably secondarily influenced other cognitive processes which was noticeable, among others, as inconsistent performance, significantly worse in dual or rapidly changing tasks. Executive functions, such as planning and new problem solving have also

improved, but mild problems with set-shifting, organizing and monitoring of complex activity were still observed in natural situations. Subjectively the patient felt significant improvement of her everyday functioning, which was also reported by family members. Most of the somatic symptoms (like nausea) resolved, motor impairment decreased and the patient became more active. During follow-up assessment, she



was also more aware of her own difficulties with controlling affective behaviors (e.g. occasional euphoria or irritability, inadequacy in social contacts).

### 3. Conclusion

To date, only several individual SS case studies presented in literature included neuropsychological assessment. These few confirmed interindividual cognitive variability. Generally, it seems there is no one cognitive-behavioral picture which might help clinicians to diagnose SS. There are no such pathognomonic cognitive subcortical features also in other cerebral microangiopathies or in multiple sclerosis, that might help clinicians to recognize a specific disease. Cognitive-behavioral global impairment or focal deficits usually depend on brain damage location and its volume [11]. In our SS patient, despite characteristic focal lesions in corpus callosum, typical callosal disconnection syndrome (e.g. bimanual discoordination, alien hand, ideomotor apraxia, tactile anomia and agraphia in the left hand) was not observed. Although, her executive dysfunctions and behavioral changes might be interpreted cautiously as a frontal callosal disconnection symptoms. During the acute stage of the disease the presented patient was suffering from severe encephalopathy, including primary confusional state. When consciousness disorders disappeared, executive deficits and some non-specific cognitive symptoms, including deficits of various subsystems of attention, as well as generalized memory difficulties and psychomotor slowing were observed. It is worth to be noticed that similar symptoms are frequently reported in small-vessel diseases (SVD), when multifocal or/and diffused brain pathology occurs. Some studies indicated that SVD patients display some cognitive and executive disturbances, e.g. limited speed and precision of perception, processing information as well working memory/attention impairment [12]. The suggested mechanism of this multiple-domain impairment in SVD is a functional disruption of cortico-subcortical circuits regulating cognition including memory-related loops (e.g. hippocampal-anterior thalamic axis loop); frontal hypometabolism observed in neuroimaging might also be a reason of generalized cognitive deterioration in such cases. [13]. Concerning our patient's education level and premorbid social functioning, her cognitive-behavioral decline as an effect of SS was highly probable. A need for neuropsychological rehabilitation was also fully justified. The new contribution of our paper is applying rehabilitation program during recovery process, which might improve outcomes, although in an individual case it is difficult to clearly prove. In three months the patient's psychological state and neurological symptoms mostly improved. However, recovery was not complete and its final effect was difficult to predict. It is known from the literature that some patients generally recover, having slight residual symptoms or even not revealing any, but others remain significantly impaired, in cognitive domain, suffering from gait disturbance or hearing loss. In one research project, aiming to describe SS long-term consequences, neuropsychological symptoms were present at the last follow-up assessment 64% of patients, and their clinical states were recognized by different clinicians as:

'encephalopathy', 'mild psycho-organic syndrome', 'fatigue', 'disorientation', 'mnestic deficits' or 'cognitive impairment'; median disease duration was 4.5 years [14]. Still, there is a lack of long term observations of large group of SS patients, especially in the aspect of detailed cognition and behavior descriptions. Screening cognitive measurement tools (e.g. Mini Mental State Examination) in assessment of SS patients may not be sensitive enough: a detailed neuropsychological examination, based also on ecological valid tests, should be carried out to reveal specific, often mild cognitive-behavioral deficits. This disease affects mostly young people whose return to their social roles remains a great matter of concern. Therefore, special value is the search for optimal forms of their rehabilitation both focused on the restoration of disturbed functions and compensation of permanent deficits in the chronic stage of disease.

### Conflict of interest

None declared.

### Acknowledgement and financial support

We are very grateful to our patient for her cooperation.

### Ethics

The work described in this article has been carried out in accordance with The Code of Ethics of the World Medical Association (Declaration of Helsinki) for experiments involving humans; Uniform Requirements for manuscripts submitted to Biomedical journals.

### REFERENCES

- [1] Susac JO, Egan RA, Rennebohm RM, Lubow M. Susac's syndrome: 1975–2015 microangiopathy/autoimmune endotheliopathy. *J Neurol Sci* 2007;257:270–2.
- [2] Rennebohm R, Susac JO, Egan RA, Daroff RB. Susac's Syndrome – update. *J Neurol Sci* 2010;299:86–91.
- [3] Star M, Gill R, Bruzzone M, De Alba F, Schneck MJ, Biller J. Do not forget Susac syndrome in patients with unexplained acute confusion. *J Stroke Cerebrovasc Dis* 2010;24(4):93–5.
- [4] Vodopivec I, Venna N, Rizzo JF, Prasad S. Clinical features, diagnostic findings, and treatment of Susac syndrome: a case series. *J Neurol Sci* 2015;357(1–2):50–7.
- [5] Feresiadou A, Eriksson U, Larsen HC, Raininko R, Nygren I, Melberg A. Recurrence of Susac Syndrome following 23 years of remission. *Case Rep Neurol* 2014;6:171–5.
- [6] Petty GW, Matteson EL, Younge BR, McDonald TJ, Wood CP. Recurrence of Susac syndrome (retinocochleocerebral vasculopathy) after remission of 18 years. *Mayo Clin Proc* 2001;76:958–60.
- [7] Pawate S, Agarwal A, Moses H, Sriram S. The spectrum of Susac's syndrome. *J Neurol Sci* 2009;30:59–64.
- [8] Petty GW, Engel BR, Younge J, Duffy T, Yanagihara CF, Lucchinetti JD, et al. Retinocochleocerebral vasculopathy. *Medicine (Baltimore)* 1998;77(1):12–40.

- 
- [9] LeMonda BC, Peck CP, Giles KJ, Bowers D. Neurocognitive profile of a woman with Susac's Syndrome: further evidence of cognitive variability. *Clin Neuropsychol* 2015;29(5):689-706.
- [10] Hsieh S, Schubert S, Hoon Ch, Hodges JR. Validation of the Addenbrooke's cognitive examination III in frontotemporal dementia and Alzheimer's disease. *Dement Geriatr Cogn* 2013;36(3-4):242-50.
- [11] Lezak M, Howieson D, Bigler E, Tranel D. *Neuropsychological assessment*. New York: Oxford University Press; 2012.
- [12] Zhou A, Jia J. Different cognitive profiles between mild cognitive impairment due to cerebral small vessel disease and mild cognitive impairment of Alzheimer's disease origin. *J Int Neuropsychol Soc* 2009;15:898-905.
- [13] Reed BR, Eberling JL, Mungas D, Weiner M, Kramer JH, Jagust WJ. Effects of white matter lesions and lacunes on cortical function. *Arch Neurol* 2004;61:1545-50.
- [14] Jarius S, Kleffner I, Dörr JM, Sastre-Garriga J, Illes Z, Eggenberger E, et al. Clinical, paraclinical and serological findings in Susac syndrome: an international multicenter study. *J Neuroinflammation* 2014;11:46.