



10 George M, Singhal V, Sharma V, Nopper AJ. Successful surgical excision of a complex vascular lesion in an infant with Kasabach-Merritt syndrome. *Pediatr. Dermatol.* 2002; **19**: 340–4.

11 Phillips WG, Marsden JR. Kasabach-Merritt syndrome exacerbated by platelet transfusion. *J. R. Soc. Med.* 1993; **86**: 231–2.

Ischemic stroke in Kawasaki disease

Wasana Prangwatanagul and Alisa Limsuwan

Division of Pediatric Cardiology, Department of Pediatrics, Ramathibodi Hospital, Mahidol University, Bangkok, Thailand

Abstract Pediatric stroke is considered to be rare. Stroke resulting from cerebral vasculitis is also uncommon in young children. With the increasing prevalence of Kawasaki disease (KD) diagnosis, this acquired vasculitis has been reported with various clinical presentations including neurological symptoms. Herein we describe the case of a KD patient presenting with stroke. A 15-month-old boy was referred due to stroke that occurred on the fifth day of febrile illness. He was initially admitted to another hospital due to fever and diarrhea. He was discharged and re-admitted 2 days afterward due to left hemiplegia. During the 10 days of the second hospitalization, he had a presumptive diagnosis of encephal meningitis. Upon referral to the present hospital, he was found to have right middle cerebral artery branch stenosis and fusiform aneurysms of the coronary arteries. Retrospectively, the patient had the full clinical criteria for KD diagnosis. Therefore, stroke could be considered as one of the uncommon clinical manifestations of KD.

Key words children, coronary aneurysm, Kawasaki disease, stroke, vasculitis.

Cerebral vascular accident or stroke in infants and young children is uncommon. Pediatric stroke due to cerebral vasculitis is also particularly rare in infants and toddlers. The prevalence of Kawasaki disease (KD), the most common acquired systemic vasculitis in young children, has increased after the introduction of guidelines for KD diagnosis. This acquired medium-sized vasculitis has been reported with a wide variety of clinical presentations in various different organ systems, including neurological symptoms. The neurological involvement in KD is usually asymptomatic, with only 1.1% of children with KD having neurological deficits.¹ The majority of the deficits are facial palsy, and there are few reports on cerebral vascular accident as a complication of KD or its treatment. Herein we describe a case of pediatric stroke as one of the clinical manifestation of KD.

Case report

A previously healthy 15-month-old boy was referred due to ischemic stroke. His mother recognized that he had weakness on the left side of his body for 10 days prior to the referral. According to his mother, he had been in his usual state of

health until 15 days previously, when he had skin lesions on his left sole that were initially diagnosed as hand-foot-mouth syndrome by a primary care physician. The following day, he developed fever and diarrhea and he was hospitalized for rehydration and gastroenteritis treatment at a local hospital. During that admission, he developed generalized urticarial rash. His mother later recalled that his lips were also cracked and bright red. He had conjunctival injection without secretion. The fever and symptoms eventually subsided on the fourth day of hospitalization and the patient was discharged. He was re-admitted 2 days afterward due to left hemiplegia. The referral letter indicated that his mother noticed he had weakness on the left side of his body since hospital discharge or 5 days after fever (Fig. 1). Physical examination confirmed muscle motor power grade I/V in the left upper and lower extremities, compared with grade V/V in the right extremities. Initial computed tomography (CT) at the local hospital showed a large and ill-defined hypodensity area in the right cerebral hemisphere with mild cerebral edema. There was leptomeningeal enhancement with contrast injection. Lumbar puncture was normal, without white blood cells in the cerebrospinal fluid. Presumptive diagnosis was encephal meningitis. He was treated with cephalosporins, vancomycin and acyclovir during the 8 days of his second hospital stay. Subsequently he was referred to the present institute for further investigation and management.

Upon arrival at the present center, he was afebrile. Periungual desquamation was observed on both hands. On

Correspondence: Alisa Limsuwan, MD, Division of Pediatric Cardiology, Ramathibodi Hospital, Rama VI Road, Bangkok 10400, Thailand. Email: alimsuwan@yahoo.com

Received 12 November 2015; revised 7 July 2016; accepted 1 September 2016.

doi: 10.1111/ped.13170

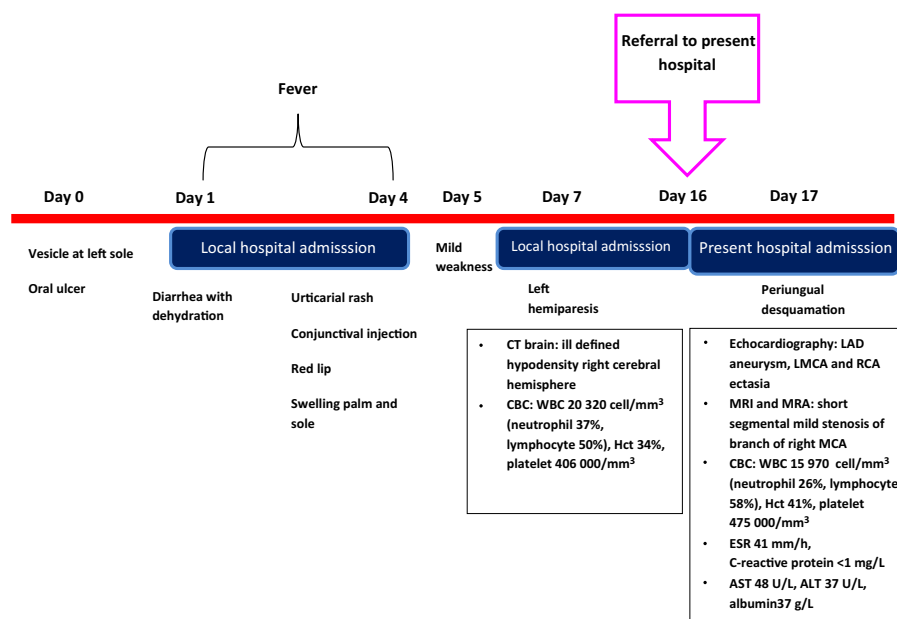


Fig. 1 Clinical course. ALT, alanine aminotransferase; AST, aspartate aminotransferase; CBC, complete blood count; CT, computed tomography; ESR, erythrocyte sedimentation rate; Hct, hematocrit; LAD, left anterior descending artery; LMCA, left middle coronary artery; MRA, magnetic resonance angiography; MRI, magnetic resonance imaging; RCA, right coronary artery; WBC, white blood cells.

neurological examination he was fully conscious with left facial palsy and left hemiplegia, with motor power grade II/V in the left upper and lower extremities. Other physical findings were normal. Repeated CT (9 days after the initial scan or 15 days after the fever) showed a well-defined hypo-density lesion involving gray and white matter at the right fronto-parieto-temporal lobe, insular cortex and right basal ganglion, suggestive of subacute right middle cerebral artery infarction. Brain magnetic resonance imaging showed a large hypointense T1, hyperintense T2 signal with gyral enhancement involving the right fronto-parieto-temporal lobe, right caudate nucleus, right lentiform nucleus, right internal and external capsule, and right insular lobe. Several tiny susceptibilities at the right basal ganglia area were also detected, suggestive of associated microhemorrhage. The findings were compatible with subacute infarction of the right middle cerebral artery territory. Brain magnetic resonance angiography (MRA) showed short segmental mild stenosis at the proximal M2 segment of the superior and inferior branches of the right middle cerebral artery. The other intracranial and cervical vessels were normal. No evidence of aneurysm or vascular malformation was seen (Fig. 2). Cardiac echocardiogram was requested as part of the stroke in the young evaluation. Bodyweight was 9.8 kg and height was 78 cm. Cardiac structure was normal without patent foramen ovale. No thrombus was visualized in any cardiac chambers. The coronary arteries were prominently dilated, including left middle coronary artery (LMCA; 4 mm; z-score, +4.95), left circumflex artery (LCx; 2.9 mm); and right coronary artery (RCA; 2.6 mm; z-score, +2.96) ectasia. There was a fusiform aneurysm of the left anterior descending

artery (LAD; 3 mm; z-score, +5.45; Fig. 3). Electrocardiogram indicated normal sinus rhythm, with heart rate 110 beats/min and non-specific ST depression in V1.

Laboratory investigation indicated borderline elevation of inflammatory markers (erythrocyte sedimentation rate, 41 mm/h; C-reactive protein, <1 mg/dL), leukocytosis (white blood cells, 15 970/mm³), thrombocytosis (platelets, 475 000/mm³), and transaminitis (aspartate aminotransferase, 48 U/L). Other cause of prothrombotic state (including anti-dsDNA, homocystine, anti-thrombin III, protein C, protein S, and lupus anticoagulant) were normal.

After review of the investigation and retrospective re-evaluation of the patient's condition, KD was the most likely diagnosis in this patient. CT angiogram showed fusiform aneurysm of the LAD, and regression of the LMCA/LCx and RCA ectasia without thrombosis. There was no evidence of vascular aneurysm or stenosis of the aorta and its branches.

Discussion

Kawasaki disease is the most common acquired systemic vasculitis predominantly involving the medium-sized vessels. With the introduction of guidelines for KD diagnosis, the number of diagnosed cases of KD has increased due to increased awareness of the disease and also additional supplement criteria for incomplete KD diagnosis. Although the clinical criteria are simple and straight forward, diagnosis of KD remains complicated in some cases. In the present case, KD was retrospectively diagnosed after investigation for stroke in

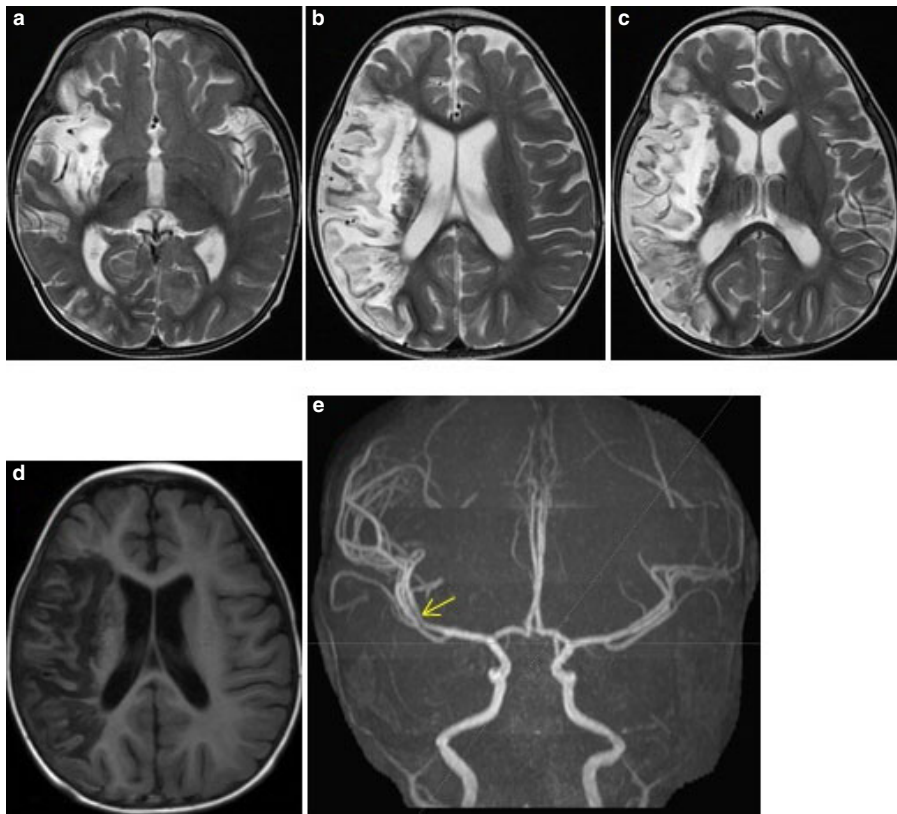


Fig. 2 Brain magnetic resonance angiography showing (a–c) large hyperintense T2-weighted lesion and (d) hypointense T1 imaging with gyral enhancement involving the right fronto-parieto-temporal lobe, right caudate nucleus, right lentiform nucleus, right internal and external capsule, and right insular lobe; (e) short segmental mild stenosis at the proximal M2 segment of the superior and inferior branches of the right middle cerebral artery. The rest of the intracranial and cervical vessels appeared normal.

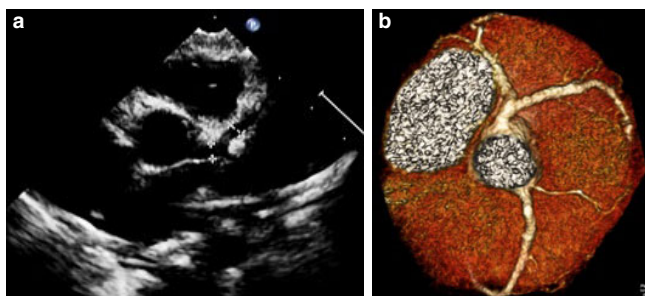


Fig. 3 (a) Echocardiogram showing the prominently dilated coronary arteries (left middle coronary artery, 4 mm; left circumflex artery, 2.9 mm) and a fusiform aneurysm of the left anterior descending artery (3 mm). Ectasia was noted in the right coronary artery (2.6 mm). (b) Computed tomography angiogram showing the fusiform aneurysm of the left anterior descending artery with regression of the coronary ectasia.

the young, which identified abnormal coronary arteries. This prompted the recalled signs and symptoms of KD including the rash, injected conjunctiva, fissured lips and peripheral edema, and desquamation along with the 4 day fever. The stroke was noted on the fifth day after the first documented fever. We considered that stroke was also one of the KD

clinical manifestations in this case. Previous reports of stroke in KD cases could not clarify whether the stroke was the manifestation of KD or the complication of treatment, particularly the i.v. immunoglobulin (IVIG) therapy. The potential explanations for IVIG-related thrombosis include increased blood viscosity,² increased thrombin production due to contamination by coagulation factor XI,³ or a direct effect of IVIG on the vascular endothelium.⁴ In the present case, the KD was diagnosed 15 days after fever when the child was afebrile. The patient had not received IVIG. The abnormal narrowing of the superior and inferior branches of the right middle cerebral artery seen on brain MRA on the 17th day after KD onset is suggestive of an acquired inflammatory KD process. The neurological symptom, manifesting on the fifth day after fever, could be the result of the arteritis along with the increased coagulation activity. The blood flow at this arteritis area abruptly decreased due to the vessel wall inflammation and also to the aggregation of the platelets from the thrombocytosis during the inflammatory phase of KD. The other cause of cerebral vascular lesion causing stroke in the young is cerebral arterial dissection, which is extremely rare, especially when it occurs spontaneously, and has never been reported in KD. In the present case, the patient had fulfilled the clinical criteria for KD diagnosis, and the ischemic stroke was considered to

Table 1 Literature review of cerebral infarction associate with Kawasaki Disease.

	Wada <i>et al.</i> (2006) ¹¹	Sebatier <i>et al.</i> (2013) ⁴	Muneuchi <i>et al.</i> (2006) ⁷	Lapointe <i>et al.</i> (1984) ⁹	Tanaka <i>et al.</i> (2007) ⁵	Ahn <i>et al.</i> (2010) ⁶	Suda <i>et al.</i> (2003) ¹²	Fujiwara <i>et al.</i> (1992) ¹³
Country	Japan	France	Japan	East Indian born in Canada (immigrants)	Japan	Korea	Japan	Japan
Age/sex	3 years/M	18 months/F	4 years/M	4 months/M	3 years/M	6 months/M	8 months/M	22 months/M
Signs and symptoms	Fever 5 days + inflamed conjunctivae, strawberry tongue, edema of the peripheral extremities, and diffuse rash	Fever 10 days + rash, edema, cervical LN, fissured lips, bilateral conjunctival injection	Fever 5 days + conjunctival injection, reddish lips and oral cavity, cervical lymphadenopathy, macular rash and edematous palms and soles	Fever persisting 38–39°C daily Unresponsive to ampicillin and cephalixin Diarrhea, rash over the upper chest, upper arms and diaper area Three weeks after the onset of fever, he was started on oral prednisone twice a day 45 days: seizure × 2, left hemiplegia	Age 1 years: Cerebral palsy Age 3 years: KD Age 12 years 7 months: high fever from an unknown etiology for 3 days, Echo: mild dilatation of the left main trunk	Fever 5 days + bilateral conjunctival injection, redness on the lip and tongue, edematous hands and feet Hepatomegaly	8 months/M ?	22 months/M ?
Stroke onset after illness	10 days after fever: motor aphasia and right hemiplegia 4 days after IVIG	11 days: right hemiplegia, left ptosis	21 days		Age 9 years	Age 7 months: generalized tonic-clonic seizure and lethargy	20 days: right hemiparesis	59 days: asymptomatic
Brain imaging	Left cerebral infarction mainly in the parieto-temporal lobe and the left basal ganglia (territory of left MCA infarction)	MRI: extended infarct territory of left MCA MRA: complete ipsilateral occlusion of ICA extending from origin to distal MCA	MRI: subacute phase of cerebellar infarction MRA: obliteration or severe stenosis of right PICA	CT: right-sided cerebral infarct involving mainly the right parietal lobe Cerebral angiography and aortography: occlusion of the parietal and temporo-occipital branches of the right MCA and widespread aneurysmal changes of the extracerebral vessels Age 5½ months: large numerous aneurysms of both coronary arteries measuring at least 1.5-fold that of normal 5 years: Normal contractility moderate fusiform dilatation of both branches of the LCA	Age 9 years: normal MRI brain CT: SAH CTA: saccular cerebral aneurysm arising from the right PCA and the right posterior communicating artery junction	Age 9 years: normal MRI brain CT: SAH MRA: saccular aneurysm at the left MCA bifurcation	Irregular stenosis of the left MCA	Systematic discovery of infarction of the right MCA deep territory
Echocardiography	No coronary artery aneurysm	Normal	15th day of illness: left coronary dilatation (7 mm), perivascular brightness Coronary angiography on the 37th day of illness: dilatation of the proximal LCA (8 mm)	Age 5½ months: large numerous aneurysms of both coronary arteries measuring at least 1.5-fold that of normal 5 years: Normal contractility moderate fusiform dilatation of both branches of the LCA	Mild dilatation of the left main trunk, LVEF 73%	Echocardiography at 5 months postoperatively showed no aneurysmal change in coronary arteries	–	Coronary aneurysm
Kawasaki treatment	IVIG 1 g/kg × 2 days (fever days 5–6) Aspirin 50 mg/kg/day started on the sixth day of fever	IVIG 2 g/kg (fever day 10)	Aspirin at fever day 3 IVIG 1 g/kg at fever day 5 → no response: repeated IVIG total 6 g/kg Pulse methylprednisolone in combination with heparin on the 11th day of illness Warfarin after CTA coronary artery	None	None	IVIG 2 g/kg, followed by aspirin for 6 weeks	After evidence of thrombosis in coronary artery aneurysm: Aspirin IVIG Intracoronary thrombolysis (occurred before IVIG treatment)	Aspirin IVIG Anticoagulants
Stroke treatment	Observation	Enoxaparin × 1 week, followed by ASA 75 mg/day	Observation	Azathioprine, prednisone 17 months Phenobarbital and phenytoin 22 months	Operation for neck clipping	Emergency craniectomy and clip occlusion of the aneurysm	–	None

ASA, aspirin; CT, computed tomography; CTA, computed tomography angiography; Hct, hematocrit; ICA, internal carotid artery; IVIG, i.v. immunoglobulin; KD, Kawasaki disease; LCA, left coronary artery; LP, lumbar puncture; LVEF, left ventricular ejection fraction; MCA, middle cerebral artery; MRA, magnetic resonance angiography; MRI, magnetic resonance imaging; PCA, posterior cerebral artery; PICA, posterior inferior cerebellar artery; plt, platelets; SAH, subarachnoid hemorrhage.

be one of the complications due to the right middle cerebral arteritis.

In the present case, the echocardiographic finding was one of the strong laboratory criteria for KD diagnosis, along with the four clinical criteria. In KD, inflammatory processes in the vessel wall, especially in the coronary arteries (coronary arteritis), result in formation of coronary aneurysms. Aneurysms may occur in other extra-parenchymal muscular arteries such as the celiac, mesenteric, femoral, iliac, renal, axillary, and brachial vessels.¹ Therefore, cerebral arteries can be involved in the systemic vasculopathy of KD, as can many other extracoronary arteries.⁵⁻⁷ Histopathology on autopsy of some patients with KD indicated cerebrovascular changes, such as endoarteritis, periarteritis, perivascular cuffing, and the focal necrotizing vasculitis.⁸ Several cases have been reported of coronary artery aneurysm with stroke, and imaging showed systemic vasculopathy or aneurysm involving the cerebral artery.^{9,10} In the present case, the patient had coronary artery aneurysm with cerebral artery stenosis. One could argue whether these two findings were part of the same disease process or were caused by two different diseases, but we consider that KD was the cause of these vascular abnormalities. The level of vascular inflammatory involvement and healing in various vessels may occur in different stages. To our knowledge there have been only eight cases of arterial ischemic stroke in KD children who had not received IVIG prior to the stroke, and only two of these patients had cerebral artery stenosis (Table 1).

Kawasaki disease shares several features with polyarteritis nodosa. In the present case, the patient underwent CT angiogram to clarify other artery involvement, but the evidence of abnormal arteries was limited to the cerebral and coronary arteries, which is more consistent with a KD diagnosis. Other autoimmune diseases had been ruled out on laboratory tests.

This study has several limitations due to the nature of retrospective reporting. The etiology and pathophysiology could not be confirmed. Further prospective cohort studies with a larger number of patients are warranted for better understanding of the pathophysiological changes in KD.

In conclusion, stroke could be one of the presenting symptoms of KD in young children with a history of fever. Clinical awareness and thorough investigation are needed to ensure successful KD diagnosis in unusual case presentations.

Disclosure

The authors declare no conflict of interest.

Author contributions

W.P. and A.L. carried out patient investigation and management. W.P. wrote the initial draft of the manuscript. A.L. critically reviewed and revised the manuscript. All authors read and approved the final manuscript.

References

- 1 Terasawa K, Ichinose E, Matsuishi T, Kato H. Neurological complications in Kawasaki disease. *Brain Dev.* 1983; **5**: 371–4.
- 2 Dalakas MC. High-dose intravenous immunoglobulin and serum viscosity: risk of precipitating thromboembolic events. *Neurology* 1994; **44**: 223–6.
- 3 Wolberg AS, Kon RH, Monroe DM, Hoffman M. Coagulation factor XI is a contaminant in intravenous immunoglobulin preparations. *Am. J. Hematol.* 2000; **65**: 30–4.
- 4 Sabatier I, Chabrier S, Brun A, *et al.* Stroke by carotid artery complete occlusion in Kawasaki disease: case report and review of literature. *Pediatr. Neurol.* 2013; **49**: 469–73.
- 5 Tanaka S, Sagiuchi T, Kobayashi I. Ruptured pediatric posterior cerebral artery aneurysm 9 years after the onset of Kawasaki disease: a case report. *Childs Nerv. Syst.* 2007; **23**: 701–6.
- 6 Ahn JH, Phi JH, Kang HS, *et al.* A ruptured middle cerebral artery aneurysm in a 13-month-old boy with Kawasaki disease. *J. Neurosurg. Pediatr.* 2010; **6**: 150–3.
- 7 Muneuchi J, Kusuhara K, Kanaya Y, *et al.* Magnetic resonance studies of brain lesions in patients with Kawasaki disease. *Brain Dev.* 2006; **28**: 30–3.
- 8 Amano S, Hazama F, Hamashima Y. Pathology of Kawasaki disease: II. Distribution and incidence of the vascular lesions. *Jpn. Circ. J.* 1979; **43**: 741–8.
- 9 Lapointe JS, Nugent RA, Graeb DA, Robertson WD. Cerebral infarction and regression of widespread aneurysms in Kawasaki's disease: case report. *Pediatr. Radiol.* 1984; **14**: 1–5.
- 10 Templeton PA, Dunne MG. Kawasaki syndrome: cerebral and cardiovascular complications. *J. Clin. Ultrasound* 1987; **15**: 483–5.
- 11 Wada Y, Kamei A, Fujii Y, Ishikawa K, Chida S. Cerebral infarction after high-dose intravenous immunoglobulin therapy for Kawasaki disease. *J. Pediatr.* 2006; **148**: 399–400.
- 12 Suda K, Matsumura M, Ohta S. Kawasaki disease complicated by cerebral infarction. *Cardiol. Young* 2003; **13**: 103–5.
- 13 Fujiwara S, Yamano T, Hattori M, Fujiseki Y, Shimada M. Asymptomatic cerebral infarction in Kawasaki disease. *Pediatr. Neurol.* 1992;**8**:235–6.