



Contents lists available at ScienceDirect

Journal of Clinical Neuroscience

journal homepage: [www.elsevier.com/locate/jocn](http://www.elsevier.com/locate/jocn)

## Case study

## De novo superior cerebellar artery aneurysm following radiosurgery for trigeminal neuralgia

Joseph C.T. Chen <sup>a,\*</sup>, Kuo Chao <sup>b</sup>, Javad Rahimian <sup>c</sup><sup>a</sup> Department of Neurological Surgery, Southern California Permanente Medical Group, 4950 Sunset Boulevard, Los Angeles, CA, USA<sup>b</sup> Division of Interventional Radiology, Southern California Permanente Medical Group, 4950 Sunset Boulevard, Los Angeles, CA, USA<sup>c</sup> Department of Radiation Oncology, Southern California Permanente Medical Group, 4950 Sunset Boulevard, Los Angeles, CA, USA

## ARTICLE INFO

## Article history:

Received 2 October 2016

Accepted 26 December 2016

Available online xxxxx

## Keywords:

Trigeminal neuralgia

Radiosurgery

Aneurysm

Radiation

Linear accelerator

## ABSTRACT

Stereotactic radiosurgery is a commonly used method for treatment of trigeminal neuralgia. Radiation has been known to be a factor in the later development of aneurysms. Aneurysms have been reported to occur after radiation delivered in a variety of methods including both externally delivered radiation radiosurgery and brachytherapy. We report here an incidence of a de novo aneurysm presenting following radiosurgery treatment for trigeminal neuralgia. The patient was treated using frame-based LINAC radiosurgery receiving 90 Gy to the mid cisternal extent of the nerve via a 4 mm conical collimator. The patient presented with progressive hypoesthesia 11 years after treatment. Imaging evaluation demonstrated the presence of an aneurysm abutting the treated trigeminal nerve. The aneurysm was successfully coil embolized. The patient's facial hypoesthesia, however, did not improve following embolization. We believe that this is the first report of such an aneurysm occurring after radiosurgery for trigeminal neuralgia. De novo aneurysms are a recognized long term complication of radiotherapy and radiosurgery treatment. This report shows such aneurysms can occur with very small treatment volumes. Late sensory changes following radiosurgery for trigeminal neuralgia should prompt workup for de novo aneurysms as well as other late adverse radiation effects.

© 2017 Elsevier Ltd. All rights reserved.

## 1. Introduction

Stereotactic radiosurgery is a commonly used method for treatment of medically refractory trigeminal neuralgia. It has a number of compelling features including its minimally invasive technique allowing for safe treatments in patients who are of advanced age or poor medical risk. Complications are rare using small collimators (4 mm) and doses up to 90 Gy [1–4]. The most common complications resulting from trigeminal neuralgia radiosurgery include facial hypoesthesia, dysesthesias, and keratoconjunctivitis.

Radiation has been known to be a factor in the later development of aneurysms. Aneurysms have been reported to occur after radiation delivered in a variety of methods including both externally delivered radiation and brachytherapy [5].

We report here an incidence of an aneurysm presenting 11 years following radiosurgery treatment for trigeminal neuralgia

and its management. We believe that this is the first report of such an aneurysm occurring after radiosurgery for trigeminal neuralgia.

## 2. Case report

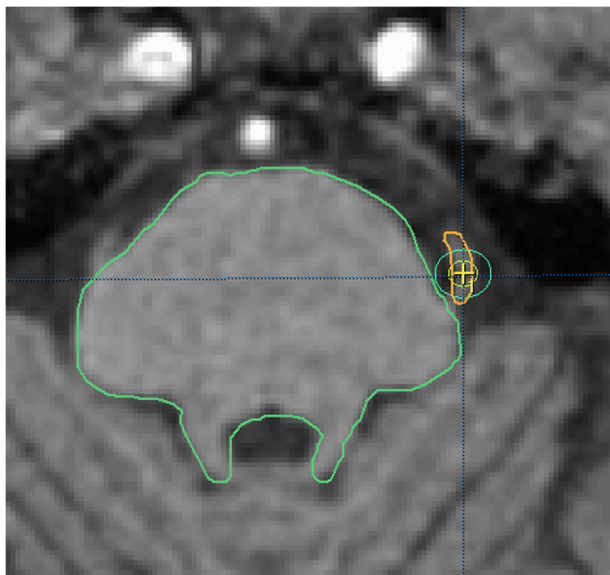
A 79 year old male with history of medically refractory left sided trigeminal neuralgia presented to our service 2003 for consultation. The patient's pain was in the left V1 and V2 distribution. The pain was poorly controlled despite a dose of 1800 mg of carbamazepine per day. Examination demonstrated no evidence of facial hypoesthesia.

The patient elected for radiosurgery treatment. The patient underwent application of stereotactic frame and linear accelerator radiosurgery as previously described [6]. A dose of 90 Gy was delivered via a 4 mm conical collimator to the proximal cisternal extent of the trigeminal nerve (presented in Fig. 1).

The patient had an excellent pain free result and was able to discontinue his medical therapy. Good relief occurred within 24 h of the treatment. 18 months following his treatment, the patient presented to the clinic for routine follow-up with complaint of new mild hypoesthesia in the V1 and V2 distribution, confirmed on examination. He maintained excellent relief of pain.

\* Corresponding author at: University of Southern California Neurorestoration Center, McKibben Hall B51A-G MC 9153, 1333 San Pablo Street, Los Angeles, CA 90089, USA.

E-mail address: [jctc01@gmail.com](mailto:jctc01@gmail.com) (J.C.T. Chen).



**Fig. 1.** Non-contrast 3D-SPGR image obtained for treatment planning to left trigeminal nerve. Isodose lines are 80% and 50%.

32 months following treatment, the patient presented again to the clinic for routine follow-up with continued pain-free result. The previously seen hypoesthesia had improved. He maintained an excellent result with no pain off of medications.

The patient was then lost to follow-up until 2012, nine years following treatment, when the patient had decline of right sided (contralateral) hearing. An MRI of the internal auditory canals was obtained and was unremarkable (Fig 2). Review of the imaging demonstrated no visible abnormalities in the vicinity of the left trigeminal nerve.

The patient then presented in 2014, eleven years after treatment, at the age of 90 years, complaining of a two-month course of worsening numbness involving the entire left side of the face. The patient was referred back to our service. An MRI with intravenous contrast was then ordered. The study demonstrated evidence of a left sided mass at the trigeminal root entry zone (Fig 2). An MRA, demonstrated an 8 mm aneurysm of the superior cerebellar artery on the left side corresponding with the previously identified mass.

The patient then underwent angiography demonstrating an aneurysm of the superior cerebellar artery. The patient then underwent coil embolization. A total of 8 Hypersoft 3D coils (Microvention, Tustin, California, USA) were placed resulting in occlusion of the aneurysm (Fig. 3). The patient tolerated the procedure without complications. Follow up MRA one year after the procedure showed durable occlusion of the aneurysm.

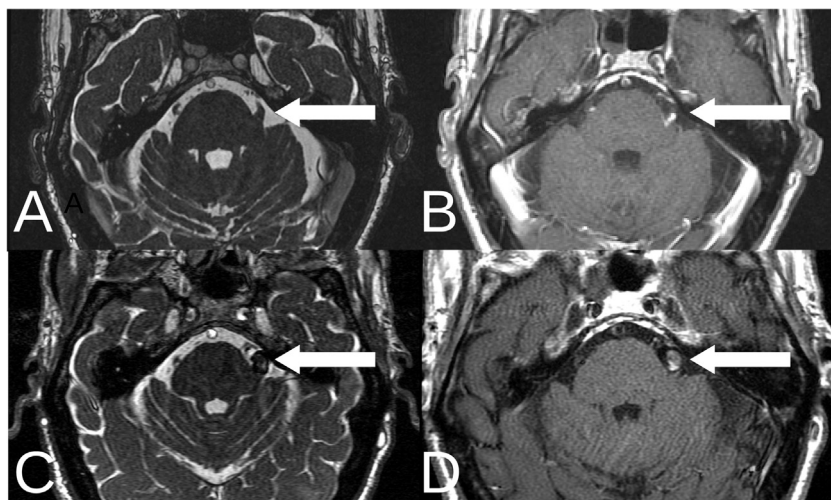
Despite successful occlusion of the aneurysm, he continues to have dense facial hypoesthesia. He remains otherwise pain free and off of trigeminal neuralgia medications. Follow-up MRA one year after embolization demonstrated no evidence of aneurysm recanalization.

### 3. Discussion

The cause of trigeminal neuralgia remains poorly understood and is likely due to a number of underlying factors. The association between neurovascular conflict and trigeminal neuralgia is well known to neurosurgeons, although it is becoming clear that neurovascular conflict is neither necessary nor sufficient to the development of trigeminal neuralgia [7]. Nevertheless, neurovascular conflict is seen in most cases where radiosurgery is used for the treatment of trigeminal neuralgia [8,9]. As such, conflicting vessels may be commonly exposed to very high doses of radiation as a consequence of treatment.

The effects of radiation on tissues are complex. The generation of free radicals is thought to mediate the effects of radiation on tissues via induction of apoptosis, prevention of cellular division via DNA damage and induction of secondary inflammatory responses [10]. The effects of radiosurgery on vasculature are understood to involve intimal hyperplasia resulting in hyaline changes within vessel walls. This often results in stenosis of vessels and reduction of flow [11].

Radiation exposure of conflicting vessels involved in trigeminal neuralgia treatments has been shown to result in variable incidences of atherosclerosis and arachnoidal thickening in the region of the radiosurgery treatment [12]. Despite these changes, which are commonly seen, there have been no reports to this date in the literature of either hemorrhage or cerebral infarction as a complication of radiosurgery treatment for trigeminal neuralgia. A study by Lorenzoni et al. involving 16 patients treated with radiosurgery for trigeminal neuralgia followed for a mean of approximately two years demonstrated no incidences of superior



**Fig. 2.** 3D-FIESTA and 3D-SPGR with contrast images two years prior to presentation (Panels A and B). 3D-FIESTA and 3D-SPGR with contrast images at time of presentation (Panel C and D) with demonstration of new lesion. Arrows demonstrates location of left trigeminal nerve and associated lesion.

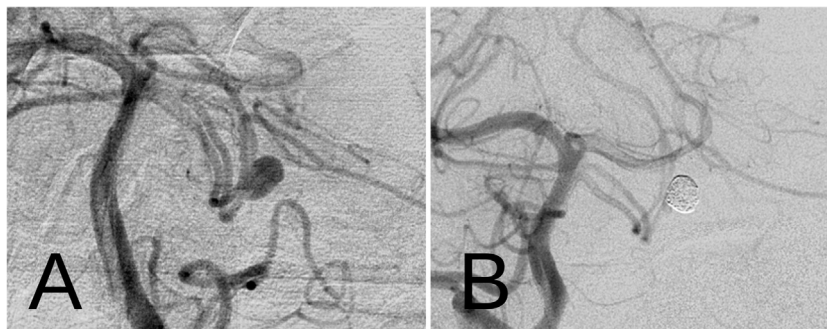

Fig. 3. AP projection digital angiography prior to (Panel A) and following embolization (Panel B).

cerebellar artery stenosis within the treatment volume and no evidence of ischemia or stroke [13]. In two reports detailing results of microvascular decompression for recurrence of pain following radiosurgery, no aneurysmal dilatations were seen in over 70 patients reported [14,15], although varying degrees of arachnoid thickening, adhesions and atherosclerotic changes were seen.

De novo aneurysm formation has been reported following various radiation modalities. In their exhaustive review, Nanney et al. found 70 de novo aneurysms reported in the literature [5]. This includes radiosurgery for cerebral arteriovenous malformation [16], acoustic neuroma (vestibular schwannoma) [17–19] and meningioma [20,21]. Fractionated stereotactic radiotherapy has also been reported as an antecedent to de novo formation of aneurysm [22].

A number of reports have been accompanied by histological analysis of resected aneurysm fragments with relatively uniform results. Typical descriptions include intimal thickening, inflammatory cell infiltration and fibrous degeneration [5]. Of interest, however, have been sporadic reports of use of radiosurgery for treatment of cerebral aneurysms. Steiner et al. in 1993 had mentioned their use of radiosurgery for treatment of cerebral aneurysms [23] and this has been recently attempted by others with apparent success [24]. Use of this technique, however, is not broadly embraced.

The relative rupture risk of radiation induced cerebral aneurysms in comparison to spontaneously occurring aneurysms is unknown. A number of reports in the literature, however, have shown that these aneurysms can rupture leading to catastrophic results. In a recent review of the literature, 55% of reported radiation related aneurysms presented with hemorrhagic complications and only 15% presented incidentally [5]. It would be prudent therefore to recommend that such aneurysms be treated upon discovery.

Radiosurgery for neoplasms often requires lifetime patient follow-up. In such cases, aneurysms may be detected on routine imaging prior to development of symptoms allowing for early intervention. Furthermore, radiosurgery for arteriovenous malformations may be associated with late complications such as radiation necrosis and cyst formation suggesting that long term imaging follow up is a reasonable option for patients who have been treated for tumors [25].

For trigeminal neuralgia, however, imaging follow-up is not routinely employed where patients have had excellent pain free outcomes, such as in this report. The discovery of this aneurysm 11 years following treatment and two years following an apparent normal MRI demonstrates that radiation related aneurysms may occur over a relatively short time frame many years after the initial treatment. The apparently low incidence of aneurysm formation after trigeminal radiosurgery makes it difficult to recommend routine imaging follow up as the yield of actionable data may not jus-

tify the cost and inconvenience of frequent imaging. Nevertheless, patients may be made aware of the very small risk of permanent disabilities or fatality as a long term potential complication of trigeminal radiosurgery during the informed consent process. Late occurring new neurological symptoms including sensory changes should be a strong indication for follow up imaging.

While concerning, the overall incidence of aneurysm formation is extremely low in comparison to the large numbers of patients treated for various indications. This along with excellent patient acceptance and preservation of quality of life continues to make radiosurgery the initial treatment of choice for many patients presenting with trigeminal neuralgia.

#### 4. Conclusion

We describe here the first reported case of de novo aneurysm formation after stereotactic radiosurgery for trigeminal neuralgia. The patient was treated successfully with embolization. Imaging should be used to evaluate patients presenting with late sensory changes after trigeminal radiosurgery.

#### References

- [1] Chen JC, Rahimian J, Rahimian R, et al. Frameless image-guided radiosurgery for initial treatment of typical trigeminal neuralgia. *World Neurosurg* 2010;74:538–43.
- [2] Tawk RG, Duffy-Fronckowiak M, Scott BE, et al. Stereotactic gamma knife surgery for trigeminal neuralgia: detailed analysis of treatment response. *J Neurosurg* 2005;102:442–9.
- [3] Dhople A, Kwok Y, Chin L, et al. Efficacy and quality of life outcomes in patients with atypical trigeminal neuralgia treated with gamma-knife radiosurgery. *Int J Radiat Oncol Biol Phys* 2007;69:397–403.
- [4] Regis J, Metellus P, Hayashi M, et al. Prospective controlled trial of gamma knife surgery for essential trigeminal neuralgia. *J Neurosurg* 2006;104:913–24.
- [5] Nanney 3rd AD, El Tecle NE, El Ahmadieh TY, et al. Intracranial aneurysms in previously irradiated fields: literature review and case report. *World Neurosurg* 2014;81:511–9.
- [6] Chen JC, Girvigian M, Greathouse H, et al. Treatment of trigeminal neuralgia with linear accelerator radiosurgery: initial results. *J Neurosurg* 2004;101 (Suppl. 3):346–50.
- [7] Lee A, McCartney S, Burbidge C, et al. Trigeminal neuralgia occurs and recurs in the absence of neurovascular compression. *J Neurosurg* 2014;120:1048–54.
- [8] Brisman R, Khandji AG, Mooij RB. Trigeminal nerve-blood vessel relationship as revealed by high-resolution magnetic resonance imaging and its effect on pain relief after gamma knife radiosurgery for trigeminal neuralgia. *Neurosurgery* 2002;50:1261–6 [discussion 6–7].
- [9] Zerris VA, Noren GC, Shucart WA, et al. Targeting the cranial nerve: microradiosurgery for trigeminal neuralgia with CISS and 3D-flash MR imaging sequences. *J Neurosurg* 2005;102(Suppl):107–10.
- [10] Hall E. Radiobiology for the radiologist. Philadelphia: Lippincott; 2000.
- [11] Schneider BF, Eberhard DA, Steiner LE. Histopathology of arteriovenous malformations after gamma knife radiosurgery. *J Neurosurg* 1997;87:352–7.
- [12] Maher CO, Pollock BE. Radiation induced vascular injury after stereotactic radiosurgery for trigeminal neuralgia: case report. *Surg Neurol* 2000;54:189–93.
- [13] Lorenzoni J, David P, Levivier M. MR-based follow-up of the superior cerebellar artery after radiosurgery for trigeminal neuralgia. *Clin Neurol Neurosurg* 2011;113:758–61.

- [14] Sekula Jr RF, Frederickson AM, Jannetta PJ, et al. Microvascular decompression after failed Gamma Knife surgery for trigeminal neuralgia: a safe and effective rescue therapy? *J Neurosurg* 2010;113:45–52.
- [15] Chen JC. Microvascular decompression for trigeminal neuralgia in patients with and without prior stereotactic radiosurgery. *World Neurosurg* 2012;78:149–54.
- [16] Akai T, Torigoe K, Fukushima M, et al. De novo aneurysm formation following gamma knife surgery for arteriovenous malformation: a case report. *J Neurol Surg Rep* 2015;76:e105–8.
- [17] Hughes JD, Osetinsky LM, Jacob JT, et al. Incidentally discovered unruptured AICA aneurysm after radiosurgery for vestibular schwannoma: a case report and review of the literature. *Otol Neurotol* 2015;36:1428–31.
- [18] Huang PP, Kamiryo T, Nelson PK. De novo aneurysm formation after stereotactic radiosurgery of a residual arteriovenous malformation: case report. *AJNR Am J Neuroradiol* 2001;22:1346–8.
- [19] Sunderland G, Hassan F, Bhatnagar P, et al. Development of anterior inferior cerebellar artery pseudoaneurysm after gamma knife surgery for vestibular schwannoma. A case report and review of the literature. *Br J Neurosurg* 2014;28:536–8.
- [20] Kellner CP, McDowell MM, Connolly Jr ES, et al. Late onset aneurysm development following radiosurgical obliteration of a cerebellopontine angle meningioma. *BMJ Case Rep* 2014;2014.
- [21] Kellner CP, McDowell MM, Connolly Jr ES, et al. Late onset aneurysm development following radiosurgical obliteration of a cerebellopontine angle meningioma. *J Neurointerv Surg* 2015;7:e21.
- [22] Fujita K, Tamura M, Masuo O, et al. Ruptured internal carotid artery aneurysm presenting with catastrophic epistaxis after repeated stereotactic radiotherapies for anterior skull base tumor: case reports and review of the literature. *J Neurol Surg Rep* 2014;75:e200–5.
- [23] Steiner L, Lindquist C, Cail W, et al. Microsurgery and radiosurgery in brain arteriovenous malformations. *J Neurosurg* 1993;79:647–52.
- [24] Lan Z, Li J, You C, et al. Successful use of Gamma Knife surgery in a distal lenticulostriate artery aneurysm intervention. *Br J Neurosurg* 2012;26:89–90.
- [25] Matsuo T, Kamada K, Izumo T, et al. Linear accelerator-based radiosurgery alone for arteriovenous malformation: more than 12 years of observation. *Int J Radiat Oncol Biol Phys* 2014;89:576–83.