

CASE REPORT

Cerebral venous thrombosis as the first presentation of classical homocystinuria in an adult patient

Emily Woods,¹ Charlotte Dawson,¹ Latha Senthil,² Tarekegn Geberhiwot^{3,4}¹QE Hospital Birmingham, Birmingham, UK²Department of Radiology, University of Birmingham, Birmingham, West Midlands, UK³Department of Endocrinology, University Hospital of Birmingham, Birmingham, UK⁴University of Birmingham, Institute of Metabolism and Systems Research, Birmingham, West Midlands, UK**Correspondence to**Dr Tarekegn Geberhiwot,
Tarekegn.hiwot@uhb.nhs.uk

Accepted 14 January 2017

SUMMARY

A 30-year-old woman presented with severe headache, dysarthria and right hemiparesis. She was treated for suspected viral encephalopathy and recovered over the following weeks although the headaches persisted. Two months later she was treated in-hospital for pulmonary embolism. The following year she was readmitted for increased frequency of headaches and was given a diagnosis of migraine. A subsequent MRI head scan was suggestive of longstanding venous sinus infarcts and neuroradiology review concluded that encephalitis had been the incorrect initial diagnosis. Subsequent investigations for an underlying cause of the two episodes of venous thrombosis revealed a total homocysteine level of $>350 \mu\text{mol/L}$ ($<15 \mu\text{mol/L}$). An underlying diagnosis of homocystinuria secondary to cystathionine β -synthase deficiency was made although this metabolic condition is normally recognised in childhood. Treatment with pyridoxine and betaine normalised her homocysteine levels and she has had no further thrombotic event since.

BACKGROUND

Headache is a relatively common disorder that in the emergency department is seen as a principal symptom in 1–2% of all patients.¹ Commonly these are primary, or benign, headaches which may be tension-type, migraine or cluster headaches. Secondary headaches are far less common and manifest as a result of another underlying pathology. This case demonstrates the importance of considering rarer causes of headache such as sinus venous thrombosis, even in younger patients with no obvious risk factors or comorbidity. A detailed medical history and assessment needs to be taken in order to identify a potentially treatable underlying cause and to aim to prevent subsequent associated life-threatening events.

CASE PRESENTATION

In July 2011, a 30-year-old woman was admitted to hospital with severe headache accompanied by other neurological symptoms including dysarthria, right wrist drop, right facial sensory loss and right hemiparesis. The following day she experienced multiple myoclonic seizures involving the right upper and lower limbs. Consciousness was preserved although the patient did experience some confusion. The patient did not have any history of head injury or nuchal rigidity and there was no family history of cerebrovascular events. The patient had a normal IQ and was otherwise healthy; a non-smoker, occasional drinker, of

normal weight and height. She had no known allergies and was on no medication including contraception. There were no clear risk factors for thrombosis.

During this admission brain MRI (figure 1A), MR venous (MRV) scan (figure 1B) and MR angiogram (MRA) were reported as 'normal' and there was no evidence of papilloedema on funduscopy or other signs of raised intracranial pressure. A lumbar puncture (LP) was performed and cerebrospinal fluid analysis was of normal pressure with no other abnormality except for enterovirus detected on PCR. Owing to the 95% specificity of this result, a diagnosis of viral encephalitis was presumed and she was treated with acyclovir and discharged with long-term sodium valproate and levetiracetam. The patient reported that she recovered over the following weeks although the headaches persevered and were so disabling that she was forced to cancel her wedding.

Two months later she was admitted to hospital with chest pain and breathlessness and CT pulmonary angiography revealed that she had developed pulmonary embolism. The patient was treated with low-molecular-weight heparin (LMWH) and 6 months of warfarin. The patient did notice that her headache had improved while on warfarin.

In October 2012 she presented again with headache. It had once been intermittent but over a few weeks had increased in frequency to a constant severe headache with an accompanying sense of unsteadiness. Similarly, there was no history of head injury or nuchal rigidity. The patient did not have any seizures, visual changes, speech disturbance, sensory loss or weakness. A further LP was reported normal and the patient was diagnosed with migraine. However, on subsequent neuroradiology review of a new MRI head scan it was reported as 'three areas of cortical signal abnormality'; suggestive of cortical vein thrombosis. The patient was restarted on LMWH and warfarin. Her headache greatly improved over a few months although the imbalance persisted and varied daily between no symptoms to needing a wheelchair.

INVESTIGATIONS

Brain MRI (figure 1A), MRA and MRV (figure 1B) were performed in July 2011 and at the time were reported as normal. After further brain MRIs and a MRV in October 2012 the finding of thrombosis initiated a review of the previous images. Re-evaluation of the first MRV from July 2011 (figure 1B) found that there was an apparent lack of filling in the anterior part of the superior sagittal



CrossMark

To cite: Woods E, Dawson C, Senthil L, et al. *BMJ Case Rep* Published online: [please include Day Month Year] doi:10.1136/bcr-2016-217477

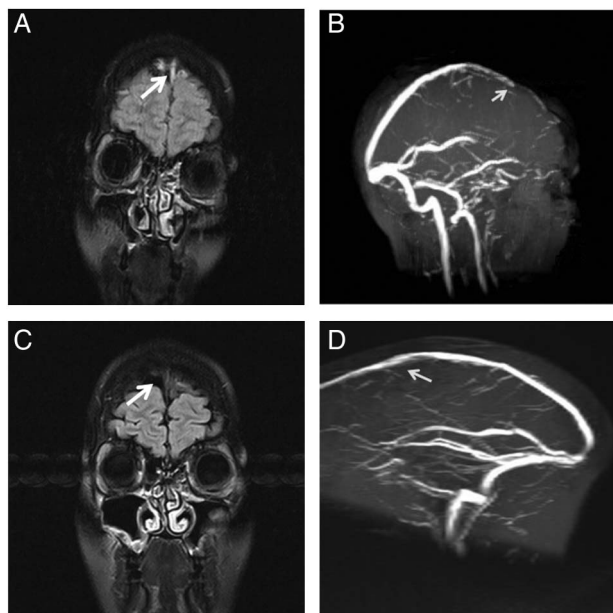


Figure 1 (A) Coronal FLAIR image showing the T2 hyper-intense signal indicative of the clot. (B) Time of Flight venogram (sagittal reformat) showing the filling defect in the anterior half of the superior sagittal sinus. (C) Coronal FLAIR image showing the hypo/isointense signal indicative of flow restoration. (D) Time of Flight venogram (sagittal reformat) showing resolution of the filling defect a year later. FLAIR, fluid-attenuated inversion recovery.

sinus leading to the conclusion that the July 2011 illness was due to cerebral sinus thrombosis rather than enteroviral encephalitis. A subsequent neuroradiology review of the October 2012 MRI (figure 1C, D) concluded that there was no clear sign of any new vessel occlusion and that the small areas of cortical signal change were longstanding and probably represented old venous infarcts dating back to July 2011. Hence, the patient had suffered two episodes of venous thrombosis in 2011 while the nature of the October 2012 symptoms was uncertain.

During the October 2012 admission a thrombophilia screen identified no prothrombotic cause and hence further testing was requested. In the following weeks biochemical testing was carried out and total homocysteine was reported as $>350 \mu\text{mol/L}$ ($<15 \mu\text{mol/L}$). Folate levels were measured and a normal result excluded the possibility of folate deficiency resulting in hyperhomocystinaemia. The methylmalonic acid test was also normal which ruled out the possibility of a cobalamin C defect and indicated that this was an isolated homocystinuria.

A cystathionine β -synthase (CBS) enzyme deficiency results in accumulation of homocysteine and methionine as the enzyme is normally involved in the breakdown of methionine to cysteine.

In all other causes of homocystinuria methionine levels are normal or low. Table 1 below shows the quantitative amino acid and homocysteine levels from this patient over a period of time.

The biochemical analysis combined with imaging and clinical evidence of multiple major thrombotic events led to a diagnosis of underlying classical homocystinuria secondary to cystathionine β -synthase deficiency.

DIFFERENTIAL DIAGNOSIS

One of the most common causes of headache, migraine, is a non-life-threatening differential in this patient. Given the other neurological symptoms, had these been focal and transient, this could have been migraine with aura. However, migraine symptoms are often typical and the clinical diagnosis should be made only in the absence of any pathology on brain imaging. Had this patient been treated for migraine with no further investigation, the outcome could have been critical. Another rare differential diagnosis to consider in this patient is subarachnoid haemorrhage given the patient's age and severe headache. However, several factors made this highly unlikely including the longevity of symptoms, lack of nuchal rigidity, absence of positive cerebrospinal fluid findings and absence of evidence on brain imaging. Another common differential which would, however, be surprising in a younger patient is cerebral arterial stroke. Supporting evidence would have been the headache, neurological deficit and altered mental status in this patient's initial presentation. Ischaemic lesions do not always show on CT head scans early on. However, this young patient did not have any cardiovascular risk factors which deem this an unlikely differential.

TREATMENT

On definitive diagnosis of classic pyridoxine responsive homocystinuria she was started on pyridoxine 100 mg two times a day and cystadane 3 mg two times a day.

OUTCOME AND FOLLOW-UP

Excellent biochemical control was achieved within 5 months of diagnosis as her homocystinuria was sensitive to pyridoxine (see table 1). As a result the patient was able to discontinue what was thought to be life-long anticoagulation a year after her late admission, but continued indefinitely on sodium valproate 500 mg two times a day and has had no further seizures. Follow-up MRI scans were performed in 2013 and 2015 due to occasional headache; both showed no recent change. At her latest follow-up in 2016 she still has had no further thrombotic events.

In light of her new diagnosis and gradually worsening night vision she was found to have bilateral lens dislocation and subsequently underwent lens replacements. She has now regained her optimal eyesight.

Table 1 Plasma homocysteine and methionine

Date	Total homocysteine ($\mu\text{mol/L}$)	Cysteine ($\mu\text{mol/L}$)	Methionine ($\mu\text{mol/L}$)	Mixed disulphide ($\mu\text{mol/L}$)	Free homocysteine ($\mu\text{mol/L}$)
28 January 2013	>350 (normal <15)	<5	31 (normal 10–40)	25	100 (normal undetectable)
25 March 2013	350	<5	20	20	57
17 April 2013	285	13	68	45	50
17 May 2013	141	35	86	30	8
07 June 2013	10	46	37	<10	<5
14 November 2013	12	48	32	<10	<5

The patient has been advised genetic counselling if planning a future pregnancy.

DISCUSSION

Our case highlights the variable presentation of two rare but treatable conditions.

Cerebral sinus thrombosis (CST) symptoms and clinical course are highly variable with severe headache, the most frequent symptom, which is present in more than 90% of adult patients. Other clinical manifestations include hemiparesis, aphasia, seizure, diplopia and coma. Unlike arterial stroke, most often affects young adults and about 75% of the adult patients are women. Underlying cause such as head injury, infection, pregnancy and prothrombotic conditions can be identified in about 85% of patients with sinus thrombosis.² Hyperhomocysteinemia and its severe form, homocystinuria, are treatable recognised causes of large vein thrombosis although CST as the initial clinical presentation is rare.

Homocystinuria is an autosomal recessive inborn error of metabolism primarily caused by CBS deficiency, although there are other rare distinct types.³ The estimated annual incidence is 5 per 1 million population. Individuals with homocystinuria normally develop manifestations in early childhood and so early diagnosis and treatment is often able to prevent further life-threatening complications. The clinical picture can be extremely heterogeneous ranging from patients with a plethora of complications such as lens dislocation, thromboembolic events and marfanoid body habitus to patients with no overt clinical signs. Learning disability is another common feature in homocystinuria and only 30% of patients have an IQ of normal range.⁴ Two phenotypes of CBS deficient homocystinuria are known; B6 responsive or non-responsive.⁵ The main treatment goal is to prevent vascular events by reducing total homocysteine to levels below 60 µmol/L with pyridoxine (if they are responsive), with or without betaine. If untreated there is a 50% chance of a thrombotic event before the age of 30 years.⁶ The mechanism of thrombosis and atherosclerosis in homocysteinemia is largely unknown but endothelial injury and stimulation of platelet aggregation has been postulated.⁷

Learning points

- ▶ Cerebral sinus thrombosis poses a diagnostic challenge because it is a rare condition with variable signs and symptoms that is often unrecognised at initial presentation.
- ▶ Cerebral sinus thrombosis should be considered as a differential diagnosis in patients with severe headache, particularly in the context of concomitant neurological signs.
- ▶ Rare inherited metabolic disorders, such as homocystinuria, can present atypically in adulthood without cardinal features so clinicians should maintain an index of suspicion.
- ▶ Homocysteine levels should be measured in patients presenting with recurrent thrombotic events, alongside the standard aetiological work-up.

Contributors EW and TG wrote the manuscript. All authors reviewed the draft and approved the final version. TG and CD cared for the patient.

Competing interests None declared.

Patient consent Obtained.

Provenance and peer review Not commissioned; externally peer reviewed.

REFERENCES

- 1 Ward TN, Levin M, Phillips JM. Evaluation and management of headache in the emergency department. *Med Clin North Am* 2001;85:971–96.
- 2 Stam J. Thrombosis of the cerebral veins and sinuses. *N Engl J Med* 2005;352:1791–179.
- 3 Finkelstein JD. Inborn errors of sulfur-containing amino acid metabolism. *J Nutr* 2006;136:1750S–4S.
- 4 Gomber S, Dewan P, Dua T. Homocystinuria: a rare cause of megaloblastic anemia. *Indian Pediatr* 2004;41:941–3.
- 5 Picker JD, Levy HL. Homocystinuria caused by cystathionine beta-synthase deficiency. Pagon RA, Adam MP, Ardinger HH, et al; Seattle: University of Washington, 2004. <http://www.ncbi.nlm.nih.gov/books/NBK1524/#> (accessed 28 Jul 2016).
- 6 Mudd SH, Skovby F, Levy HL, et al. The natural history of homocystinuria due to cystathionine beta-synthase deficiency. *Am J Hum Genet* 1985;37:1–31.
- 7 Hajjar KA. Homocysteine: a sulph'rous fire. *J Clin Invest* 2001;107:663–4.

Copyright 2017 BMJ Publishing Group. All rights reserved. For permission to reuse any of this content visit <http://group.bmj.com/group/rights-licensing/permissions>.
BMJ Case Report Fellows may re-use this article for personal use and teaching without any further permission.

Become a Fellow of BMJ Case Reports today and you can:

- ▶ Submit as many cases as you like
- ▶ Enjoy fast sympathetic peer review and rapid publication of accepted articles
- ▶ Access all the published articles
- ▶ Re-use any of the published material for personal use and teaching without further permission

For information on Institutional Fellowships contact consortiasales@bmjgroup.com

Visit casereports.bmj.com for more articles like this and to become a Fellow