

Bilateral Internal Carotid Artery Aneurysms at the Subpetrosal Portion with Unilateral Lower Cranial Nerve Palsies: Review and Consideration of Surgical Strategy

Kei Noguchi, MD, Takachika Aoki, MD, Rokudai Sakamoto, MD, Kimihiko Orito, MD, Yasuharu Takeuchi, MD, Masaru Hirohata, MD, and Motohiro Morioka, MD

Background: Symptomatic bilateral extracranial internal carotid artery (ICA) aneurysms at the subpetrosal portion are extremely rare, and their treatment strategy remains unknown. **Clinical Presentation:** A 42-year-old man presented to our hospital with a 2-month history of sudden onset of hoarseness, dysarthria, and dysphagia. Magnetic resonance imaging, magnetic resonance angiography, and computed tomography angiography revealed extracranial bilateral ICA aneurysms at the subpetrosal portion. The left-sided aneurysm compressed the left-sided lower cranial nerves (IX, X, XI, and XII), whereas the right-sided aneurysm was asymptomatic. We prioritized the treatment of the right-sided aneurysm to prevent bilateral lower cranial nerve deficits. This strategy was used because aneurysm treatment is not guaranteed to cure the left-sided cranial nerve palsies that lasted for 2 months. The right-sided ICA aneurysm was treated with ICA ligation and high-flow extracranial–intracranial bypass using the radial artery as bypass graft. Stent-assisted coil embolization was performed to the left-sided ICA aneurysm after 17 days. The patient showed no right-sided symptoms, and his left-sided symptoms remarkably improved 1 year after surgery. **Conclusion:** Our unique surgical strategy of prioritizing the aneurysm on the “asymptomatic” side may be one of the best treatment approaches in an extremely rare bilateral aneurysm case. **Key Words:** Bilateral extracranial internal carotid artery aneurysms—EC–IC bypass—lower cranial nerve deficit—subpetrosal portion—symptomatic.

© 2017 National Stroke Association. Published by Elsevier Inc. All rights reserved.

From the Department of Neurosurgery, Kurume University School of Medicine, Fukuoka, Japan.

Received November 2, 2016; revision received November 30, 2016; accepted December 28, 2016.

Grant support: This work was supported by Grants-in-Aid for Scientific Research from the Ministry of Education, Sports, Science and Culture of Japan.

Address correspondence to Kei Noguchi, MD, Department of Neurosurgery, Kurume University School of Medicine, 67, Asahimachi Kurume City, Fukuoka 830-0011, Japan. E-mail: noguchi_kei@med.kurume-u.ac.jp.

1052-3057/\$ - see front matter

© 2017 National Stroke Association. Published by Elsevier Inc. All rights reserved.

<http://dx.doi.org/10.1016/j.jstrokecerebrovasdis.2016.12.033>

Introduction

Extracranial internal carotid artery (ICA) aneurysms are rare and account for .1%-4% of all arterial aneurysms.¹⁻³ These aneurysms generally exist at the ICA bifurcation or the proximal side of ICA.^{4,5} Extracranial distal ICA aneurysms are mostly related to carotid artery dissection,⁶⁻⁸ and their main symptom is associated with cerebral ischemia caused by embolism from dissecting aneurysm.^{9,10} In this paper, we report an extremely rare case of spontaneous bilateral extracranial ICA aneurysms at the subpetrosal portion, of which the aneurysm on one side caused ipsilateral lower cranial nerve palsies. We used

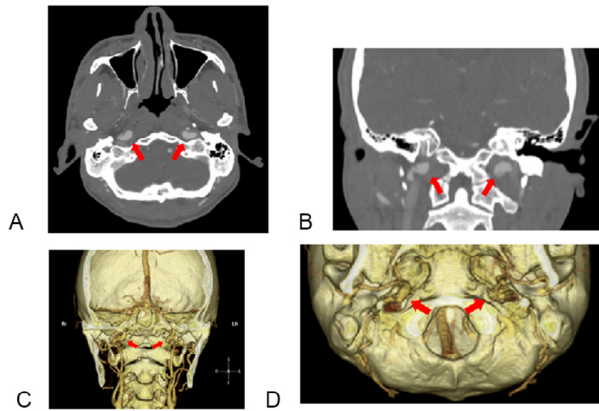


Figure 1. Computed tomography angiography (A: axial image; B: coronal image) and 3-dimensional computed tomography angiography (C and D). The arrows indicate bilateral internal carotid artery aneurysms at the subpetrosal portion. These aneurysms are located just under the jugular foramen.

a unique treatment strategy including surgical and endovascular interventions.

Clinical Presentation

A 42-year-old man had been experiencing hoarseness, dysphagia, and dysarthria for 2 months. He had no remarkable history or familial history and no abnormality on laboratory examinations. Neurologic examination

revealed weak swallowing reflex, dropping of the palatine arch on the left side, and left-sided weakness of the sternocleidomastoid muscle and tongue. Laryngoscopic examination demonstrated left-sided vocal cord paralysis. Video fluoroscopic examination of swallowing showed stagnation of foods at the laryngeal vestibule. Based on the above findings, we diagnosed the patient with left-sided lower cranial nerve (IX, X, XI, and XII) palsies. Other cranial nerves on the left side and all cranial nerves on the right side were normal. Magnetic resonance imaging (MRI) demonstrated that no intracranial abnormality caused the lower cranial nerve palsies. Computed tomography angiography (CTA) and magnetic resonance angiography (MRA) revealed bilateral ICA aneurysms at the subpetrosal portion. These aneurysms were located just under the jugular foramen (Fig 1). Constructive interference in steady-state MRI revealed that both aneurysms exist close to the lower cranial nerves and appear to compress these nerves (Fig 2), whereas right-sided aneurysm did not show any symptoms. Digital subtraction angiography (DSA) confirmed the presence of bilateral ICA aneurysms at the subpetrosal portion, which were 14.3 mm in diameter on the left side and 8 mm in diameter on the right side (Fig 3, A-D). Although these aneurysms mildly compressed the bilateral internal jugular vein, venous return and collateral route for venous return were sufficient. There was no evidence of bilateral venous congestion on DSA and MRI. Based on these findings, the

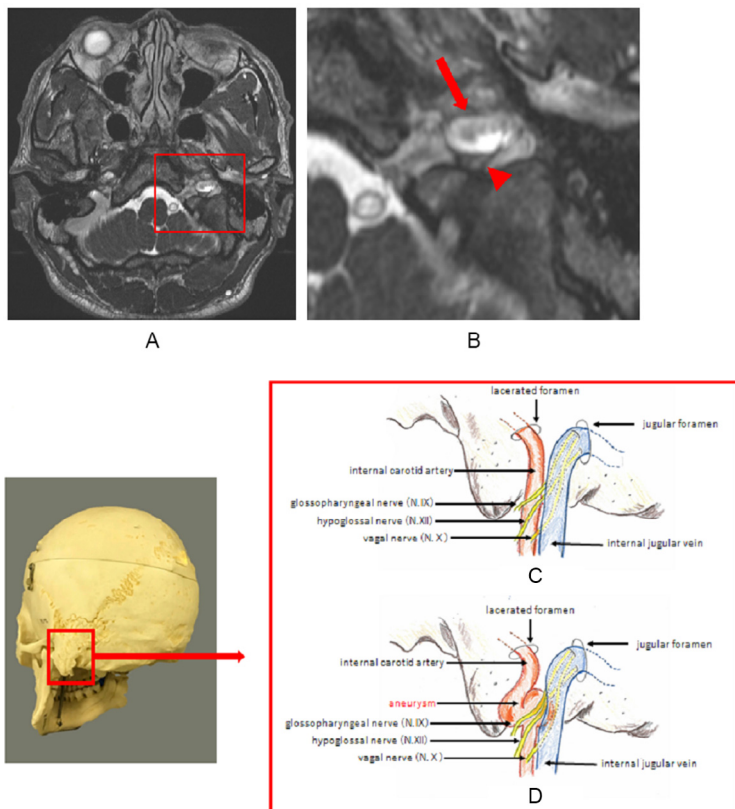


Figure 2. Constructive interference in steady-state magnetic resonance imaging reveals left-sided aneurysmal compression of the lower cranial nerves (A). The arrowhead (B) indicates left-sided lower cranial nerves, and the arrow (B) indicates left-sided ICA aneurysm at the subpetrosal portion. Subpanel (C) shows the neighboring structures, which include the left lower cranial nerves, jugular foramen, jugular vein, lacerated foramen, and ICA information. Subpanel (D) shows an aneurysm and its neighboring structures, which include compressed lower cranial nerves. Abbreviation: ICA, internal carotid artery.

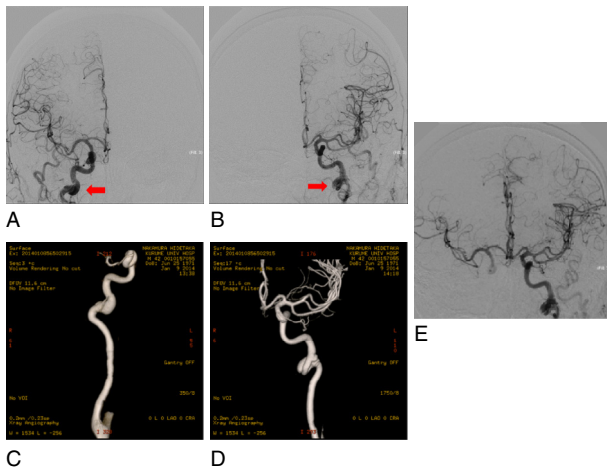


Figure 3. Digital subtraction angiography confirms the presence of bilateral ICA aneurysms at the subpetrosal portion. Right-sided ICA aneurysm (A: AP view; C: 3D image) and left-sided ICA aneurysm (B: AP view; D: 3D image). The arrows (A and B) indicate aneurysms. Balloon test occlusion on the right ICA shows a good cross flow through the anterior communicating artery (E). Abbreviation: ICA, internal carotid artery.

symptoms were due to the compression of the left-sided aneurysm to the lower cranial nerves at the subpetrosal portion, but the right-sided aneurysm was asymptomatic.

Considering the therapeutic strategy, we understand that the first target is symptomatic aneurysm. However, the following issues exist. First, aneurysm treatment on the ipsilateral side is not guaranteed to cure the left-sided cranial nerve palsies that have lasted for 2 months. Second, if the right-sided aneurysm grows and becomes symptomatic, then a risk of serious bilateral lower cranial nerve paralysis exists. The manifestation is severe dysphonia, dyspnea, and stridor; it can be fatal if the airway is not secured. Third, prioritizing the treatment of left-sided aneurysm is expected to change the wall shear stress of the right-sided aneurysm. This change may promote aneurysm growth on the right side, and right-sided symptoms may be attributed to this growth.

Therefore, we prioritized the radical treatment of asymptomatic right-sided aneurysm to preserve completely the asymptomatic lower cranial nerves after sufficient informed consent. Balloon test occlusion on the right ICA showed a good cross flow from the anterior and posterior communicating arteries (Fig 3, E). The patient did not manifest ischemic symptoms and had mean stump pressures of more than 60% compared with the mean systemic pressure during balloon test occlusion. In addition, a remarkable change in latency and amplitude was not observed in sensory-evoked potential monitoring. Although these results indicate favorable ischemic tolerance, ligation without high-flow bypass may result in increasing wall shear stress of the left-sided aneurysm.

ICA ligation with high-flow extracranial–intracranial bypass (EC–IC bypass) using the radial artery as bypass graft, fol-

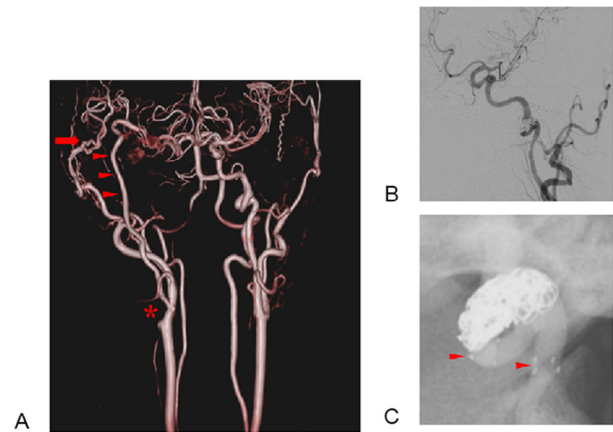


Figure 4. ICA ligation (asterisk) with high-flow extracranial–intracranial bypass using the radial artery as bypass graft (arrowhead) and superficial temporal artery–middle cerebral artery M4 bypass (arrow) (A). Digital subtraction angiography of post stent-assisted coil embolization for left ICA aneurysm (B). Proximal and distal ends of the stent are indicated by an arrowhead (C). Abbreviation: ICA, internal carotid artery.

lowed by superficial temporal artery–middle cerebral artery M4 bypass (STA–MCA assist bypass), was first performed for the right-sided aneurysm (Fig 4, A). Postoperative MRI revealed a small infarction at the right cortex of the temporal lobe but no neurologic deterioration. MRA showed thrombosed right ICA aneurysm and good flow without constriction of the EC–IC bypass. We initially planned the same treatment (ICA ligation and high-flow EC–IC bypass) for the left side within several weeks. However, single-photon emission computed tomography showed a slight decline in the cerebral blood flow at the right hemisphere. Sixteen days after the right side surgery, we performed stent-assisted coil embolization for the symptomatic left-sided aneurysm to prevent the decrease in cerebral blood flow on the left side (Fig 4, B,C). The postoperative course was uneventful. The lower cranial nerve deficits on the left side gradually reduced and almost disappeared in 10 months. If the left-sided aneurysm shows lower cranial nerve disturbance again in the future, then bilateral lower cranial nerve palsies will not exist and can be treated with additional strategy, IC ligation, and EC–IC bypass.

Discussion

Here, we report a spontaneous bilateral extracranial ICA aneurysm at the subpetrosal portion, of which the aneurysm on one side caused ipsilateral lower cranial nerve palsies. A surgical intervention for such extremely rare case is reported in this study for the first time.

Extracranial ICA aneurysms are rare. The risk factors and causes of these aneurysms are genetic and environmental, including atherosclerosis,⁵ traumatic events,¹¹ migraine,¹² recent infection,¹³ vasculitis,¹⁴ hyperhomocysteinemia,¹⁵ and hereditary dermatologic or connective tissue disorder (e.g., Ehlers–Danlos

syndrome, Marfan syndrome, neurofibromatosis type 1, and fibromuscular dysplasia).^{14,16,17} However, the past history, clinical findings, and results of blood biochemistry, immunologic inspections, and images including whole-body CT/CTA in this case did not present the abovementioned factors and causes. Extracranial carotid artery dissecting aneurysm is also a well-known cause of this condition.¹⁸⁻²⁰ In this case, the intimal flaps and the tapered pseudolumens, which are characteristics of dissecting aneurysms, were not found through thin-slice CTA, high-resolution MRI, MRA, and DSA. The patient also had no history of headache suggestive of ICA dissections. These aneurysms were not dissecting aneurysms. Although .5% of ICA dissection cases only present cranial nerve palsy without headache,²¹⁻²³ most of these cases have aneurysms at the cavernous portion. Therefore, we diagnosed this case as spontaneous bilateral extracranial ICA aneurysms at the subpetrosal portion, and 1 aneurysm caused ipsilateral lower cranial nerve palsies.

Some treatment options for symptomatic bilateral ICA aneurysms existed. However, there are some issues including the side to be treated first and the best treatment approach to use. Generally, we precede the treatment for the symptomatic side, but left-sided cranial nerve palsies that lasted for 2 months are not guaranteed to be cured in this case. Previous studies did not statistically report the relationship between disease duration and the cure rate of lower cranial nerve palsy. There were apprehensions that the asymptomatic side aneurysm may grow and become symptomatic, falling into bilateral vocal fold paralysis, which causes fatal airway obstruction.²⁴⁻²⁷ Thus, we precede the treatment for the asymptomatic side aneurysm. ICA ligation with high-flow EC-IC bypass using the radial artery as bypass graft and STA-MCA assist bypass was performed. It was the best radical treatment to prevent right-sided aneurysm to become symptomatic and avoid considerable changes in the wall shear stress of the left-sided aneurysm. Changing the wall shear stress may promote aneurysm growth.²⁸⁻³² Uozumi et al³³ reported 6 cases of bilateral giant intracavernous ICA aneurysm. Similar to our case, one side was symptomatic and the other side was asymptomatic. High-flow EC-IC bypass was performed in all but one case. However, the asymptomatic side aneurysm became enlarged in 5 of the 6 cases and the symptomatic side became enlarged in 4 of the 5 cases after the first treatment (mean follow-up period was 61.3 months). Fujimura et al²⁰ also reported a case of bilateral giant intracavernous ICA aneurysm. They observed that the asymptomatic side aneurysm became symptomatic 10 months after the treatment (parent artery occlusion and high-flow bypass). Alternatively, direct surgery for extracranial distal ICA aneurysms can frequently cause permanent cranial nerve injury.³⁴ We confirmed that our surgical strategy is a good choice.

We describe a case of bilateral extracranial ICA aneurysms at the subpetrosal portion with unilateral lower cranial nerve palsies. This condition has no established treatment method because of its extremely rare occurrence. We prioritized aneurysm treatment on the unaffected side and obtained a good result. This treatment strategy is recommended as the treatment of choice.

Conclusion

Symptomatic bilateral extracranial ICA aneurysms at the subpetrosal portion are extremely rare, and their treatment strategy remains unknown. In this case report, we demonstrate a unique surgical approach that prioritizes the aneurysm on the "asymptomatic" side. This strategy may be one of the best treatment approaches for this condition.

Acknowledgments: We thank Ms. Junko Miyoshi and Ms. Keiko Suematsu for their technical assistance. We would also like to thank Editage (www.editage.jp) for English language editing.

References

1. Beall AC Jr, Crawford ES, Cooley DA, et al. Extracranial aneurysms of the carotid artery. Report of seven cases. *Postgrad Med* 1962;32:93-102.
2. Schechter DC. Cervical carotid aneurysms: part I. *NY State J Med* 1979;79:892-901.
3. Hanakita J, Suwa H, Nishi S, et al. Bilateral aneurysms of extracranial internal carotid arteries. Case report. *Neurol Med Chir (Tokyo)* 1991;31:972-977.
4. El-Sabroun R, Cooley DA. Extracranial carotid artery aneurysms: Texas Heart Institute experience. *J Vasc Surg* 2000;31:702-712.
5. Reslan OM, Ebaugh JL, Raffetto JD. Bilateral asymptomatic extracranial carotid artery aneurysms. *Ann Vasc Surg* 2010;24:691.e11-691.e16.
6. Spitzer C, Mull M, Töpper R. Isolated hypoglossal nerve palsy caused by carotid artery dissection the necessity of MRI for diagnosis. *J Neurol* 2001;28:909-910.
7. Guidetti D, Pisanello A, Giovanardi F, et al. Spontaneous carotid dissection presenting lower cranial nerve palsies. *J Neurol Sci* 2001;184:203-207.
8. Guy N, Deffond D, Gabrillargues J, et al. Spontaneous internal carotid artery dissection with lower cranial nerve palsy. *Can J Neurol Sci* 2001;28:265-269.
9. Rhodes EL, Stanley JC, Hoffman GL, et al. Aneurysms of extracranial carotid arteries. *Arch Surg* 1976;111:339-343.
10. Busuttill RW, Davidson RK, Foley KT, et al. Selective management of extracranial carotid arterial aneurysms. *Am J Surg* 1980;140:85-91.
11. Foreman PM, Griessenauer CJ, Falola M, et al. Extracranial traumatic aneurysms due to blunt cerebrovascular injury. *J Neurosurg* 2014;120:1437-1445.
12. D'Anglejan-Chatillon J, Ribeiro V, Mas JL, et al. Migraine—a risk factor for dissection of cervical arteries. *Headache* 1989;29:560-561.
13. Grau AJ, Brandt T, Buggle F, et al. Association of cervical artery dissection with recent infection. *Arch Neurol* 1999;56:851-856.

14. Wessels T, Sparing R, Neuschaefer-Rube C, et al. Vocal cord palsy resulting from spontaneous carotid dissection. *Laryngoscope* 2003;113:537-540.
15. Gallai V, Caso V, Paciaroni M, et al. Mild hyperhomocyst(e)inemia: a possible risk factor for cervical artery dissection. *Stroke* 2001;32:714-718.
16. Ma Y, Li M, Zhang H, et al. A 10-year follow-up of extracranial-intracranial bypass for the treatment of bilateral giant internal carotid artery aneurysms in a patient with fibromuscular dysplasia: case report. *Acta Neurochir (Wien)* 2010;152:2191-2195.
17. Ku YK, Chen HW, Chen HW, et al. Giant extracranial aneurysms of both internal carotid arteries with aberrant jugular veins in a patient with neurofibromatosis type 1. *AJNR Am J Neuroradiol* 2008;29:1750-1752.
18. Isildak H, Karaman E, Ozdogan A, et al. Unusual manifestations of bilateral carotid artery dissection: dysphagia and hoarseness. *Dysphagia* 2010;25:338-340.
19. Waespe W, Niesper J, Imhof HG, et al. Lower cranial nerve palsies due to internal carotid dissection. *Stroke* 1988;19:1561-1564.
20. Fujimura M, Sato K, Kimura N, et al. A case of bilateral giant internal carotid artery aneurysms at the cavernous portion managed by 2-stage extracranial-intracranial bypass with parent artery occlusion: consideration for bypass selection and timing of surgeries. *J Stroke Cerebrovasc* 2014;23:e393-e398.
21. Leys D, Lucas C, Gobert M, et al. Cervical artery dissections. *Eur Neurol* 1997;37:3-12.
22. Mokri B, Silbert PL, Schievink WI, et al. Cranial nerve palsy in spontaneous dissection of the extracranial internal carotid artery. *Neurology* 1996;46:356-359.
23. Sturzenegger M. Spontaneous internal carotid artery dissection: early diagnosis and management in 44 patients. *J Neurol* 1995;242:231-238.
24. Martínez-Oropeza Ldel C, González-Ojeda A, Góvea-Camacho LH, et al. Management of bilateral vocal cord paralysis with laser cordectomy. *Rev Med Inst Mex Seguro Soc* 2014;52:162-167.
25. Li Y, Pearce EC, Mainthia R, et al. Comparison of ventilation and voice outcomes between unilateral laryngeal pacing and unilateral cordotomy for the treatment of bilateral vocal fold paralysis. *ORL J Otorhinolaryngol Relat Spec* 2013;75:68-73.
26. Holinger LD, Holinger PC, Holinger PH. Etiology of bilateral abductor vocal cord paralysis: a review of 389 cases. *Ann Otol Rhinol Laryngol* 1976;85(4 Pt 1):428-436.
27. Sapundzhiev N, Lichtenberger G, Eckel HE, et al. Surgery of adult bilateral vocal fold paralysis in adduction: history and trends. *Eur Arch Otorhinolaryngol* 2008;265:1501-1514.
28. Nakatani H, Hashimoto N, Kang Y, et al. Cerebral blood flow patterns at major vessel bifurcations and aneurysms in rats. *J Neurosurg* 1991;74:258-262.
29. Gonzalez CF, Cho YI, Ortega HV, et al. Intracranial aneurysms: flow analysis of their origin and progression. *AJNR Am J Neuroradiol* 1992;13:181-188.
30. Gobin YP, Counord JL, Flaud P, et al. In vitro study of haemodynamics in a giant saccular aneurysm model: influence of flow dynamics in the parent vessel and effects of coil embolisation. *Neuroradiology* 1994;36:530-536.
31. Satoh T, Onoda K, Tsuchimoto S. Visualization of intraaneurysmal flow patterns with transluminal flow images of 3D MR angiograms in conjunction with aneurysmal configurations. *AJNR Am J Neuroradiol* 2003;24:1436-1445.
32. Meng H, Tutino VM, Xiang J, et al. High WSS or low WSS? Complex interactions of hemodynamics with intracranial aneurysm initiation, growth, and rupture: toward a unifying hypothesis. *AJNR Am J Neuroradiol* 2014;35:1254-1262.
33. Uozumi Y, Okamoto S, Araki Y, et al. Treatment of symptomatic bilateral cavernous carotid aneurysms: long-term results of 6 cases. *J Stroke Cerebrovasc* 2015;24:1013-1018.
34. Welleweerd JC, den Ruijter HM, Nelissen BG, et al. Management of extracranial carotid artery aneurysm. *Eur J Vasc Endovasc Surg* 2015;50:141-147.