

# Delayed Intraparenchymal and Intraventricular Hemorrhage Requiring Surgical Evacuation after MRI-Guided Laser Interstitial Thermal Therapy for Lesional Epilepsy

Sean M. Barber<sup>a</sup> Luke Tomycz<sup>b</sup> Timothy George<sup>b</sup> Dave F. Clarke<sup>c</sup> Mark Lee<sup>b</sup>

<sup>a</sup>Department of Neurosurgery, Houston Methodist Neurological Institute, Houston, TX, and <sup>b</sup>Department of Neurosurgery, Seton Brain and Spine Institute, and <sup>c</sup>Division of Neurology, Department of Pediatrics, Comprehensive Epilepsy Program, Dell Children's Medical Center of Central Texas, Austin, TX, USA

## Keywords

Epilepsy · Intracranial hemorrhage · Laser ablation · Pseudoaneurysm · Stereotactic techniques

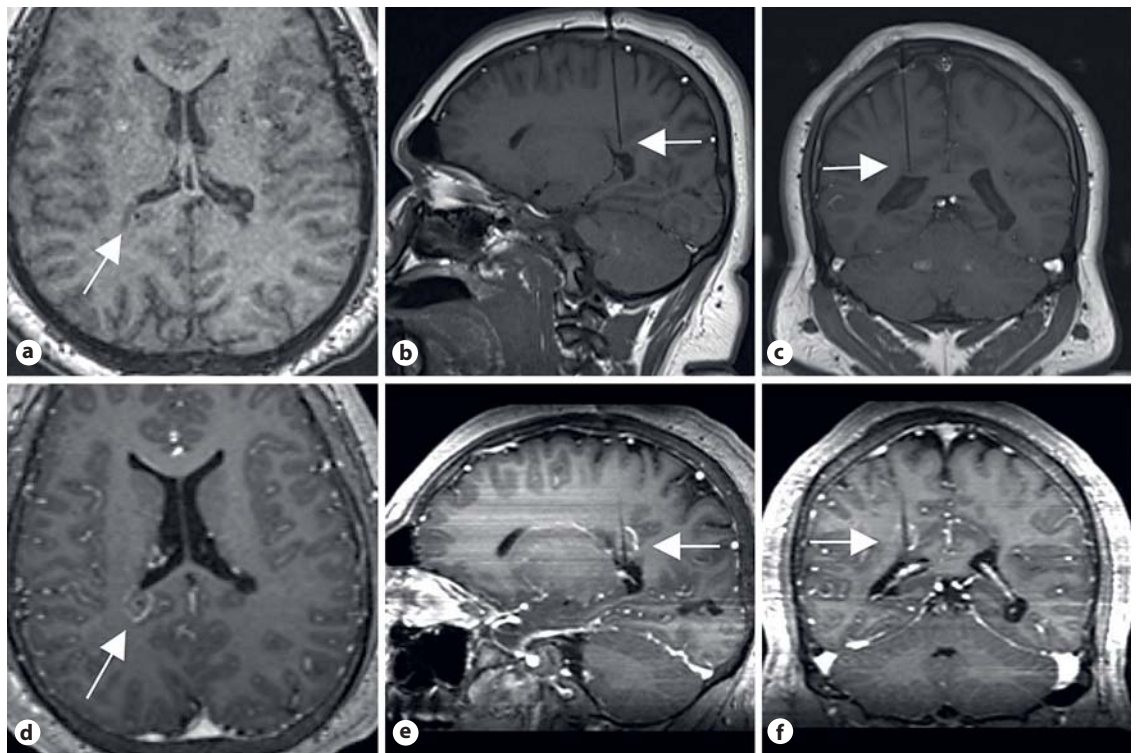
## Abstract

**Background:** Symptomatic intracranial hemorrhage is a rare complication of laser interstitial thermal therapy (LITT). **Objectives:** To present a unique case of delayed symptomatic intracranial hemorrhage occurring after a LITT procedure for epilepsy in a high-volume center (68 LITT procedures for pediatric epilepsy have been performed). **Methods:** An 18-year-old male with epilepsy underwent LITT to an area of heterotopia near the right lateral ventricle. He did well initially and was discharged home on postoperative day 1 but returned on postoperative day 9 with headache and left hemiparesis. He was found to have intraparenchymal and intraventricular hemorrhage in the region of the LITT catheter tract. **Results:** CT angiography on admission revealed a small vascular abnormality near the focus of hemorrhage suspicious for pseudoaneurysm, although conventional angiography was negative. The patient declined neurological and underwent craniotomy and hemorrhage evacuation. He eventually convalesced and was discharged to inpatient rehabilitation with persistent left hemiparesis. He has been

seizure free since the intervention but remains on antiepileptic drugs. **Conclusions:** Evidence from the literature suggests that the pathophysiology of symptomatic hemorrhage after LITT may be related to vascular injury and pseudoaneurysm formation from LITT catheter placement and/or thermal injury from the ablation itself. © 2017 S. Karger AG, Basel

## Introduction

MRI-guided laser interstitial thermal therapy (LITT) is a stereotactic, minimally invasive method of inducing selective thermal injury to pathological lesions in the brain. Although stereotactic laser thermal ablation has been described as early as 1983 [1], recent technological advances in MRI guidance and real-time monitoring of local tissue injury have galvanized interest in the technique as a treatment for tumors and epileptogenic foci in particular [2–4]. While early reports of LITT safety and efficacy have been favorable [3, 5–8], a variety of unexpected adverse events related to LITT have also been reported, including intracranial hemorrhage [2–4, 8, 9], cerebral edema [9], and fracture of the intracranial bolt/catheter [10].



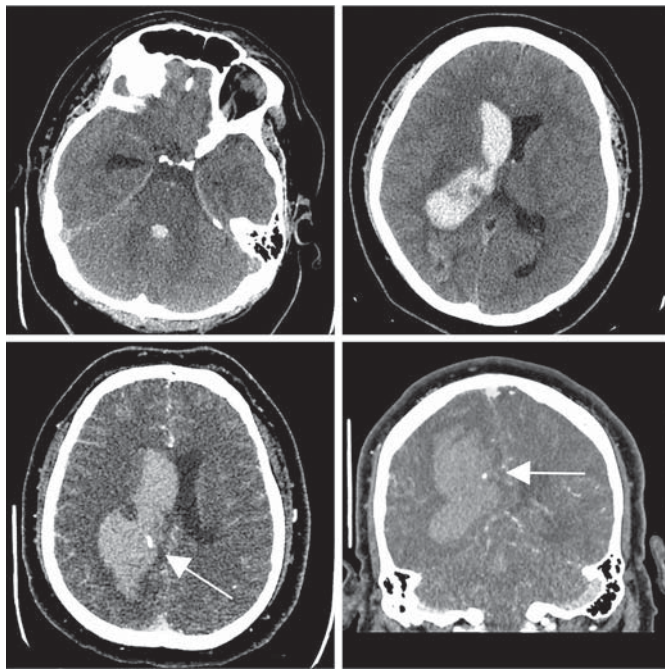
**Fig. 1.** MRI T1 images after contrast enhancement. Axial (a), sagittal (b), and coronal (c) images taken after stereotactic placement of a laser fiber catheter within a small focus of heterotopia near the posterior aspect of the right lateral ventricle demonstrate the location of the catheter tip (white arrows). d–f Corresponding images taken after laser interstitial thermal therapy was complete revealing wispy enhancement around the lesioned focus (white arrows).

According to these initial reports, clinically relevant intracranial hemorrhage after LITT is a rare – although occasionally catastrophic – complication [2, 8], typically discovered as a result of clinical deterioration soon after the ablative procedure and often attributed to bur hole creation and catheter placement rather than to thermal injury from the ablation itself [9, 10]. Interestingly, all moderate to severe intraparenchymal hemorrhages currently reported after LITT have occurred in patients undergoing ablation for tumors; only 1 of these cases was treated with surgical evacuation and/or exploration [11], and in only 1 case did the hemorrhage arise more than 1 week after treatment [4].

We report a case of intraparenchymal and intraventricular hemorrhage occurring 9 days after an LITT procedure for periventricular heterotopia in a patient with intractable epilepsy. The patient underwent craniotomy for hemorrhage evacuation and exploration, but no source of the hemorrhage was ultimately discovered.

### Case Description

An 18-year-old male with no significant medical history other than partial complex seizures since the age of 13 presented to our clinic as a referral for possible vagal nerve stimulator placement. Despite adequate treatment trials with 3 antiepileptic medications, he continued to have seizures every other day. He underwent an MRI of the brain at age 18 and was found to have multiple foci of nodular heterotopia and linear cortical dysplasia abutting the lateral ventricles bilaterally. He underwent phase 2 evaluation consisting of stereotactic placement of 4 depth electrodes in bilateral occipitotemporal areas of heterotopia as well as bifrontal areas of heterotopia abutting the frontal horns of the lateral ventricles. All but the right frontal heterotopic foci were found to exhibit epileptogenic activity associated with electrographic and clinical seizures. The patient was thus considered to be a candidate for LITT (68 LITT procedures have been performed by the authors for pediatric epilepsy at the time of this publication) – a more definitive treatment option than vagal nerve stimulator placement. He underwent LITT to the 3 epileptogenic foci at that time with 3 Visualase (Medtronic, Minneapolis, MN, USA) catheters. Postoperatively, he experienced moderate visual apraxia that largely resolved over the following 6 months. He was discharged to home on postoperative day 3 after the ablative procedure. Although he experi-



**Fig. 2.** CT brain images without contrast (top) obtained when the patient presented 9 days later with hemiparesis and headache. Intraparenchymal hemorrhage is seen within the tract and around the tip of the laser fiber catheter through which laser interstitial thermal therapy took place. Also seen is diffuse intraventricular hemorrhage and hydrocephalus. CT-angiography images (bottom) reveal a possible pseudoaneurysm in the vicinity of the hemorrhage (white arrows).

enced 2 clinical seizures in the immediate postoperative period, no further clinical seizure activity was witnessed until 17 months later, when he began to have occasional breakthrough seizures despite continuous therapy with 2 antiepileptic drugs.

The patient presented to our clinic 21 months after the initial ablation complaining of persistent breakthrough seizures and the need for ongoing use of antiepileptic drugs, together preventing him from pursuing academic and work-related interests to his full capacity. An MRI of the brain at that time revealed a previously untreated area of heterotopia abutting the posterior aspect of the right lateral ventricle. After discussing the risks and benefits of intervention, the patient elected to undergo LITT to the previously untreated area of heterotopia abutting the posterior right lateral ventricle. A single Visualase (Medtronic) catheter was placed here using a rigid, stereotactic frame (Fig. 1a–c). Intraoperative MRI at the time revealed only postablation changes without evidence of significant hemorrhage (Fig. 1d–f). Postoperatively, the patient did well and was discharged home in good condition on postoperative day 1.

On postoperative day 9 the patient presented to an outside facility with acute-onset left hemiparesis, generalized tonic-clonic seizure activity, and severe headache. A CT of the brain at that time revealed intraparenchymal hemorrhage along the right parietal catheter tract as well as hemorrhage within the lateral, third, and fourth ventricles (Fig. 2). CT angiography at the time revealed an

abnormal dilation of a vessel within the right lateral periventricular area that was felt by the reading radiologist to be consistent with a pseudoaneurysm of a right posterior cerebral artery branch. An external ventricular drain was placed, and the patient underwent conventional 4-vessel angiography, which was negative for pseudoaneurysm or other vascular abnormality.

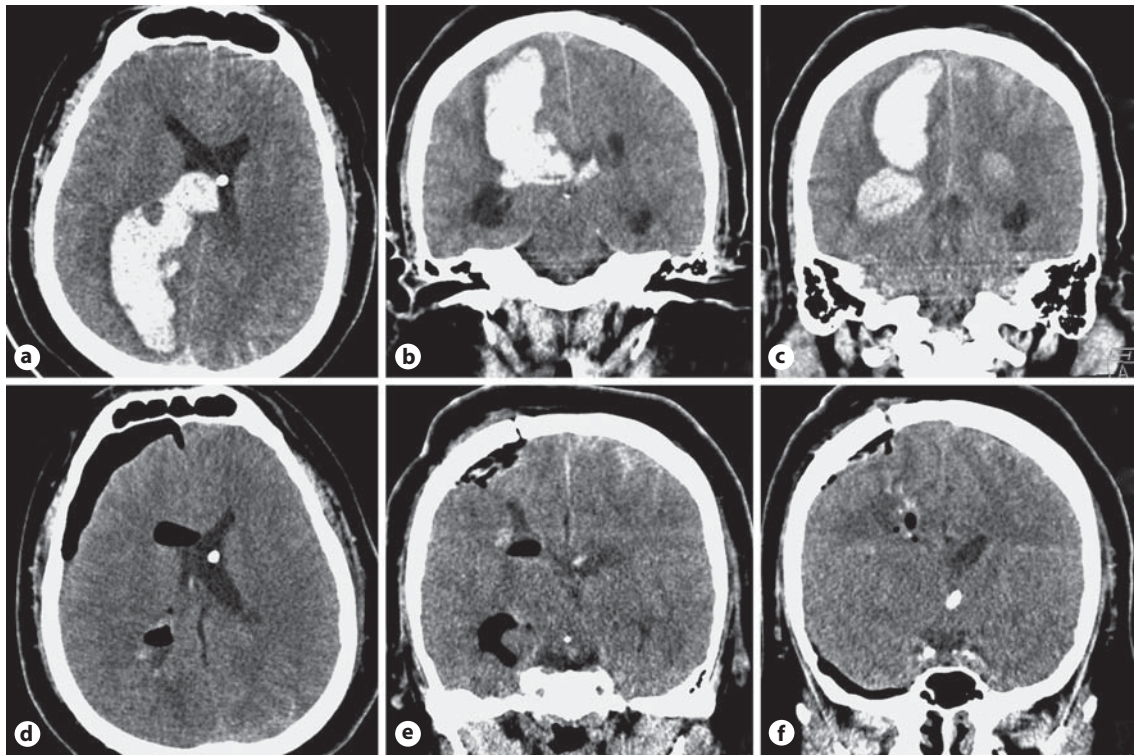
The patient remained clinically stable for 2 days, but he became acutely unresponsive on hospital day 2, and intracranial pressure values became elevated up to 50 mm Hg. A repeat CT brain was performed, revealing worsening of the previously seen intraparenchymal and intraventricular hemorrhage as well as trapping of the right lateral ventricle (Fig. 3a–c). He was taken emergently to the operating room where a right parietal craniotomy was performed. A firm, organized intraparenchymal hematoma was encountered tracking down into the right lateral ventricle. After this was evacuated, the area was explored thoroughly. Several small vessels coursing along the choroid plexus within the right lateral ventricle appeared to be bleeding slightly. These were coagulated, but no further vascular source for the patient's hemorrhage could be identified.

The patient returned to the intensive care unit where he was monitored for several days without further hemorrhage. An attempt was made to wean the external ventricular drain on postoperative days 3 and 4 from the craniotomy, but the patient did not tolerate weaning. An attempt was then made to perform an endoscopic third ventriculostomy on postoperative day 4, but visibility was limited due to persistent intraventricular blood, and thus the procedure was aborted. A second attempt was made to wean the external ventricular drain, but the patient did not tolerate the weaning clinically, and a ventriculoperitoneal shunt was instead placed on postoperative day 16 from the craniotomy. The patient remained stable over the course of the following week and was then discharged to inpatient rehabilitation for his persistent left hemiparesis. He has been seizure free since the intervention but remains on antiepileptics at the most recent follow-up.

## Discussion

Though the incidence of symptomatic hemorrhage after stereotactic intracranial procedures is reportedly low (1.2–7.2%) [11–21], the potential morbidity and mortality associated with intracranial hemorrhage after LITT are illustrated in this case. Patients undergoing LITT must be counseled accordingly.

Although a small amount of asymptomatic hemorrhage may be expected in a majority of patients after stereotactic neurosurgical procedures [21], the mechanism underlying the development of clinically relevant intracranial hemorrhage after catheter placement, electrode placement, or stereotactic biopsy is not well understood. The placement of a catheter or electrode through the parenchyma of the brain could presumably lead to tract hemorrhage through direct vascular injury, and efforts should be made to plan a trajectory that avoids any visible vessels during procedural planning. Venous oozing could



**Fig. 3.** CT brain images without contrast. Axial (a) and coronal (b, c) images taken after the patient experienced a neurological decline reveal worsening of the previously seen intraparenchymal and intraventricular hemorrhage. Axial (d) and coronal (e, f) images taken after operative exploration and hematoma evacuation reveal complete resolution of the previously seen hemorrhage.

also be a factor in patients with clotting deficiencies, and standard coagulation studies (e.g., INR, PTT, platelet count) should be a routine component of the preoperative evaluation. During tumor biopsy, bleeding may also occur directly from the lesion itself, and active bleeding from the biopsy cannula should prompt a period of observation and irrigation until the bleeding abates.

Factors such as intraoperative or postoperative hypertension [12], vascularity of the target lesion (e.g., in patients with glioblastoma) [21, 22], and occult coagulopathy [11] in certain patients have been cited as possible explanations for the occurrence of clinically relevant intracranial hemorrhage after intracranial catheter/electrode placement. Among these supposed risk factors, however, only hypertension has been objectively associated with symptomatic hemorrhage [12].

Sansur et al. [12] (2007) retrospectively evaluated the incidence of intracranial hemorrhage occurring after the placement of 567 intraparenchymal electrodes in 259 patients for deep brain stimulation, radiofrequency lesioning (for movement disorders), and seizure focus localiza-

tion. Symptomatic intracranial hemorrhage was discovered in 7 patients (2.7% of patients, 1.2% of all electrodes placed). The majority of these hemorrhages (4/7) occurred after deep brain stimulator electrode placement (although 2/7 occurred after radiofrequency lesioning). Furthermore, only 1 of the symptomatic hemorrhages (1/7) occurred in the target region; the others were seen in the subcortical or intraventricular spaces. Preexisting hypertension was a risk factor for symptomatic hemorrhage in this study ( $p = 0.007$ ), as was a history of Parkinson disease ( $p = 0.007$ ), advanced age ( $p = 0.01$ ), and male sex ( $p = 0.04$ ). Prior use of anticoagulant or antiplatelet medications was not significantly associated with the risk of symptomatic hemorrhage ( $p = 0.95$ ).

In addition to the risks of vascular injury associated with transparenchymal catheter/electrode placement and aspiration (e.g., with stereotactic biopsies), LITT procedures introduce a unique element that could conceivably contribute to the risk of intracranial hemorrhage: direct thermal vascular injury. The thermal dose delivered, the direction of delivery, and the length of time over which

**Table 1.** Review of reported cases of symptomatic intracranial hemorrhage occurring after LITT

Authors	Age, years	Sex	Pathology	LITT target location	Hemorrhage location	Duration to symptom onset/hemorrhage detection	Vascular lesion	Management	Outcome at last follow-up
Jethwa et al. [9], 2012	NR	NR	meningioma	left sylvian fissure	NR	identified after laser fiber/probe insertion and prior to therapy	NR	craniotomy for hemorrhage evacuation	NR
Sloan et al. [4], 2013	44	M	glioblastoma	left parietal	intraparenchymal	6 weeks	pseudo-aneurysm	coil embolization	neurologically intact
Mohammadi et al. [8], 2014	NR	NR	glioblastoma	NR	NR	NR	NR	nonoperative	expired
Mohammadi et al. [8], 2014	NR	NR	glioblastoma	NR	NR	NR	NR	nonoperative	NR
Mohammadi et al. [8], 2014	NR	NR	glioblastoma	NR	NR	NR	NR	nonoperative	NR
Barber et al. [present study]	18	M	epileptic focus, heterotopia	right parietal	intraparenchymal and intraventricular	9 days	possible pseudo-aneurysm	craniotomy for hemorrhage evacuation	resolving hemiparesis

Comprehensive list of reported cases of symptomatic intracranial hemorrhage occurring after LITT, including age and sex of the patients, pathology targeted with LITT, target location, hemorrhage location, duration to symptom onset, whether a vascular lesion was subsequently detected in the hemorrhage location, how the hemorrhage was managed, and patient clinical outcome at the last follow-up visit, where reported. LITT, laser interstitial thermal therapy; NR, not reported.

this dose is delivered are all relatively variable between practitioners and are often tailored to the specific patient and/or lesion being treated. It seems feasible that higher thermal doses delivered over a greater length of time could lead to increased tissue injury and a greater propensity for symptomatic intracranial hemorrhage. The limited amount of available evidence, however, seems to indicate that the risk of symptomatic intracranial hemorrhage after LITT is not appreciably greater than that seen with other stereotactic procedures, despite the addition of thermal injury to the procedure [2–4, 8, 9]. Further study regarding the risks and benefits of varying doses and time frames of heat delivery will be required in order to better characterize the influence of thermal injury on complications and other outcomes.

The majority of previously reported symptomatic intracranial hemorrhages discovered after LITT have occurred in patients undergoing LITT for tumors (Table 1) [2–4, 8, 9]. While it may seem that the vascular proliferation and necrosis associated with high-grade gliomas would increase the risk of symptomatic hemorrhage after stereotactic biopsy or LITT, objective evidence in support of this idea is lacking.

Many of the reported symptomatic intracranial hemorrhages after LITT were discovered almost immediately after the procedure due to neurological deterioration or routine postoperative imaging acquisition. In our case, however, and in the case of 1 other report [4], hemorrhage was discovered 1–6 weeks after the procedure (Table 1). Interestingly, in both cases of delayed symp-

tomatic intracranial hemorrhage after LITT evidence of a pseudoaneurysm was seen within the vicinity of the treatment target or tract on imaging. Sloan et al. [4] (2013) discovered a pseudoaneurysm and associated intracranial hemorrhage in a patient 6 weeks after undergoing an LITT procedure for recurrent glioblastoma when the patient presented with neurological deterioration. The pseudoaneurysm was embolized, and the patient reportedly experienced no further complication or deficit. In our case, evidence of a pseudoaneurysm was seen in the vicinity of the laser fiber/probe tract on CT angiography performed 9 days after the LITT procedure, although no vascular abnormality was seen on conventional catheter angiography performed shortly thereafter, nor was any abnormality directly visualized when the area was explored intraoperatively days later.

Field et al. [11] (2001) similarly described 2 incidences of delayed hemorrhage in patients undergoing stereotactic biopsy for high-grade glioma. In both cases, CT performed 15 min after the procedure was negative for hemorrhage, and both patients were discharged home on postoperative day 1. Both patients returned days later with neurological decline and evidence of large intraparenchymal and/or intraventricular hematomas in the vicinity of the biopsy site. One patient died despite operative intervention, while the other was treated conservatively and eventually discharged with persistent motor deficit. It is unclear whether vascular imaging was performed in these cases, although no findings of pseudoaneurysm or other vascular abnormality are reported.

## Conclusions

We present the first reported case of a symptomatic intracranial hemorrhage occurring more than 1 week after LITT for epilepsy. While the pathophysiology of delayed hemorrhage after LITT is incompletely understood, findings from this case and others suggest that vascular injury and resultant pseudoaneurysm formation may play a role. Further study may further elucidate the mech-

anism involved in such complications and provide guidance to practitioners at high-volume centers in terms of mitigating risk.

## Disclosure Statement

The authors have no conflicts of interest to declare. Specifically, the authors have no personal, financial, or institutional interest in any of the drugs, materials, or devices described in this article.

## References

- 1 Bown SG: Phototherapy in tumors. *World J Surg* 1983;7:700–709.
- 2 Medvid R, Ruiz A, Komotar RJ, Jagid JR, Ivan ME, Quencer RM, et al: Current applications of MRI-guided laser interstitial thermal therapy in the treatment of brain neoplasms and epilepsy: a radiologic and neurosurgical overview. *Am J Neuroradiol* 2015;36:1998–2006.
- 3 Willie JT, Laxpati NG, Drane DL, Gowda A, Appin C, Hao C, et al: Real-time magnetic resonance-guided stereotactic laser amygdalohippocampotomy for mesial temporal lobe epilepsy. *Neurosurgery* 2014;74:569–584.
- 4 Sloan AE, Ahluwalia MS, Valerio-Pascua J, Manjila S, Torchia MG, Jones SE, et al: Results of the NeuroBlate System first-in-humans Phase I clinical trial for recurrent glioblastoma: clinical article. *J Neurosurg* 2013;118:1202–1219.
- 5 Hawasli AH, Kim AH, Dunn GP, Tran DD, Leuthardt EC: Stereotactic laser ablation of high-grade gliomas. *Neurosurg Focus* 2014;37:E1.
- 6 Curry DJ, Gowda A, McNichols RJ, Wilfong AA: MR-guided stereotactic laser ablation of epileptogenic foci in children. *Epilepsy Behav* 2012;24:408–414.
- 7 Schwarzmaier HJ, Eickmeyer F, von Tempelhoff W, Fiedler VU, Niehoff H, Ulrich SD, et al: MR-guided laser-induced interstitial thermotherapy of recurrent glioblastoma multiforme: preliminary results in 16 patients. *Eur J Radiol* 2006;59:208–215.
- 8 Mohammadi AM, Hawasli AH, Rodriguez A, Schroeder JL, Laxton AW, Elson P, et al: The role of laser interstitial thermal therapy in enhancing progression-free survival of difficult-to-access high-grade gliomas: a multicenter study. *Cancer Med* 2014;3:971–979.
- 9 Jethwa PR, Barrese JC, Gowda A, Shetty A, Danish SF: Magnetic resonance thermometry-guided laser-induced thermal therapy for intracranial neoplasms: initial experience. *Neurosurgery* 2012;71(suppl 1):133–144.
- 10 Buckley R, Estronza-Ojeda S, Ojemann JG: Laser ablation in pediatric epilepsy. *Neurosurg Clin N Am* 2016;27:69–78.
- 11 Field M, Witham TF, Flickinger JC, Kondziolka D, Lunsford LD: Comprehensive assessment of hemorrhage risks and outcomes after stereotactic brain biopsy. *J Neurosurg* 2001;94:545–551.
- 12 Sansur C, Frysinger RC, Pouratian N, Fu K-M, Bittl M, Oskouian RJ, et al: Incidence of symptomatic hemorrhage after stereotactic electrode placement. *J Neurosurg* 2007;107:998–1003.
- 13 Beric A, Kelly PJ, Rezai A, Sterio D, Mogilner A, Zonenshayn M, et al: Complications of deep brain stimulation surgery. *Stereotact Funct Neurosurg* 2001;77:73–78.
- 14 Binder DK, Rau GM, Starr PA: Risk factors for hemorrhage during microelectrode-guided deep brain stimulator implantation for movement disorders. *Neurosurgery* 2005;56:722–728.
- 15 Favre J, Taha JM, Burchiel KJ: An analysis of the respective risks of hematoma formation in 361 consecutive morphological and functional stereotactic procedures. *Neurosurgery* 2002;50:48–56.
- 16 Gorgulho A, De Salles A F, Frighetto L, Behnke E: Incidence of hemorrhage associated with electrophysiological studies performed using macroelectrodes and microelectrodes in functional neurosurgery. *J Neurosurg* 2005;102:888–896.
- 17 Lyons KE, Wilkinson SB, Overman J, Pahwa R: Surgical and hardware complications of subthalamic stimulation: a series of 160 procedures. *Neurology* 2004;63:612–616.
- 18 Bernays RL, Kollias SS, Khan N, Brandner S, Meier S, Yonekawa Y: Histological yield, complications, and technological considerations in 114 consecutive frameless stereotactic biopsy procedures aided by open intraoperative magnetic resonance imaging. *J Neurosurg* 2002;97:354–362.
- 19 Jackson RJ, Fuller GN, Abi-Said D, Lang FF, Gokaslan ZL, Shi WM, et al: Limitations of stereotactic biopsy in the initial management of gliomas. *Neuro Oncol* 2001;3:193–200.
- 20 Kongkham PN, Knifed E, Tamber MS, Bernstein M: Complications in 622 cases of frame-based stereotactic biopsy, a decreasing procedure. *Can J Neurol Sci* 2008;35:79–84.
- 21 Kulkarni A V, Guha A, Lozano A, Bernstein M: Incidence of silent hemorrhage and delayed deterioration after stereotactic brain biopsy. *J Neurosurg* 1998;89:31–35.
- 22 Sawin PD, Hitchon PW, Follett KA, Torner JC: Computed imaging-assisted stereotactic brain biopsy: a risk analysis of 225 consecutive cases. *Surg Neurol* 1998;49:640–649.