



Contents lists available at ScienceDirect

Journal of Clinical Neuroscience

journal homepage: www.elsevier.com/locate/jocn

Case report

Successful coil embolization of a ruptured mycotic aneurysm that developed three days after septic embolic infarction: Case report and review of the literature

Joshua L. Wang^a, Archana P. Hinduja^b, Ciarán J. Powers^{a,*}^a Department of Neurological Surgery, The Ohio State University Wexner Medical Center, United States^b Department of Neurology, The Ohio State University Wexner Medical Center, United States

ARTICLE INFO

Article history:

Received 7 November 2016

Accepted 22 January 2017

Available online xxxx

Keywords:

Infectious intracranial aneurysm

Infectious endocarditis

Septic emboli

Coil embolization

Mycotic aneurysm

ABSTRACT

Background: Infectious intracranial aneurysms (IIAs) are rare entities and are often associated with septic embolus from infectious endocarditis. They may develop rapidly and carry a higher risk of rupture and mortality compared to noninfectious aneurysms. However, the development and rupture of an IIA within 48 h in a patient with septic infarction patient is exceedingly rare.

Case description: In this report, we describe a 25-year-old male who presented with left-sided hemiparesis and dysarthria from septic embolus to the right middle cerebral artery. Thirty-nine hours after presentation, he became encephalopathic following a witnessed seizure. Angiography demonstrated a new, ruptured aneurysm, which was successfully treated with endovascular coil embolization. Our study documents the first report of coil embolization in a rapidly developed infectious aneurysm.

Conclusions: Importantly, this case demonstrates that septic infarction may precede and herald IIA development and rupture. If IIA is detected due to rupture, coil embolization can be a safe and effective therapy.

© 2017 Elsevier Ltd. All rights reserved.

1. Introduction

Infectious intracranial aneurysms (IIAs, also referred to as microbial or mycotic intracranial aneurysms) are rare entities, comprising 0.7–6.5% of all intracranial aneurysms [1]. These may develop rapidly and have a higher risk of rupture compared to non-infectious aneurysms. Patients with IIA often present with symptoms associated with infection or aneurysmal subarachnoid hemorrhage (SAH), but rarely as significant neurologic deficits from cerebral thromboembolism. Here, we describe the first case of coil embolization in a patient presenting with ischemic stroke from septic embolism with subsequent development and rupture of IIA during the same hospitalization.

Abbreviations: IIA, infectious intracranial aneurysm; SAH, subarachnoid hemorrhage; CT, computed tomography; MCA, middle cerebral artery; tPA, tissue plasminogen activator; HD, hospital day.

* Corresponding author at: Department of Neurosurgery, The Ohio State University Wexner Medical Center, N1022 Doan Hall, 410 West 10th Avenue, Columbus, OH 43210, United States.

E-mail address: Ciaran.Powers@osumc.edu (C.J. Powers).

2. Case report

A 25-year old male presented to the emergency department with sudden onset of dysarthria and left hemiparesis. He had a prior history of deep venous thrombosis, dental caries, and multiple drug abuse with heroin and cocaine use earlier that day. His initial National Institutes of Health Stroke Scale was 3, and computed tomography (CT) images of the head showed a hyperdense right middle cerebral artery (MCA) sign. He was transferred to our comprehensive stroke center after receiving intravenous tissue plasminogen activator (tPA).

Upon arrival, a CT-angiogram showed partial occlusion of the right MCA proximal to its bifurcation (Fig. 1A and B). Hematology showed a white blood cell count of 12,800 cells/ μ L; C-reactive protein was 46.6 mg/L. He improved markedly overnight with repeat head CT on hospital day #2 (HD #2) demonstrating an acute infarct in the right basal ganglia and anterior insular cortex (Fig. 1C). On auscultation, a new holosystolic murmur was identified. Blood cultures were positive for gram-positive streptococci and broad-spectrum antibiotics were started.

The patient experienced a generalized seizure overnight and received intravenous phenytoin and diazepam and was intubated

<http://dx.doi.org/10.1016/j.jocn.2017.01.021>

0967-5868/© 2017 Elsevier Ltd. All rights reserved.

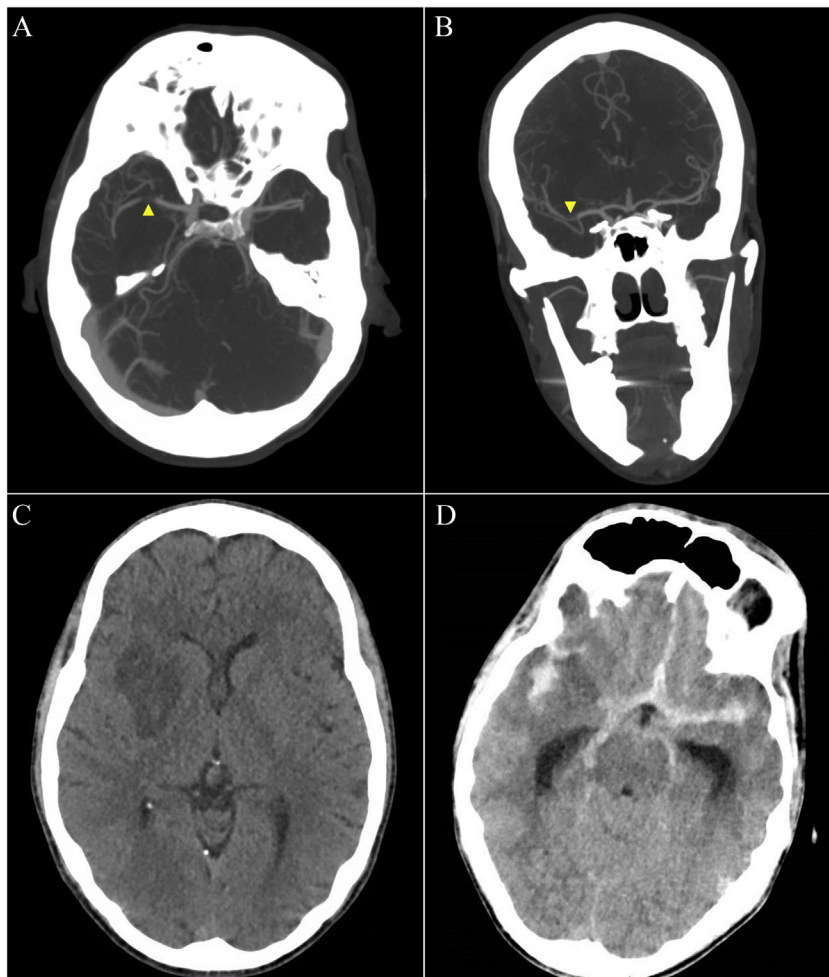


Fig. 1. Axial (A) and coronal (B) views of a computed tomography (CT) angiogram on hospital day #1 showing occlusion (arrowheads) in the M2 segment just distal to the middle cerebral artery (MCA) bifurcation. (C) Axial view of a CT of the head on hospital day #2 showing hypodensity within the right basal ganglia and insular cortex, representing an acute infarct. (D) Axial view of a CT of the head on hospital day #3 showing diffuse subarachnoid hemorrhage with intraventricular extension and resulting moderate acute hydrocephalus.

(HD #3). Repeat head CT performed 39 h after initial presentation demonstrated diffuse subarachnoid hemorrhage with intraventricular extension and moderate acute hydrocephalus (Fisher grade 3, Hunt-Hess grade 4, Fig. 1D), for which an external ventricular drain was placed. Cerebral angiography performed on HD #4 demonstrated mild to moderate diffuse vasospasm and a 5 mm × 3 mm aneurysm at the origin of one of the M2 branches (Fig. 2B), which was treated with coil embolization. Post-treatment angiography showed Raymond 3 residual filling in the aneurysm dome (Fig. 2C).

His course was complicated by cerebral vasospasm, which required daily administration of intra-arterial verapamil from the fifth day till eighth day. His blood cultures grew *Viridans Streptococci*, for which he received a course of intravenous penicillin. Transesophageal ultrasound demonstrated a flail anterior mitral valve leaflet with a small vegetation. He was discharged to a rehabilitation facility at 3 weeks.

Upon follow up at 5 weeks, he displayed remarkable recovery, with mild dysarthria, left facial droop, left upper extremity weakness, and a modified Rankin Score of 2. He is scheduled for a mitral valve replacement.

3. Discussion

The term “mycotic aneurysm” was coined by Osler in 1885 in reference to aneurysms associated with bacterial endocarditis,

and IIAs are now a well-known complication of infectious endocarditis [2].

IIAs result from weakening of the arterial wall from microbial infection [3]. The infectious process and inflammatory response leads to infiltration of neutrophils that results in degradation of the adventitia and media, fragmentation of the internal elastic lamina, and proliferation of the intima [1]. Pulsatile hydrostatic pressure and thrust against the weakened arterial wall results in aneurysm development and growth. IIAs tend to be thin-walled and friable and exhibit a high tendency to rupture and hemorrhage [3]. The vast majority of IIAs result from bacterial infection, most commonly *Staphylococcus aureus* and *Streptococcus* species, though IIAs may also result from fungal or viral infection. Infections leading to IIAs may occur via extravascular invasion or more often via hematogenous spread, most commonly from bacterial endocarditis, as in our patient [4]. Septic emboli preferentially lodge at distal branch points in the MCA, accounting for the anatomic preference of IIAs.

Given the paucity of population-based studies, the natural history of IIAs is unknown, though high rates of fatality have been previously described [1]. IIAs most commonly present following aneurysmal rupture with symptoms related to the rupture and to the underlying etiology of the IIA [3]. Our patient presented with focal neurologic deficits from ischemic stroke secondary to septic embolization. An IIA developed at the site of the septic embolus and subsequently ruptured. Development of an IIA following septic

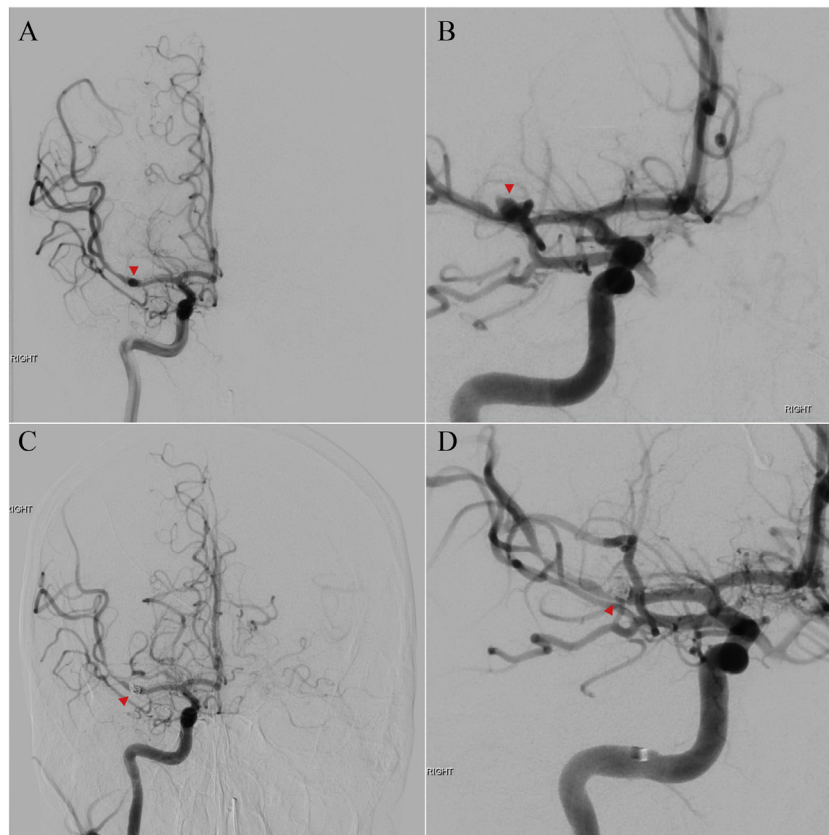


Fig. 2. Anterior–posterior (AP) (A) and oblique (B) views of a cerebral angiogram demonstrating a 3 mm × 5 mm berry aneurysm in the M2 segment just distal of the MCA bifurcation. Post-endovascular coil embolization angiographic images, AP (C) and oblique (D) views, demonstrating the coil mass and reduced residual filling in the aneurysm.

infarct in the same hospitalization is extremely rare. To our knowledge, there have only been 5 cases of SAH following septic embolic infarction reported, all located in the MCA [5–9]. The interval between ischemic onset and aneurysm rupture was less than 4 days in 4 cases and was 20 days in a single case. In our patient's case, the development and rupture of an IIA occurred within 36 h from ischemic presentation. These data suggest that the onset of septic embolism may be detectable prior to the rupture of IIA, but require a high clinical suspicion for an infectious etiology. There is a paucity of data regarding the role of early detection and management of septic emboli and its relation to the growth and development of IIA. Early detection of unruptured IIA may guide in clinical decision-making to reduce the risk of rupture. Conservative management of septic emboli to minimize IIA-related complications includes antibiotics and blood pressure control [1].

Aggressive and proactive treatment of IIAs may be accomplished with open or endovascular approaches. Given the morbidity of open surgery and potential complications when paired with cardiothoracic surgery (e.g. valve replacement for septic vegetations), endovascular treatment is gaining popularity [10]. In addition, endovascular treatment for ruptured aneurysms is favored when there is evidence of radiographic vasospasm. Endovascular therapy has decreased risk of anesthetic complications, rapid institution of anticoagulation therapy, and short time lag between the treatment of the aneurysm and cardiac surgery. Current techniques in endovascular treatment include parent artery occlusion, coil embolization with and without stent-assist, flow diversion, and liquid embolic agents. Given the location and morphology of the IIA in our case, we opted for direct coil embolization of the aneurysm. Although various cases of successful coil embolization of IIAs have been reported, this is the first case to our knowledge of successful endovascular coiling in a patient with septic infarction prior

to development and rupture of an IIA. Other cases with similar presentations were treated with trapping [5,7,8], clipping [9], and conservatively [6]. Endovascular coiling in IIAs carries a risk of aneurysm rupture (or re-rupture) due to the thin and friable wall. Other potential complications include partial occlusion of the parent vessel by coils and persistent filling of the aneurysm.

4. Conclusion

We present a rare case of septic infarction with subsequent development and rupture of an IIA. Our patient was successfully treated with endovascular coil embolization of the IIA. Angiographic evaluation of ischemic strokes in patients with infectious endocarditis or sepsis may reveal IIAs prior to their rupture and provide an opportunity to reduce the risk of aneurysm rupture.

Informed consent

The patient has consented to submission of this case report to the journal.

Funding

This research received no specific grant from any funding agency in the public, commercial, or not-for-profit sectors.

Conflict of interest statement

The authors declare that the article content was composed in the absence of any commercial or financial relationships that could be construed as a potential conflict of interest.

References

- [1] Kanno S, Thomas SV. Intracranial microbial aneurysm (infectious aneurysm): current options for diagnosis and management. *Neurocrit Care* 2009;11:120–9.
- [2] Osler W. The Gulstonian lectures, on malignant endocarditis. *Br Med J* 1885;1:467–70.
- [3] Ducruet AF, Hickman ZL, Zacharia BE, et al. Intracranial infectious aneurysms: a comprehensive review. *Neurosurg Rev* 2010;33:37–46.
- [4] Dhomne S, Rao C, Shrivastava M, et al. Endovascular management of ruptured cerebral mycotic aneurysms. *Br J Neurosurg* 2008;22:46–52.
- [5] Wakamoto H, Tomita H, Miyazaki H, et al [The early hemorrhage and development of a bacterial aneurysm after a cerebral ischemic attack caused by a septic embolism – a case report]. *No Shinkei Geka* 2001;29:415–20.
- [6] Saito A, Kawaguchi T, Hori E, et al. Subarachnoid hemorrhage after an ischemic attack due to a bacterial middle cerebral artery dissecting aneurysm: case report and literature review. *Neurol Med Chir (Tokyo)* 2014;54:196–200.
- [7] Inoue T, Anzai T, Utsumi Y [Early subarachnoid hemorrhage from a bacterial aneurysm of the middle cerebral artery bifurcation following cerebral infarction caused by a septic embolism: case report]. *No Shinkei Geka* 2006;34:1051–5.
- [8] Yamaguchi S, Sakata K, Nakayama K, et al [A surgically treated case with a ruptured bacterial aneurysm of the middle cerebral arterial bifurcation following occlusion]. *No Shinkei Geka* 2004;32:493–9.
- [9] Krapf H, Skalej M, Voigt K. Subarachnoid hemorrhage due to septic embolic infarction in infective endocarditis. *Cerebrovasc Dis* 1999;9:182–4.
- [10] Zanaty M, Chalouhi N, Starke RM, et al. Endovascular treatment of cerebral mycotic aneurysm: a review of the literature and single center experience. *Biomed Res Int* 2013;2013:151643.