

CASE REPORT

Sagittal sinus thrombosis in JAK2-V617F mutation without overt myeloproliferative disorder

Prashant Ramesh Bhand,¹ Supriya Ramesh Karde,¹ Nagabathula Ramesh²

¹Department of General Medicine, Midland Regional Hospital, Portlaoise, Ireland
²Department of Radiology, HSE, Portlaoise, Laois, Ireland

Correspondence to

Dr Prashant Ramesh Bhand,
 prashant.bhand@gmail.com

Accepted 9 February 2017

SUMMARY

We describe a case of a man aged 41 years who presented with a history of generalised headaches for 1 week and an acute episode of tonic-clonic seizures. He had no history of medical illness, was non-smoker, with an extensive family history of haematological disorders. Initial CT brain with contrast did not show any abnormalities in brain parenchyma. X-ray and CT right shoulder showed shoulder dislocation secondary to trauma associated with seizure prior to hospital admission. Subsequently, MRA and MRV brain was arranged, which revealed extensive expansible occlusive filling defect dominating the middle of superior sagittal sinus with left frontal cortical and subcortical acute oedema. He was promptly started on anticoagulation therapy. Considering the unusual site and unprovoked nature of thrombosis, further investigations including JAK2 mutation were arranged which revealed latent myeloproliferative disorder. He was referred to haematology services for further follow-up and monitoring of latent myeloproliferative disorder.

BACKGROUND

Thrombosis is a leading cause of morbidity and mortality in patients with myeloproliferative disorders. Certain somatic mutations like JAK2 V617F, CALR and MPL have been identified in persons with BCR-ABL-negative myeloproliferative disorder. However, JAK2 mutation remains most frequently and distinctively associated with BCR-ABL-negative myeloproliferative disorders with incidence of 98% in polycythaemia vera, 50–60% in essential thrombocythosis and 55–65% in primary myelofibrosis. It is a mutation in the auto-inhibitory domain of tyrosine kinase JAK2 that replaces valine with phenylalanine (V617F) resulting into constitutive kinase activation and plays a key role in the pathogenesis.¹ Thrombosis in JAK2 mutation has been associated with elevated blood counts; whereas in the absence of erythrocytosis or thrombocythosis, it is said to be due to JAK2 mutation operated leucocyte and platelet activation.

In an event of thrombosis at unusual site, a further investigation to rule out thrombophilia is justified. However, the rate of occurrence of JAK2 mutation in association with cerebral venous thrombosis is unknown and the value of JAK2 screening in such group of patients remains unexplored. Nonetheless, JAK2 mutations have a potential of transformation into an overt disease and therefore need close monitoring.

CASE PRESENTATION

A man aged 41 years brought in by ambulance to emergency department with an episode of tonic-clonic seizures followed by right shoulder pain. He had further two episodes of tonic-clonic seizures with up rolling of eyes, tongue biting and urinary incontinence in emergency department of which previous episode occurred while waiting for X-ray of his shoulder. Further questioning revealed generalised headaches for 1 week with intermittent relief with paracetamol.

He had no history of any medical illness, was non-smoker and denied any illicit drug abuse. In terms of family history, his father was diagnosed with myelofibrosis at the age of 73, maternal aunt had deep vein thrombosis at the age of 20 with subsequent multiple miscarriages, also 1 of her children was described to have Factor V Leiden and another child as being heterozygous carrier for Factor V Leiden.

INVESTIGATIONS

CT brain with contrast was performed initially, which did not show any abnormalities. Meanwhile, X-ray and CT right shoulder revealed shoulder dislocation, reverse Hill-Sachs lesion of right humerus with reverse Bankart lesion of the glenoid secondary to trauma associated with seizure prior to presentation in emergency department. Routine investigations including full blood count, renal function tests, liver function tests, CRP, serum glucose, coagulation profile were all normal except d-dimers of 5862.5 (normal range (0–500)). In addition, an echocardiogram was arranged to rule out an intracardiac thrombus, which was normal. MRI and MRV brain eventually revealed extensive expansible occlusive filling defect dominating the middle of superior sagittal sinus with left frontal cortical and subcortical acute oedema causing mild positive mass effect (figures 1–3)

Further investigations including serum protein electrophoresis, ANA, ANCA, ENA, viral screen (herpes simplex virus 1 and 2, varicella-zoster, EBV, enterovirus, CMV) and PNH screen (CD 59, FLAER, CD 157) were unremarkable. Blood film revealed teardrop cells with platelet anisocytosis. DNA analysis in quantitative PCR assay was requested which detected JAK2 V617F mutation. Considering presence JAK2 V617F mutation associated with thrombosis, a bone marrow biopsy/aspirate was performed by haematology team, which confirmed morphological features in keeping with silent myeloproliferative disorder.



CrossMark

To cite: Bhand PR, Karde SR, Ramesh N. *BMJ Case Rep* Published online: [please include Day Month Year] doi:10.1136/bcr-2016-218298

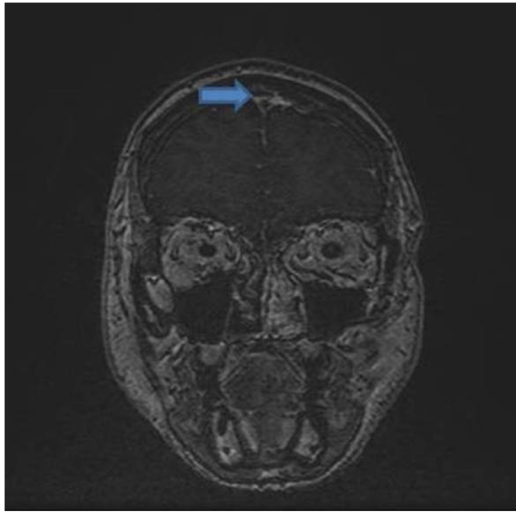


Figure 1 MRV cranial showing extensive, occlusive filling defect dominating the middle superior sagittal sinus.

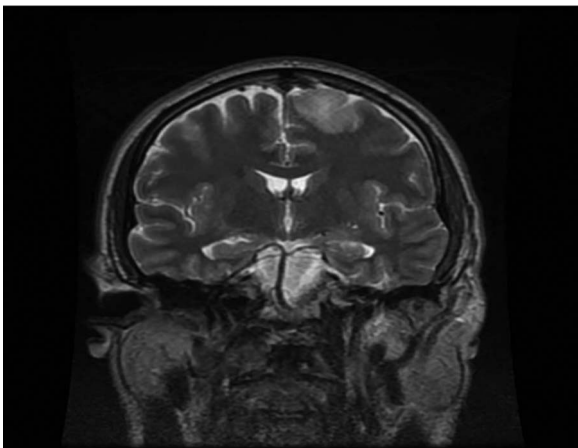


Figure 2 Coronal T2-weighted image showing blurring of superior sagittal sinus flow.

DIFFERENTIAL DIAGNOSIS

Sagittal sinus thrombosis secondary to undiagnosed hypercoagulable disease.

TREATMENT

In consultation with haematology team, he was started on warfarin with target INR 2–3 and bridging with therapeutic dose low molecular weight heparin. As he did not have any, clinical manifestation of myeloproliferative disorder other than the presence of JAK2 mutation and thrombosis, no treatment was indicated other than lifelong anticoagulation. He was also started on levetiracetam as advised by neurology team, which was subsequently changed to zonisamide in view of deranged liver function tests.

OUTCOME AND FOLLOW-UP

He is currently under regular follow-up with the haematology and neurology teams.

DISCUSSION

Myeloproliferative neoplasms include a range of disorders namely polycythaemia vera, essential thrombocytosis, primary

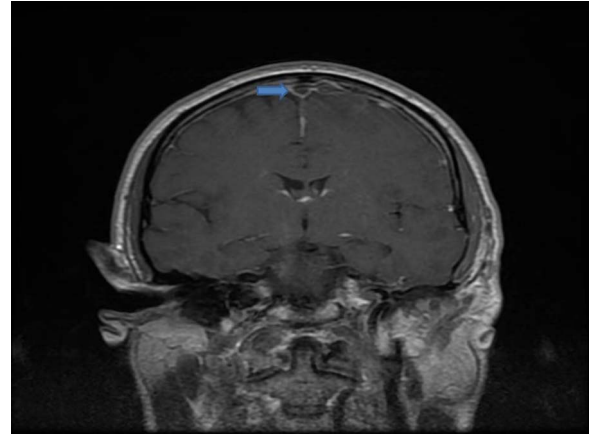


Figure 3 Coronal postcontrast T1-weighted image showing expansile continuous filling defect dominating superior sagittal sinus with left frontal cortical and subcortical acute oedema.

myelofibrosis, chronic myeloid leukaemia (bcr-abl positive) and four other poorly characterised disorders.¹ Somatic mutations like JAK2, CALR and MPL are peculiar to bcr-abl-negative myeloproliferative disorder; however, JAK2 remains the most frequent with incidence of ~98% in polycythaemia vera, 50–60% in essential thrombocytosis, and 55–65% in primary myelofibrosis.² It is a substitution of valine by phenylalanine at amino acid V617F resulting in activation of tyrosine kinase facilitating a factor independent of growth and cytokine sensitivity of haematopoietic cells.³ The mutation may be infrequently found in normal individuals using ultrasensitive techniques and is not detected in cases of reactive conditions with elevated blood counts.⁴ Venous thrombosis in common sites as the deep circulation of the lower limbs is typical; however, venous thrombosis at unusual sites like splanchnic circulation and to lower degree in cerebral circulation is not as rare as in common population,^{5 6} especially in young patients.

Cerebral venous thrombosis albeit a rare clinical phenomenon is a life-threatening condition and a major cause of morbidity and mortality in myeloproliferative disorders. A spectrum of disorders have been identified to have potential risk of cerebral venous thrombosis, for example, trauma, neoplasms, chronic inflammatory diseases, various hypercoagulable states and indeed involve multiple complex mechanisms.^{7 8} The underlying mechanisms are related to alterations in the physical properties of the dural sinuses and veins, the chemical and haemodynamic properties of blood flow due to raised blood counts, vascular injury from trauma causing endothelial damage.⁹ Though JAK2 mutation has been consistently associated with raised erythrocytosis and thrombosis,¹⁰ it has been speculated that thrombosis in the absence of elevated blood counts may be mediated by JAK2-driven platelet and leucocyte activation.¹¹ The presence of JAK2 mutation without myeloproliferative disorder may indicate an early or latent disease with potential for transformation into overt disease in future. Thus, cerebral venous thrombosis in such cases can be the first manifestation of MPN or can even present few years before development of overt disease.

Many epidemiological studies have confirmed an upward trend in the prevalence of thrombosis with increasing age in individuals with myeloproliferative disorders. Also, previous thrombotic events independently contribute to the future risk of such events. Reportedly, age and previous thrombotic events have complex interaction, which is a positive determinant of

probability of recurrent thromboses.¹² Although the symptoms may vary depending on the site and extent of the thrombus, headache is the most common presentation seen in 89% and in 8% the only symptom. Seizures and focal deficits may occur due to thrombus extending to cortical vein and to lesser extent in the case of sagittal sinus thrombosis.¹³ MRA/MRV remains the gold standard for detecting cerebral venous thrombosis. The false-negative rate for CT diagnosis is high; however, hyperdense cortical veins or sinuses may be seen on non-contrast CT brain and non-opacified thrombus may be seen on contrast-enhanced CT brain.⁹ A positive D-dimers supports the probability of clinical diagnosis but a normal D-dimers does not exclude the diagnosis.

The recommended treatment for venous thromboembolism in myeloproliferative disorder does not differ from general population. Low molecular weight heparin is used during acute phase followed by oral anticoagulant. Short-term anticoagulation with pharmacological cyto-reduction followed by low-dose aspirin may be employed for patients not undergoing chemotherapy or undiagnosed disease with venous thrombosis at usual site. However, an anticoagulant and aspirin for longer period may be necessary for patients on chemotherapy. On the contrary, there are no clear guidelines governing anticoagulation in venous thrombosis at unusual site and treatment is usually decided on individual basis.¹² Primary prevention with anticoagulant should be offered in high-risk cases.

Cerebral venous thrombosis could indeed be a herald sign of impending myeloproliferative disorder. JAK2 V617F mutation though frequent in patients with splanchnic vein thrombosis, it is relatively uncommon in patients with arterial thrombosis and venous thrombosis at other locations.¹⁴ Thus,

the exact frequency of JAK2 mutation in the cerebral venous thrombosis cohort is unclear, which invariably questions significance of such investigation. Also many studies have been performed to analyse the sensitivity of JAK2 in recognising the risk of venous thromboembolism in myeloproliferative disorder, results of which are largely inconsistent and uncertain. Nevertheless, further research focusing on the merit of JAK2 mutation in the case of cerebral venous thrombosis regardless of the presence myeloproliferative disorder needs to be encouraged.

Contributors PRB involved in diagnosis and treatment plan of the patient also writing case report. SRK helped in writing and editing case report and collecting clinical data. NR provided help to get radiological images and reporting of radiological images.

Competing interests None declared.

Patient consent Obtained.

Provenance and peer review Not commissioned; externally peer reviewed.

REFERENCES

- 1 Kasper DL, Harrison TR. *Harrison's principles of internal medicine*. New York: McGraw-Hill, Medical Pub. Division, 2015.
- 2 Tefferi A, Guglielmelli P, Larson DR, et al. Long-term survival and blast transformation in molecularly annotated essential thrombocythemia, polycythemia vera, and myelofibrosis. *Blood* 2014;124:2507–13.
- 3 James C, Ugo V, Le Couédic JP, et al. A unique clonal JAK2 mutation leading to constitutive signalling causes polycythaemia vera. *Nature* 2005;434:1144–8.
- 4 P'ng S, Carnley B, Baker R, et al. Undiagnosed myeloproliferative disease in cases of intra-abdominal thrombosis: the utility of the JAK2 617F muta. *Clin Gastroenterol Hepatol* 2008;6:472–5.
- 5 Casini A, Fontana P, Lecompte TP, et al. Thrombotic complications of myeloproliferative neoplasms: risk assessment and risk-guided management. *J Thromb Haemost* 2013;11:1215–27.
- 6 Smalberg JH, Arends LR, Valla DC, et al. Myeloproliferative neoplasms in Budd-Chiari syndrome and portal vein thrombosis: a meta-analysis. *Blood* 2012;120:4921–8.
- 7 Bousser MG, Ferro JM. Cerebral venous thrombosis: an update. *Lancet Neurol* 2007;6:162–70.
- 8 Bousser MG. Cerebral venous thrombosis: diagnosis and management. *J Neurol* 2000;247:252–8.
- 9 Liu KC, Hamilton BE, Barnwell SL. Cerebral venous and sinus thrombosis. *Youmans Neurol Surg* 2011;4:3698–705.e2, Chapter 357.
- 10 Hexner EO. JAK2 V617F: implications for thrombosis in myeloproliferative diseases. *Curr Opin Hematol* 2007;14:450–4.
- 11 Arellano-Rodrigo E, Alvarez-Larrán A, Reverter JC, et al. Increased platelet and leukocyte activation as contributing mechanisms for thrombosis in essential thrombocythemia and correlation with the JAK2 mutational status. *Haematologica* 2006;91:169–75.
- 12 Landolfi R, Di Gennaro L, Falanga A. Thrombosis in myeloproliferative disorders: pathogenetic facts and speculation. *Leukemia* 2008;22:2020–8.
- 13 Thorell SE, Parry-Jones AR, Punter M, et al. Cerebral venous thrombosis—a primer for the haematologist. *Blood Rev* 2015;29:45–50.
- 14 Xavier SG, Gadelha T, Rezende SM, et al. Spector N.JAK2V617F mutation in patients with thrombosis: to screen or not to screen? *Int J Lab Hematol* 2011;33:117–24.

Learning points

- ▶ Thrombotic events like cerebral venous thrombosis undoubtedly warrant further investigations and screening for JAK2 may appear crucial in diagnosing latent myeloproliferative disorder in such cases as illustrated by our case report.
- ▶ Such patients often need long-term surveillance for possibility of future transformation to myeloproliferative disorder.
- ▶ Further studies exemplifying the prevalence of JAK2 mutation in the case of cerebral venous thrombosis need to be emphasised and supported.

Copyright 2017 BMJ Publishing Group. All rights reserved. For permission to reuse any of this content visit <http://group.bmj.com/group/rights-licensing/permissions>.
BMJ Case Report Fellows may re-use this article for personal use and teaching without any further permission.

Become a Fellow of BMJ Case Reports today and you can:

- ▶ Submit as many cases as you like
- ▶ Enjoy fast sympathetic peer review and rapid publication of accepted articles
- ▶ Access all the published articles
- ▶ Re-use any of the published material for personal use and teaching without further permission

For information on Institutional Fellowships contact consortiasales@bmjgroup.com

Visit casereports.bmj.com for more articles like this and to become a Fellow