

## Case report

# Transient global amnesia in immediate postoperative period: A diagnostic dilemma



Anudeep Jafra<sup>a,\*</sup>, Tanvir Samra<sup>b</sup>, Vasudha Gupta<sup>b</sup>, M Seran Kumar Reddy<sup>b</sup>

<sup>a</sup> Department of Anaesthesia and Intensive Care, Post Graduate Institute Of Medical Education and Research, Sector-12, 160012 Chandigarh, India

<sup>b</sup> Post Graduate Institute Of Medical Research and Education, Sector-12, 160012 Chandigarh, India

## ARTICLE INFO

## Article history:

Received 7 May 2016

Received in revised form 1 November 2016

Accepted 7 December 2016

Available online xxxx

## Keywords:

Memory

Amnesia

Transient global amnesia

## ABSTRACT

**Introduction:** Transient Global Amnesia (TGA) is short-term inability to form new memories despite otherwise normal neurological function. There is associated anterograde and retrograde amnesia. The memory loss is often accompanied by repetitive questioning and temporal disorientation while higher cognitive functions are preserved. The symptoms usually resolve by 24 h.

**Case report:** We present an interesting case of 31 year old female who was planned for robotically assisted right sided pyeloplasty. 30 min after emergence from anaesthesia patient was disoriented, with retrograde and anterograde amnesia, but neurological function was intact. Neurologic imaging revealed no abnormality. 36 h later patient was able to recall everything.

**Discussion:** The pathogenesis of TGA has more recently been attributed to cerebral venous hypertension resulting from retrograde jugular venous flow. Precipitating events are Valsalva manoeuvre, emotion/stress/pain, Excessive exertion, sexual intercourse and swimming in cold water.

**Conclusion:** TGA presents dramatically, it needs to be differentiated from cerebral event. It resolves on its own. But one needs to be aware of existence of such an entity.

© 2016 Elsevier Inc. All rights reserved.

## 1. Introduction

Transient global amnesia (TGA) is characterized by temporary disruption of short term memory. There is inability to form new memories, anterograde amnesia which is abrupt in onset and associated retrograde amnesia which ranges from few hours to years [1]. The imperative feature is patient is alert, attentive and there is no clouding of consciousness or loss of personal identity. Usually the symptoms resolve by 30 min to 24 h. Once the attack is over there occurs rapid and complete return of anterograde memory, but retrograde memory is slow to return to normal and patient is not able to recall the present episode of memory loss. We present a case of TGA in a young female following robotically assisted laparoscopic pyeloplasty under general anaesthesia and highlighting the differential diagnosis, precipitating events and treatment of this rare neurological entity.

## 2. Case report

31 year old female patient belonging to American Society of Anaesthesiologists physical status classification 1, weighing 42 kg was administered general anaesthesia for robotically assisted laparoscopic pyeloplasty. Her biochemical and hematological investigations were in normal limits and past medical history was insignificant. Patient was premedicated with H<sub>2</sub> blocker (ranitidine 150 mg) and benzodiazepine (alprazolam 0.25 mg). Intraoperative monitoring included electrocardiogram, pulse oximetry, end tidal carbon dioxide measurement, non-invasive blood pressure measurement and temperature monitoring. Patient was induced with 100% oxygen using propofol 2 mg/kg, Muscle relaxation was achieved using vecuronium 0.1 mg/kg, for analgesia-4.5 mg morphine was given, airway was secured with 7.5 mm endotracheal tube. Anaesthesia was maintained using desflurane in 50% oxygen in air mixture. Patient was operated in left lateral decubitus position and surgery lasted for two hours. Intraoperatively hemodynamics remained stable with no episode of hypotension. Extubation was smooth and uneventful; patient was conscious and responding to commands.

30 min after surgery, in postanesthesia care unit patient was not able to recall names of family members and was repeatedly asking 'where am I'. Patient was conscious and oriented but there was total amnesia of her hospitalization for the surgery. Neurological examination including higher mental functions and cranial nerve examination were

\* Corresponding author: Post Graduate Institute of Medical Education and Research, Sector-12, Chandigarh 160012, India.

E-mail addresses: anu\_gmch@yahoo.co.in (A. Jafra), drtanvirsamra@yahoo.in (T. Samra), dr.vasudhagupta@gmail.com (V. Gupta), seranreddy.m@gmail.com (M. Seran Kumar Reddy).

**Table 1**  
Postoperative investigations.

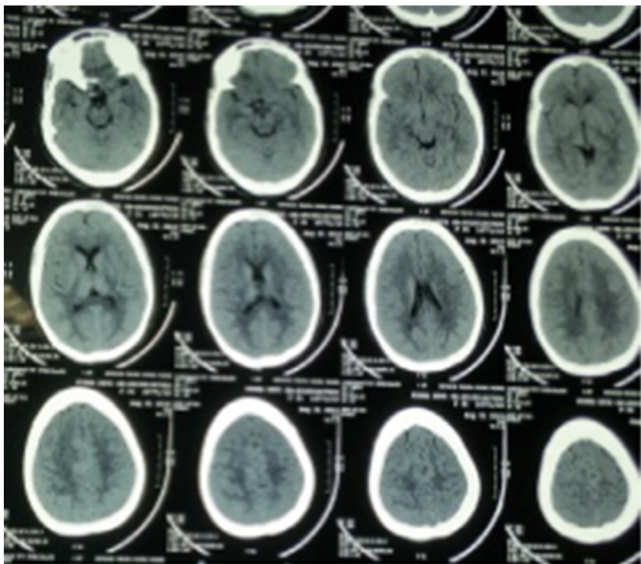
Postoperative	Hb-10.6 g% Blood sugar-110 mg%	Na <sup>+</sup> - 142 meq/l K <sup>+</sup> - 3.8 meq/l
ABG-pH -7.36/paO <sub>2</sub> -80/paCO <sub>2</sub> -38/HCO <sub>3</sub> -22.8/BE-1.5/Cl <sup>-</sup> -98.9		

normal. Electrolyte/metabolic abnormality were ruled out on normal values of arterial blood gas analysis and biochemical investigations (Table 1). Non-contrast computed tomography scan of head (Fig. 1) was done 6 h later but it was normal. A detailed neurological and psychiatric evaluation was done and patient failed in all tests for short term memory. Patient was shown five objects which 30 s later when again shown to her she was not able to recognize and refused that she was shown these before. Mini Mental State Examination (MMSE) score was 26; deficit was seen only in amnesic components. Patient was closely observed and monitored and no active intervention was done on second postoperative day. She was not able to recall any past events, not able to recognize her own children but there was no loss of personal identity. After 36 h patients memory recovered and she was able to recall all her past and present history but was not able to recall this event of memory loss and the surgery she had undergone. MMSE score after the episode was 30/30.

### 3. Discussion

TGA was first described by Fischer and Adams in 1958; it is characterized by transient loss of memory in an otherwise healthy patient [2]. The annual incidence ranges from 3 to 32/100,000/year, with slight female preponderance. There is a brief period of anterograde amnesia and retrograde amnesia which extends to days or weeks to years which subsequently shrinks over time and finally patient is left with permanent amnesia for a short duration when new memories were not formed. This is accompanied by repetitive questioning by the patient as to “where am I”, “Why I am here” and associated temporal dissociation could be there. But there are no focal neurological symptoms and all higher cortical functions like language, calculations, reasoning, abstract thinking are intact and patient is calm but disoriented to time and place. Though a rare entity, the literature search shows its existence after both general and spinal anaesthesia [3,4].

In our case the following differential diagnosis were made; acute confusional states (ACS), complex partial seizures, transient epileptic



**Fig. 1.** Non-contrast computed tomography scan of head - normal.

amnesia (TEA), transient ischaemic attack (TIA), toxic metabolic states, psychogenic amnesia, migraine and paradoxical embolism from patent foramen ovale. In ACS patients are inattentive and there is loss of stream of thoughts so it was ruled out. There was no episode of seizure in our patient so possibility of complex partial seizures was not there. TEA is a manifestation of temporal lobe epilepsy, and patients will have multiple episodes characterized by amnesia and symptoms usually last for less than one hour which did not occur in our case. In psychogenic amnesia there is profound retrograde amnesia with loss of personal identity but intact anterograde memory, which did not correspond to the symptoms in our patient. TIA was ruled out as there was no motor and sensory loss in our patient and also CT scan of the patient was normal. In contrast the CT images in acute embolic stroke might show early ischaemic changes. We labeled our patient with TGA after excluding all the above causes and using diagnostic criteria (Table 2) laid down in 1990 by Hodges JR and Warlow CP [5].

Etiology of TGA is obscure; large number of hypothesis has been given. Most commonly affected areas of brain linked to TGA are mediobasal temporal, hippocampus and parahippocampus. Neuroimaging modalities like single photon emission computed tomography scan show decreased blood flow in these areas in TGA patients. Also diffusion weighted imaging studies show changes in the mentioned areas after 48 h of the event [6,7]. And before onset of TGA most patients have Valsalva like precipitating activities like swimming, sexual intercourse, acute pain, coughing, straining and immersion in cold water. Lewis suggested Valsalva manoeuvre allows brief retrograde transmission of high venous pressure to the cerebral venous system, due to jugular valve incompetence resulting in venous ischaemia [8]. Sander D et al. studied the venous flows in internal jugular vessels in 21 patients with TGA and 21 controls using two Valsalva manoeuvres and concluded that TGA was attributable to venous congestion and consequent venous ischaemia to bilateral diencephalic or hippocampal structures [9]. During perioperative period patients may undergo substantial pain, emotional and physical stress which leads to increase intrathoracic pressure, leading to decreased cerebral venous return from the superior vena cava and increased cerebral venous pressure, thereby causing venous ischemia due to cerebral venous congestion and hence can trigger an episode of TGA [10]. Pantoni et al. suggested the contribution of psychological factors and reported that 50% patients with TGA had a phobic personality trait [11]. Recently, a unifying hypothesis has been put forward by Winbeck et al. which suggests that TGA can result from transient ischaemia of memory-relevant structures either from arterial emboli or from venous ischaemia with Valsalva-like activities before the onset of symptoms [7].

Factors like coughing during extubation, generation of large levels of negative pressure by patient during extubation, positive end expiratory pressure and Valsalva manoeuvre might have lead to increased intrathoracic pressure and venous backflow in our patient. Perioperative factors like anxiety, pain, emotions and stress could also have acted as precipitating factors. The drugs used in the patient were all short acting (including desflurane- low blood gas solubility): it is unlikely that such prolonged amnesia was due to residual pharmacological effects of drugs. Usually the attack lasts for less than 24 h duration but the diagnostic criteria which have been laid out have not been validated as to

**Table 2**  
Diagnostic criteria.

1.	Attack must be witnessed
2.	Acute onset of anterograde amnesia during the attack
3.	No clouding of consciousness
4.	No cognitive impairment other than amnesia (no aphasia or apraxia)
5.	No loss of personal identity
6.	No focal neurology or epileptic features must be present
7.	Patients with recent head trauma or seizures were excluded
8.	Attack must resolve within 24 h
9.	Other causes of amnesia must be excluded

whether they can be successfully applied in clinical practice to this subset of patients with postoperative amnesia. If diagnosis can be made on basis of history and examination no further testing or investigations are required. Though in 1995, Sandson and Price suggested a myriad group of investigations including electro encephalogram, echocardiography, Doppler, magnetic resonance imaging, magnetic resonance angiography, holter monitoring and toxicology screening [12]. Diffusion weighted magnetic resonance imaging (DW-MRI) was the next imaging modality of choice in our patient but due to absence of any localising signs it was postponed. Sedlaczek et al. showed with serial imaging DWI changes were rarely noted in the acute phase but were evident at 48 h [13]. However some investigators report no detectable DWI changes [7]. The recurrence is rare with an incidence of 3–20% in 5 years. It does not lead to any long term neurological sequelae and no treatment is required.

#### 4. Conclusion

TGA presents in a very dramatic manner, is a self-limiting condition and does not lead to any long term neurological deficit. But it needs to be differentiated from acute cerebral ischaemic event and thorough neurological examination is a must. One needs to be aware of existence of such an entity to relieve the anxiety of patient's relatives and reassure that the event will resolve spontaneously.

#### Conflict of interest

No conflicts of interest.

#### Funding

This case report did not receive any specific grant from funding agencies in the public, commercial, or not-for-profit sectors.

#### Acknowledgement

Published with written consent of the patient.

#### References

- [1] Zeman AZ, Hodges JR. Transient global amnesia. *Br J Hosp Med* 1997;58:257–60.
- [2] Fischer CM, Adams RD. Transient global amnesia. *Trans Am Neurol Assoc* 1958;83:143–6.
- [3] Wood T, Donegan J. Transient global amnesia following general anesthesia. *Anesthesiology* 1985;62:807–9.
- [4] Dykes MHM, Chir B. Transient global amnesia following spinal anesthesia. *Anesthesiology* 1972;36:615–72.
- [5] Hodges JR, Warlow CP. Syndromes of transient amnesia: towards a classification. A study of 153 cases. *J Neurol Neurosurg Psychiatry* 1990;53:834–43.
- [6] Sander K, Sander D. New insights into transient global amnesia: recent imaging and clinical findings. *Lancet Neurol* 2005;4:437–44.
- [7] Winbeck K, Etgen T, von Einsiedel HG, et al. DWI in transient global amnesia and TIA: proposal for an ischaemic origin of TGA. *J Neurol Neurosurg Psychiatry* 2005;76:438–41.
- [8] Lewis SL. Aetiology of transient global amnesia. *Lancet* 1998;352:397–9.
- [9] Sander D, Winbek K, Etgen T, Knapp R, Klingelhofer J, Conrad B. Disturbance of venous flow patterns in patients with transient global amnesia. *Lancet* 2000;356:1982–4.
- [10] Fischer CM. Transient global amnesia: precipitating activities and other observations. *Arch Neurol* 1982;39:605–8.
- [11] Pantoni L, Bertini E, Lamassa M, et al. Clinical features, risk factors, and prognosis in transient global amnesia: a follow-up study. *Eur J Neurol* 2005;12:350–6.
- [12] Sandson TA, Price BH. Transient global amnesia. *Semin Neurol* 1995;15:183–7.
- [13] Sedlaczek O, Hirsch JG, Grips E, et al. Detection of delayed focal MR changes in the lateral hippocampus in transient global amnesia. *Neurology* 2004;62:2165–70.