

Case Studies

Different Perfusion Patterns in a Patient with Acute Ischemic Stroke

Salvatore Rudilosso, MD,* Carlos Laredo, MSc,*† Xabier Urrea, MD, PhD,*† and Ángel Chamorro, MD, PhD*†

A 29-year-old male patient with aphasia and mild weakness of the right arm arrived at the emergency room 4 hours after symptom onset. The computed tomography perfusion showed a typical delay in the time-based maps in the left occipital lobe and another hyperperfused area in the left frontal lobe. The follow-up magnetic resonance imaging confirmed cortical ischemic lesions in both areas. This case shows that besides hypoperfusion, hyperperfusion can also be found in the first stages of acute stroke, and it is highly suggestive of established ischemic lesions.

Key Words: Ischemic stroke—CT perfusion—hyperperfusion—reperfusion.

© 2017 National Stroke Association. Published by Elsevier Inc. All rights reserved.

Case Presentation

We present a case of a 29-year-old male patient, with no cardiovascular risk factors other than smoking habit, who presented with sudden motor aphasia, weakness, and hypoesthesia of the right arm. On his arrival at the emergency service 4 hours after symptom onset, he was improving, but the examination still showed mild right upper limb weakness. Nonenhanced computed tomography (CT) scan showed loss of cortical gray-white differentiation in part of the left frontal lobe (Fig 1). The perfusion maps showed a typical image of delay in time-based maps and reduced flow in the left occipital lobe and a hyperperfused area with no delay and increased flow in the left frontal lobe (Fig 1). All vessels were patent on CT angiography. The patient did not receive any acute

reperfusion therapy as he was almost recovered after neuroimaging. The follow-up magnetic resonance imaging 72 hours later showed ischemic lesions on diffusion-weighted imaging that matched both areas with altered perfusion (Fig 1). The full etiologic workup showed only a patent foramen ovale, but no deep venous thrombosis or prothrombotic disorders. The patient fully recovered and was discharged on antiplatelet therapy.

Discussion

Cortical hyperperfusion has been seen not only in stroke mimics such as hypermetabolism in focal seizures,¹ but also in acute stroke, especially after thrombolysis.^{2,3} This case report demonstrates that local hyperperfusion can be present in the very first stages of ischemic stroke and that different patterns of perfusion can be found at the same time. Hyperperfused areas in acute ischemic stroke seem to reflect tissue that is already infarcted. Actually in this case, the nonenhanced CT showed signs of established ischemia inside the hyperperfused area. We speculate that the hyperperfusion may be the result of spontaneous reperfusion in brain vessels with impaired autoregulatory capacity due to ischemia. Regional differences in collateral circulation and in the ischemic threshold may explain why hypo- and hyperperfused areas co-exist after cerebral ischemia. The prognostic value of

From the *Functional Unit of Cerebrovascular Diseases, Hospital Clínic, Barcelona, Spain; and †Institut d'Investigacions Biomèdiques August Pi i Sunyer, Barcelona, Spain.

Received December 21, 2016; accepted February 20, 2017.

Address correspondence to Xabier Urrea, MD, PhD, Institute of Neurosciences, 170 Villarroel, 08036 Barcelona, Spain. E-mail: xurra@clinic.cat; @xabierurra.

1052-3057/\$ - see front matter

© 2017 National Stroke Association. Published by Elsevier Inc. All rights reserved.

<http://dx.doi.org/10.1016/j.jstrokecerebrovasdis.2017.02.025>

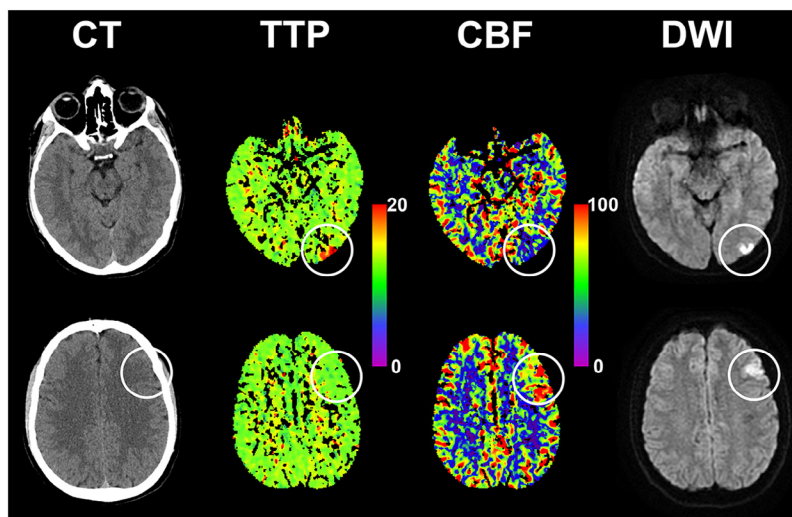


Figure 1. Nonenhanced computed tomography (CT), CT perfusion, and follow-up diffusion-weighted imaging (DWI) studies.

The first row shows a hypoperfused lesion with delay in the time-to-peak (TTP) map and a reduced cerebral blood flow (CBF) area. The second row shows a hyperperfused lesion characterized by a normal TTP map and a hyperperfused area in the CBF map. The nonenhanced CT shows early ischemic changes in this area. In both cases, an ischemic lesion was found in the follow-up DWI. The white circles point out the described findings.

these findings is still controversial: early positron emission tomography studies described that spontaneous hyperperfusion in ischemic stroke could be related to better outcome,⁴ but later studies showed that hyperperfusion was associated with hemorrhagic transformation.³ From a practical point of view, clinicians should be aware that in a patient with acute neurological deficits, hyperperfused areas on CT perfusion that respect a vascular territory are highly suggestive of established ischemic lesions.

References

1. Payabvash S, Oswood MC, Truwit CL, et al. Acute CT perfusion changes in seizure patients presenting to the emergency department with stroke-like symptoms: correlation with clinical and electroencephalography findings. *Clin Radiol* 2015;70:1136-1143. doi:10.1016/j.crad.2015.06.078.
2. Shahi V, Fugate JE, Kallmes DF, et al. Early basal ganglia hyperperfusion on CT perfusion in acute ischemic stroke: a marker of irreversible damage? *AJNR Am J Neuroradiol* 2014;35:1688-1692. doi:10.3174/ajnr.A3935.
3. Yu S, Liebeskind DS, Dua S, et al. Postischemic hyperperfusion on arterial spin labeled perfusion MRI is linked to hemorrhagic transformation in stroke. *J Cereb Blood Flow Metab* 2015;35:630-637. doi:10.1038/jcbfm.2014.238.
4. Marchal G, Furlan M, Beaudouin V, et al. Early spontaneous hyperperfusion after stroke. A marker of favourable tissue outcome? *Brain* 1996;119:409-419.