

Carotid Endarterectomy to Remove Retained Solitaire Stent Retriever inside Carotid Stent after Mechanical Thrombectomy

Mary In-Ping Huang Cobb, MD,* Tony P. Smith, MD,† Patrick A. Brown, MD,†
L. Fernando Gonzalez, MD,* and Ali R. Zomorodi, MD*

Background: Tandem occlusions of the internal carotid artery (ICA) and middle cerebral artery (MCA) occur in up to a third of patients with acute ischemic strokes undergoing endovascular mechanical thrombectomy. Understanding open neurosurgical management of associated complications with this procedure is important. *Case Report:* A 67-year-old man with acute onset of left hemiparesis and a tandem right ICA and MCA occlusion. He underwent carotid stent angioplasty of a stenotic ICA, followed by attempted Solitaire stent retrieval of an MCA clot. On withdrawal, the tines of the Solitaire stent lodged inside the Precise carotid stent. The patient was started on aspirin, Plavix, and heparin infusion, and underwent a carotid endarterectomy (CEA) with safe removal of the stents and primary vessel repair. *Conclusion:* This is the first case reported to date of a Solitaire stent becoming lodged inside a Precise carotid stent, salvaged by CEA with safe removal of the stents and primary vessel repair. We discuss the timing, indication, alternatives, and technical nuances of a CEA in this setting. **Key Words:** Carotid endarterectomy—carotid stent—carotid stenosis—mechanical thrombectomy—retained stent—solitaire stent—tandem occlusion.

© 2017 National Stroke Association. Published by Elsevier Inc. All rights reserved.

Introduction

Carotid endarterectomy (CEA) has become the primary treatment for carotid stenosis, with carotid artery stenting reserved for symptomatic patients with >70% stenosis and at high risk for CEA (e.g., those with severe cardiac disease, a history of CEA with recurrent stenosis, contralateral

carotid occlusion, and history of radiation to the neck).¹ Case studies have described the use of CEA as a salvage therapy to remove either restenosed carotid stents deemed unsalvageable with balloon-assisted stent angioplasty, removal of a fragmented carotid stent, or stent migration.^{2,21} Surgical removal of an intra-arterial stent is risky secondary to the potential endothelialization of the stents to the lumen of the vessel walls, making removal difficult without perforating the native vessel.

With 10%-30% of acute ischemic strokes presenting with tandem internal carotid artery (ICA) and middle cerebral artery (MCA) occlusions, many patients are undergoing deployment of both a temporary stent retriever (e.g., Solitaire [ev3 Neurovascular, Irvine, CA] or Trevo [Stryker, Fremont, CA]) to remove a distal clot and a permanent carotid stent (e.g., Precise Pro Rx [Cordis, Fremont, CA] or Carotid Wall [Boston Scientific, Boston, MA]) to maintain the patency of an underlying stenotic or dissected ICA.²²⁻²⁸ With recent data showing the effectiveness of mechanical

From the *Duke University Hospitals, Department of Neurosurgery, Durham, North Carolina; and †Duke University Hospitals, Department of Radiology, Division of Interventional Radiology, Durham, North Carolina.

Received October 7, 2016; revision received January 25, 2017; accepted February 9, 2017.

Address correspondence to Mary In-Ping Huang Cobb, MD, Duke University Medical Center, Box 3807, Durham, NC 27701. E-mail: maryih.cobb@duke.edu.

1052-3057/\$ - see front matter

© 2017 National Stroke Association. Published by Elsevier Inc. All rights reserved.

<http://dx.doi.org/10.1016/j.jstrokecerebrovasdis.2017.02.015>

thrombectomy for acute ischemic strokes, it is increasingly important to understand how to manage potential complications associated with these procedures.^{22,29-33} In the setting of tandem occlusions, we describe here the first reported case of a CEA for the retrieval of a Solitaire stent lodged inside a carotid stent after mechanical thrombectomy in the setting of a tandem ICA and MCA stenosis causing an acute ischemic stroke.

Clinical Presentation

A 67-year-old man with a history of hypertension and coronary artery disease, who presented with an acute onset of left hemiparesis, dysarthria, and facial droop (National Institutes of Health Stroke Scale score 16). Computed tomography (CT) of the brain showed no hemorrhage. Intravenous tissue plasminogen activator was administered. CT angiogram showed a right carotid occlusion. Within 6 hours of symptom onset, the patient underwent catheter angiography, which demonstrated an occlusion of the right ICA (cervical segment) (Fig 1). He underwent a balloon-assisted carotid stent angioplasty, which recanalized the ICA. After opening up the ICA, the tandem M1 occlusion was attacked with deployment of a Solitaire stent retriever (ev3 Neurovascular). As the Solitaire stent was withdrawn, it lodged into the tines of the Precise Pro Rx carotid stent (Cordis) (Fig 2). The guide catheter was not passed through the stent. Balloon angioplasty was not attempted because of the difficulty finding the lumen inside both the Solitaire and the Precise stents. Snare retrieval was not performed because of the high risk of perforation of the native vessel

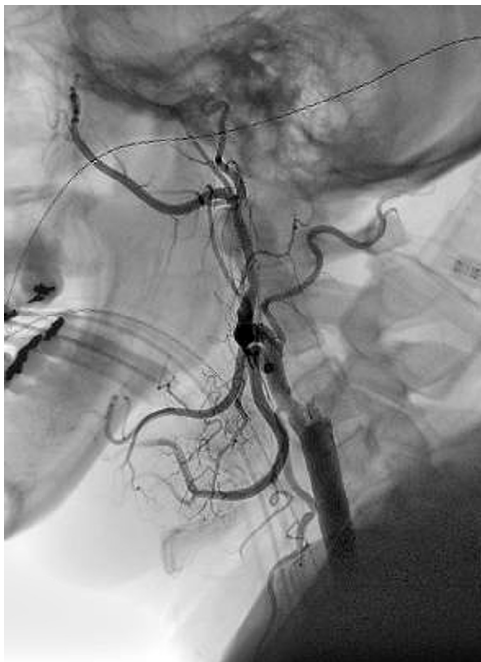


Figure 1. Catheter angiogram showing right internal carotid artery occlusion.

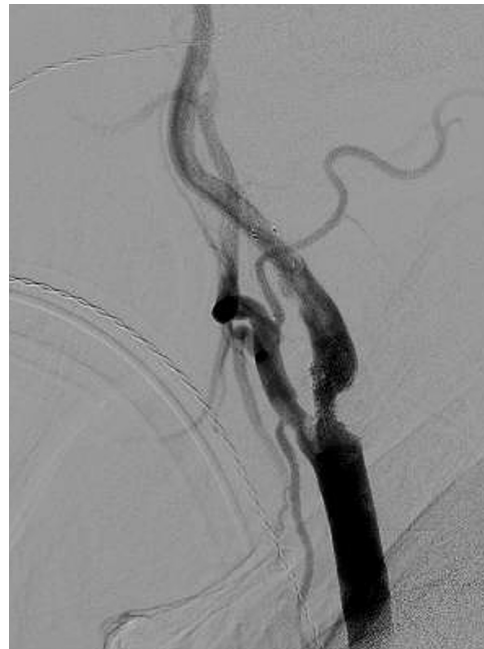


Figure 2. Solitaire stent lodged inside a Precise carotid stent.

on removal. With antegrade flow into the anterior cerebral artery (ACA) and MCA, and time to thrombolysis in cerebral infarction score (TICI) of 2b reperfusion distal to the stent, the procedure was aborted.

The patient was placed on aspirin, clopidogrel (Plavix, Bristol-Myers Squibb/Sanofi Pharmaceuticals Partnership, Bridgewater, NJ), and heparin guttae (gtt) at 600 U an hour. Five days later, after his examination had improved and stabilized (National Institutes of Health Stroke Scale score 12) and before the stents endothelialized, he was brought to the operating room and underwent a CEA for retrieval of the Solitaire stent and Precise carotid stent, and primary reconstruction of the carotid stenosis.

Operative Nuances

The patient's heparin gtt was held before anesthesia induction. Neuromonitoring with somatosensory evoked potentials (SSEPs) and electroencephalogram (EEG) was established to provide evidence of vascular perfusion while the patient was under general endotracheal anesthesia. The standard latero-cervical incision was performed. The carotid sheath was identified by palpation of the arterial pulse. The precise location of the stent inside the carotid artery was confirmed by an intraoperative x-ray. The carotid artery was circumferentially dissected away from the carotid sheath. A temporary straight aneurysm clip was placed on the ICA, just distal to the underlying stent, followed by a Sugita clip (Mizuho, Tokyo, Japan) on the proximal common carotid artery. Two temporary straight aneurysm clips were placed in the superior thyroid artery and external carotid artery. It was important at this point to exclude the stent from these clips.

The length of the CEA was identified and marked, with extension of the incision proximal to the underlying stent. The adventitia of the common carotid artery was opened with an 11 blade scalpel and Potts scissors. Dissection was performed starting at the caudal end of the incision through the layers of the media and intima into the native non-stent portion of the vessel. As the dissection was carried cranially, the carotid stent was revealed, showing apposition to an underlying hard thick layer of calcified plaque and atherosclerosis. The tines of the stent pressed unevenly against the lumen plaque, but there appeared to be no apposition against the native intimal wall. Once the plane of the carotid stent was identified, dissection occurred more superficially, separating the plaque and stent mass from the intima, using a nerve hook and DeBakey forceps.

As the incision and dissection extended rostrally, the retained Solitaire stent was identified inside the carotid stent. With the ICA unclipped and backbleeding, the entire plaque and stent mass was carefully removed caudally en bloc through the native non-stent area (Fig 3). Careful evaluation of the ICA was performed to rule out a dissection flap. Further dissection under heparinized saline irrigation occurred with a ringed curette to fine comb additional atherosclerotic plaque away from the intimal walls. Running sutures with a 6-0 prolene were used to close the endarterectomy from rostral to caudal direction. Before

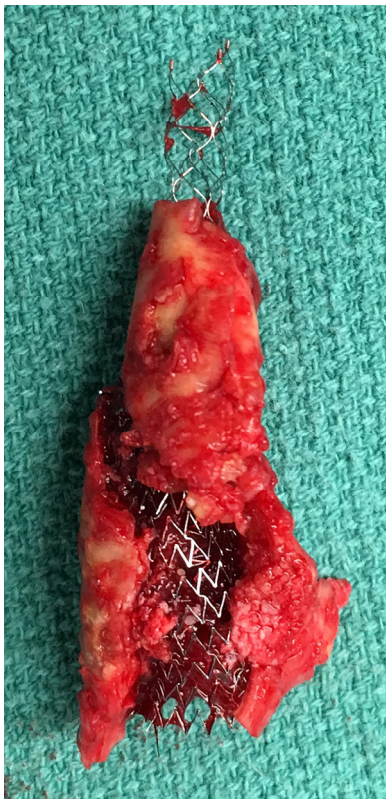

Figure 3. Gross specimen of the Solitaire stent, Precise carotid stent, and calcified atherosclerotic plaque.

the last 2 sutures were placed, the aneurysm clip on the external carotid artery (ECA) was temporarily removed to wash additional debris. Once the sutures were tied, the ECA aneurysm clip was removed, followed by the common carotid artery and ICA.

There were no changes in EEG, SSEPs, or vital signs. Intraoperative angiography was performed showing interval removal of the Solitaire and carotid stent, with antegrade flow into the ACA and MCA. There was a small dissection proximal to the CEA, and the endarterectomy was extended caudally. Care was taken to stitch down the inside of the dissection flap to the native vessel using a double-ended suture. Hemostasis was achieved. Gelfoam was placed on top of the endarterectomy. The carotid sheath was approximated loosely with a couple of 4-0 neurilon sutures, followed by closure of the platysma and skin in layers. A tiny little suction drain was left in overnight. Post-procedural CT angiogram showed non-flow-limiting stenosis proximal to the CEA, and an additional balloon-assisted carotid stent angioplasty was performed without complication.

Discussion

This is the first described case of a CEA as a salvage technique to remove a retained Solitaire stent and carotid stent. Several case studies of salvage CEA procedures have been described for the removal of a carotid stent.²⁻²¹ Prior cases were performed for stent restenoses, migration, fracture, and entrapment of a distal embolic protection device. None were performed in the setting of an acute ischemic stroke. Only a few studies involved a primary repair after removal of the carotid stent, with the assistance of a patch graft being the most common strategy, followed by a reverse saphenous vein bypass (Table 1). In our case, primary repair was achieved safely with the assistance of intraoperative localization by x-ray and angiography, in a patient who remained paralyzed, under general endotracheal anesthesia, with intracranial perfusion monitored by potential changes in EEG and SSEPs.

Surgical Risk of Stent Removal

Surgical removal of an intraluminal stent is uncommon for the primary fear that the stent tines have penetrated the lumen of the vessel walls and endothelialized, making surgical dissection of the stent away from the intima cumbersome and unsafe. Shearing of the stent against the lumen of the native vessels can compromise the integrity of the native vessel, making it difficult for the surgeon to reconstruct the vessel.^{34,35} This could lead to the need for a patch graft to assist in repair, or more complicated salvage techniques such as vessel bypass, proximal vessel occlusion, or vessel trapping.^{11,15}

In this case, the stent was intertwined in the plaque. Our exposure was extra long to allow for exposure of

Table 1. Review of carotid endarterectomy cases for removal of diversion of stents

Author	No. of cases	Technique	Results
Vale et al 1997 ²	1	Stent removal and CEA	No complications
Johnson et al 1997 ³	1	Reversed saphenous vein bypass	No complications
Calvey and Gough 1998 ⁴	1	Reversed saphenous vein bypass	No complications
Reedy et al 2000 ⁵	2	Stent removal and CEA with patch	No complications
Leger et al 2001 ⁶	2	PTFE bypass	No complications
Owens et al 2002 ⁷	6	Stent removal and CEA (1) Thrombolysis and stent removal with CEA (1) Reversed saphenous vein bypass (2) ICA to ECA transposition	1 case of reversed vein bypass thrombosis
de Borst et al 2003 ⁸	4	Stent removal with CEA and patch	Hemiparesis (1) No complications (3)
Akin et al 2004 ⁹	1	Stent removal with CEA and patch	No complication
Setacci et al 2005 ¹⁰	3	Stent removal and CEA with patch	No complication
de Vries et al 2005 ¹¹	1	Stent removal and CEA	No complications
Raithel 2005 ¹²	8	Stent removal and CEA with patch (6) or graft (2) Stent removal and CEA (1)	No complications
Faggioli et al 2007 ¹³	5	Stent removal and CEA with patch (2) Reversed saphenous vein bypass (2) Stent removal and CEA (primary repair) (1)	No complications
Jimenez et al 2008 ¹⁴	1	Stent removal with CEA and patch	No complication
Valibhoy et al 2007 ¹⁵	1	Stent removal with CEA and patch	No complication
King et al 2009 ¹⁶	1	Stent removal with CEA and patch	No complication
Soylu and Bayazit 2011 ¹⁷	1	Stent removal and CEA with patch	No complication
Reichmann et al 2011 ¹⁸	15	Stent removal and CEA with patch (13)	Aphasia, hemiparesis (1) Neck hematoma (2) No complications (12)
Gonzalez et al 2011 ¹⁹	3	Stent removal and CEA with patch (3)	No complication
Jost et al 2012 ²⁰	4	Stent removal and CEA with patch (3) Stent removal and CEA (1)	Neck hematoma (1) Aphasia, dysphagia (1) No complications (2)
Zheng et al 2013 ²¹	1	Stent removal and CEA	No complication

Abbreviations: CEA, carotid endarterectomy; ECA, external carotid artery; ICA, internal carotid artery; PTFE, polytetrafluoroethylene.

the native vessel above and below the stent. Following this native plane between the plaque and the lumen in an area with native vessel was important before dissection along the stent and plaque. Care was taken in both cases to remove the stent through an exposed native vessel segment to avoid penetration of thinned native vessel walls. Prior studies had described difficulty cutting the artery because of the metallic stent.² In our case, there was no need to cut the Precise stent or Solitaire stent because both were deep, intertwined inside the plaque. Repair and reconstruction need to occur quickly with proximal control achieved at the compromise of limited intracranial perfusion through collateral vessels.

Alternative Treatments

Alternatives described elsewhere for carotid restenosis including percutaneous balloon angioplasty with or without carotid stent angioplasty were not available to our patient because of the risk of crushing the poorly positioned

Solitaire stent through the vessel walls.³⁶ Finding the true lumen inside an obliquely positioned Solitaire stent would be virtually impossible under fluoroscopic guidance. Further, the relatively small size of the stent retriever to the carotid stent would lead to poor apposition, even with the stent fully expanded with balloon angioplasty.

Deployment of a Snare device to retrieve the Solitaire stent into a large proximal catheter was not performed because of the concern for unpredictable dissection or perforation of the native vessel. Navigating a Snare stent across the lumen of the carotid stent and attaching it to the Solitaire stent without catching the carotid stent would be challenging. Further, if the Snare device were to attach to the Solitaire stent, the consequent movement of the carotid stent as the Snare-Solitaire stent unit was withdrawn would be unpredictable.

Although not performed on this patient, transcranial cerebral Dopplers can be performed to see if there is a shower of emboli, with indication to treat more urgently if they are persistent with an associated change

in neurologic examination. Complete vessel takedown is another alternative; however, in this patient with an acute ischemic stroke, it was evident that he was dependent on vascularization from the right ICA.

Alternatives to Carotid Stent Placement in Setting of Acute Tandem Occlusion

There is still ongoing debate over the appropriate time to place a carotid stent after a mechanical thrombectomy in patients with tandem occlusions. Some advocate for balloon angioplasty of the carotid stent stenosis, followed by removal of a distal occlusion with a stent retriever. A few days later, after the patient is clinically stable and loaded with dual antiplatelet agents, the patient will return to the angiography suite for placement of a carotid stent. However, with a tight stenosis causing an acute distal occlusion, there is interval risk of a re-occlusion without more urgently addressing the underlying cause.

Further, the Penumbra aspiration device may serve as an alternative for mechanical thrombectomy without the use of a stent retriever.³⁷ This technique involves no placement of a stent within a stent; however, most of the core acute ischemic stroke trials showing efficacy involved use of flow arrest with the proximal balloon catheter and a distal stent retriever such as Solitaire or Trevo.^{22,29-33}

Conclusion

In conclusion, we describe here the first study to date of surgical removal of a stent retriever lodged inside a carotid stent, followed by a primary vessel reconstruction and repair. Although rare, understanding the open surgical management of this complication is important to minimize the risk of stroke and dissection. In the landscape of increasing rates of endovascular mechanical thrombectomy and carotid stent angioplasty in patients with tandem ICA and MCA occlusions, we hope this report provides additional insight on how to safely manage this clinical scenario.

References

1. CMS, Decision Memo for Carotid Artery Stenting (CAG-00085R). Centers for Medicare and Medicaid Services. Available at: www.cms.gov. Accessed 24 November 2015.
2. Vale FL, Fisher WS 3rd, Jordan WD Jr, et al. Carotid endarterectomy performed after progressive carotid stenosis following angioplasty and stent placement. *Case Report J Neurosurg* 1997;87:940-943.
3. Johnson SP, Fujitani RM, Leyendecker JR, et al. Stent deformation and intimal hyperplasia complicating treatment of a post-carotid endarterectomy intimal flap with a Palmaz stent. *J Vasc Surg* 1997;25:764-768.
4. Calvey T, Gough MJ. A late complication of internal carotid artery stenting. *J Vasc Surg* 1998;27:753-755.
5. Reedy FM, Colonna M, Genovese V, et al. Successful surgical treatment of two patients with restenosis after previous stenting of the carotid artery. *Eur J Vasc Endovasc Surg* 2000;20:99-101.
6. Leger AR, Neale M, Harris JP. Poor durability of carotid angioplasty and stenting for treatment of recurrent artery stenosis after carotid endarterectomy: an institutional experience. *J Vasc Surg* 2001;33:1008-1014.
7. Owens EL, Kumins NH, Bergan JJ, et al. Surgical management of acute complications and critical restenosis following carotid artery stenting. *Ann Vasc Surg* 2002;16:168-175.
8. de Borst GJ, Ackerstaff RGA, Mauser HW, et al. Operative management of carotid artery in-stent restenosis: first experiences and duplex follow-up. *Eur J Vasc Endovasc Surg* 2003;26:137-140.
9. Akin E, Knobloch K, Pichlmaier M, et al. In-stent restenosis after carotid stenting necessitating open carotid surgical repair. *Eur J Cardiothorac Surg* 2004;26:442-443.
10. Setacci C, De Donato G, Setacci F, et al. Surgical management of acute carotid thrombosis after carotid stenting: a report of three cases. *J Vasc Surg* 2005;42:993-996.
11. de Vries JP, Meijer RW, van den Berg JC, et al. Stent fracture after endoluminal repair of a carotid artery pseudoaneurysm. *J Endovasc Ther* 2005;12:612-615.
12. Raithel D. Complications of carotid artery stenting. *J Cardiovasc Surg (Torino)* 2005;46:261-265.
13. Faggioli GL, Ferri M, Rossi C, et al. Carotid stent failure: results of surgical rescue. *Eur J Vasc Endovasc Surg* 2007;33:58-61.
14. Jimenez JC, Moore WS, Lawrence PF, et al. Technical strategies for recurrent carotid stenosis following angioplasty and stenting. *Ann Vasc Surg* 2008;22:179-184.
15. Valibhoy AR, Mwipatayi BP, Sieunarine K. Fracture of a carotid stent: an unexpected complication. *J Vasc Surg* 2007;45:603-606.
16. King BN, Scher LA, Lipsitz EC. Refractory in-stent restenosis following carotid artery stenting: a case report and review of operative management. *Vasc Endovascular Surg* 2009;43:306-311.
17. Soyulu L, Bayazit M. Carotid endarterectomy performed after carotid artery restenosis following stent migration. *Ann Vasc Surg* 2011;25.
18. Reichmann BL, van Laanen JH, de Vries JP, et al. Carotid endarterectomy for treatment of in-stent restenosis after carotid angioplasty and stenting. *J Vasc Surg* 2011;54:87-92.
19. Gonzalez A, Drummond M, McCord S, et al. Carotid endarterectomy for treatment of in-stent restenosis. *J Vasc Surg* 2011;54:1167-1169.
20. Jost D, Unmuth SJ, Meissner H, et al. Surgical treatment of carotid in-stent-restenosis: novel strategy and current management. *Thorac Cardiovasc Surg* 2012;60:517-524.
21. Zheng J, Liu L, Cao Y, et al. Carotid endarterectomy with stent removal in management of in-stent restenosis: a safe, feasible, and effective technique. *Eur J Vasc Endovasc Surg* 2014;47:8-12.
22. Berkhemer OA, Franssen PS, Beumer D, et al. A randomized trial of intraarterial treatment for acute ischemic stroke. *N Engl J Med* 2015;372:11-20.
23. Kappelhof M, Marquering HA, Berkhemer OA, et al. Intra-arterial treatment of patients with acute ischemic stroke and internal carotid artery occlusion: a literature review. *J Neurointerv Surg* 2015;7:8-15.
24. Cohen JE, Gomori JM, Rajz G, et al. Extracranial carotid artery stenting followed by intracranial stent-based

- thrombectomy for acute tandem occlusive disease. *J Neurointerv Surg* 2015;7:412-417.
25. Maurer CJ, Joachimski F, Berlis A. Two in one: endovascular treatment of acute tandem occlusions in the anterior circulation. *Clin Neuroradiol* 2015;25:397-402.
 26. Lescher S, Czeppan K, Porto L, et al. Acute stroke and obstruction of the extracranial carotid artery combined with intracranial tandem occlusion: results of interventional revascularization. *Cardiovascular and interventional radiology*. *Cardiovasc Intervent Radiol* 2015;38:304-313.
 27. Dababneh H, Bashir A, Hussain M, et al. Endovascular treatment of tandem internal carotid and middle cerebral artery occlusions. *J Vasc Interv Neurol* 2014;7:26-31.
 28. Stampfl S, Ringleb PA, Mohlenbruch M, et al. Emergency cervical internal carotid artery stenting in combination with intracranial thrombectomy in acute stroke. *AJNR Am J Neuroradiol* 2014;35:741-746.
 29. Campbell BC, Mitchell PJ, Kleinig TJ, et al. Endovascular therapy for ischemic stroke with perfusion-imaging selection. *N Engl J Med* 2015;372:1009-1018.
 30. Goyal M, Demchuk AM, Menon BK, et al. Randomized assessment of rapid endovascular treatment of ischemic stroke. *N Engl J Med* 2015;372:1019-1030.
 31. Saver JL, Goyal M, Bonafe A, et al. Solitaire™ with the Intention for Thrombectomy as Primary Endovascular Treatment for Acute Ischemic Stroke (SWIFT PRIME) trial: protocol for a randomized, controlled, multicenter study comparing the Solitaire revascularization device with IV tPA with IV tPA alone in acute ischemic stroke. *Int J Stroke* 2015;10:439-448.
 32. Saver JL, Goyal M, Bonafe A, et al. Stent-retriever thrombectomy after intravenous t-PA vs. t-PA alone in stroke. *N Engl J Med* 2015;372:2285-2295.
 33. Jovin TG, Chamorro A, Cobo E, et al. REVASCAT trial investigators: thrombectomy within 8 hours after symptom onset in ischemic stroke. *N Engl J Med* 2015;372:2296-2306.
 34. Gersak B, Gabrijelcic T. Successful surgical removal of partially expanded Palmaz stent from external iliac artery. *Panminerva Med* 1995;37:92-94.
 35. Dwivedi AJ, Sharma D, Parks K. Management of a misplaced endovascular stent in pulmonary artery. *Am Surg* 2015;81:E151-E153.
 36. Di Gioia G, Campanale CM, Mega S, et al. Percutaneous treatment of recurrent in-stent restenosis of carotid artery stenting: a case report and state-of-the-art review. *Am J Case Rep* 2015;16:558-562.
 37. Hussain SI, Zaidat OO, Fitzsimmons BF. The Penumbra system for mechanical thrombectomy in endovascular acute ischemic stroke therapy. *Neurology* 2012;79(13 Suppl 1):S135-S141.