



Letter to the Editor

Hemichorea-hemiballismus in the setting of posterolateral putaminal lesion and treatment with topiramate



Keywords:

Hemichorea-hemiballismus

Topiramate

Putamen

Pathophysiology

Letter to Editor

A-60 year old female with medical history of hypertension, diabetes mellitus (with good glycemic control) and hyperlipidemia suffered from right sided involuntary movements of upper and lower extremities progressing over the past 4 years (Video 1). She had had an ischemic stroke characterized with right sided weakness 8 years ago. Motor examinations revealed 4+/5 motor weakness solely in the right triceps muscle and her walking was antalgic due to gonarthrosis. Cranial MRI showed chronic ischemic lesion in the left thalamic and posterior putamen (Fig. 1). With the diagnosis of vascular hemichorea hemiballismus (HC/HB), oral haloperidol was started up to the 2×5 mg dosage. However, on the second week evaluation on haloperidol treatment, not any improvement was achieved. Hence, haloperidol was discontinued and oral topiramate was started (up to 2×50 mg). On follow-up evaluation, three weeks later, a moderate response was achieved which was prominent in the lower extremity movements (Video 2).

Discussions

Hemiballismus can be defined as high amplitude, violent and conspicuous proximal involvement of the extremities localized in the one side of body and hemichorea can be defined as involuntary, non-patterned and random appearing, lateralized movements. The etiological causes of HC/HB syndrome include most commonly stroke, neoplasm, systemic lupus erythematosus, hyperglycemic hyperosmolar non-ketotic state, Wilson's disease, and thyrotoxicosis [1].

In contrast to the classical knowledge regarding the role of subthalamic nucleus in HC/HB, the majority of patients with vascular causes have lesions outside the subthalamic nucleus [2]. In literature, other regions including cortex, caudate, putamen, thalamus, and brain stem have been reported to be in association as causative lesions of HC/HB [3,4]. Based on these controversies in literature, Lagaïere et al. conducted an impressive study, using lesion network mapping method, to reveal disruption in a possible, common

functional network underlying this clinical manifestation [5]. As a result, they concluded that lesions occurred in regions commonly connected to the posterolateral putamen. Accordingly, our case constitutes a smart illustration of case with HC/HB associated with putaminal lesion. An interesting point in our patient may be that the temporal relationship of stroke and clinical manifestations of HC/HB conflict. One explanation may be that our evaluation was retrospective and a possible lacunar stroke that might affect the posterior putaminal region, at the time of the onset of HCHB cannot be ruled out. On the other hand, the patient's symptoms had worsened progressively over the last 4 years which rather can be attributed to a dynamic alterations, advancing in the interval period, in some compensatory changes to focal disruptions. Nonetheless, this hypothesis remains to be elucidated in future studies of large case series.

Another remarkable point was that not a response was taken by haloperidol, whereas topiramate resulted in a significant amelioration in the dosage of 50 mg twice daily, nearly total at lower limb. Although the exact mechanism is unclear, it is assumed that TPM might be effective via enhancement in GABAergic activity in the indirect pathway, which has been suggested to be reduced in HC/HB caused by striatal lesions [6]. In literature, the efficiency of topiramate in HC/HB has been emphasized only in the limited number of case series [7–9]. However, this report represents a crucial and impressive sample from the perspective of efficiency of topiramate in HC/HB. Furthermore, it also represents a rare report illustrating posterolateral putaminal lesion and associated HC/HB, supporting the recently reports pointing out the role of posterolateral putamen in HC/HB pathophysiology [5]. Lagaïere et al. tried to explain this result in the background of the anatomical and functional role of posterolateral putamen within the basal ganglia-thalamocortical motor loop [5,10]. At this point, considering the markedly efficiency of topiramate in our case with MRI showing posterolateral putaminal lesion, it can be speculated that specifically GABAergic indirect pathways from putamen to GP externa may be responsible from this clinical picture of HC/HB. Future studies, addressing the pathophysiological pathways of posterolateral putamen using treatment based approaches may give substantial contributions to the unknown aspects of HC/HB.

Supplementary data to this article can be found online at <http://dx.doi.org/10.1016/j.jns.2017.02.031>.

Conflicts of interest

None.

Acknowledgement

None.

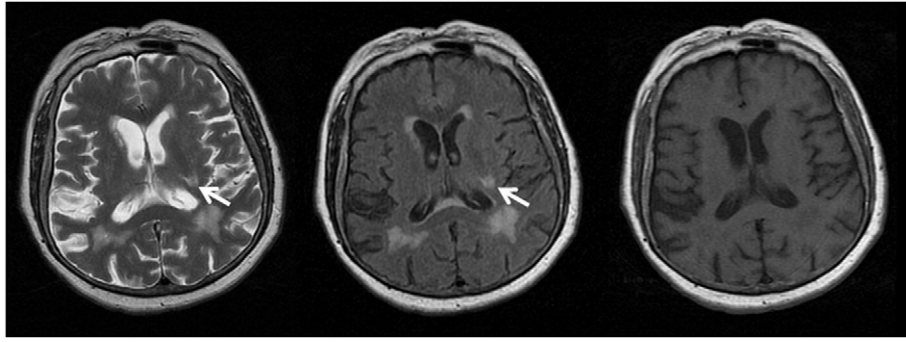


Fig. 1. Cranial MRI showing chronic lacunar lesion in the posterior putaminal region.

References

- [1] S. Padmanabhan, A.S. Zagami, A.M. Poynten, A case of hemichorea-hemiballismus due to nonketotic hyperglycemia, *Diabetes Care* 36 (4) (2013) e55–e56.
- [2] F. Ghika-Schmid, et al., Hyperkinetic movement disorders during and after acute stroke: the Lausanne Stroke Registry, *J. Neurol. Sci.* 146 (2) (1997) 109–116.
- [3] M. Kawamura, N. Takahashi, K. Hirayama, Hemichorea and its denial in a case of caudate infarction diagnosed by magnetic resonance imaging, *J. Neurol. Neurosurg. Psychiatry* 51 (4) (1988) 590–591.
- [4] S.J. Chung, et al., Hemichorea after stroke: clinical-radiological correlation, *J. Neurol.* 251 (6) (2004) 725–729.
- [5] S. Laganieri, A.D. Boes, M.D. Fox, Network localization of hemichorea-hemiballismus, *Neurology* 86 (23) (2016) 2187–2195.
- [6] T. Hashimoto, et al., Neuronal activity in the globus pallidus in chorea caused by striatal lacunar infarction, *Ann. Neurol.* 50 (4) (2001) 528–531.
- [7] E.M. Gatto, et al., Vascular hemichorea/hemiballism and topiramate, *Mov. Disord.* 19 (7) (2004) 836–838.
- [8] E. Driver-Dunckley, V.G. Evidente, Hemichorea-hemiballismus may respond to topiramate, *Clin. Neuropharmacol.* 28 (3) (2005) 142–144.
- [9] T.A. Zesiewicz, K.L. Sullivan, R.A. Hauser, Vascular hemichorea/hemiballismus and topiramate, *Mov. Disord.* 21 (4) (2006) 581 (author reply 582).
- [10] S. Lehericy, et al., Diffusion tensor fiber tracking shows distinct corticostriatal circuits in humans, *Ann. Neurol.* 55 (4) (2004) 522–529.

Halil Onder

Yozgat State Hospital, Department of Neurology, Yozgat, Turkey

E-mail address: halilonder@yahoo.com

20 December 2016