

Journal of Dual Diagnosis

research and practice in substance abuse comorbidity

ISSN: 1550-4263 (Print) 1550-4271 (Online) Journal homepage: <http://www.tandfonline.com/loi/wjdd20>

Autoimmune-Mediated Psychosis: A Case of Susac Syndrome in a Drug User

Pablo Barrio MD, Mercè Balcells PhD, Delón La Puma MD & Carles Gaig PhD

To cite this article: Pablo Barrio MD, Mercè Balcells PhD, Delón La Puma MD & Carles Gaig PhD (2017): Autoimmune-Mediated Psychosis: A Case of Susac Syndrome in a Drug User, Journal of Dual Diagnosis, DOI: [10.1080/15504263.2017.1296212](https://doi.org/10.1080/15504263.2017.1296212)

To link to this article: <http://dx.doi.org/10.1080/15504263.2017.1296212>



Published online: 03 Apr 2017.



Submit your article to this journal [↗](#)



View related articles [↗](#)



View Crossmark data [↗](#)

Autoimmune-Mediated Psychosis: A Case of Susac Syndrome in a Drug User

Pablo Barrio, MD^a, Mercè Balcells, PhD^a, Delón La Puma, MD^b, and Carles Gaig, PhD^b

^aAddictive Behaviours Unit, Clinical Neuroscience Institute, Clinic Hospital of Barcelona, Barcelona, Spain; ^bNeurology Department, Clinical Neuroscience Institute, Clinic Hospital of Barcelona, Barcelona, Spain

ABSTRACT

Objective: Susac syndrome, a rare disorder, is thought to be mediated by autoantibodies. One of the potential targets of these autoantibodies could be an antigen in the microvessels of the brain, the retina, and the inner ear leading to central nervous system (CNS) alterations, visual disturbances, and hearing deficits. Our aim is to expand clinicians' diagnostic options when facing psychosis due to medical conditions. **Methods:** A case report was conducted for this study. **Results:** This paper reports the case of a young male drug user who presented with psychosis, confusion and CNS vasculitis. First deemed to be drug-induced CNS vasculitis, it was finally diagnosed as Susac syndrome. **Conclusions:** Although an infrequent entity, Susac syndrome should remain an option in the differential diagnosis of several neurological and psychiatric presentations.

KEYWORDS

Susac syndrome; CNS vasculitis; drug use; cannabis dependence

This article reports the case of a 23-year-old man with cannabis dependence and psychostimulant abuse who experienced an episode of psychosis and delirium due to central nervous system (CNS) vasculitis. Initially deemed to be drug-induced CNS vasculitis (a rare but well-described entity), it was finally determined to be a case of Susac syndrome, a rare autoimmune disorder affecting the microvessels of the CNS, the retina, and the inner ear in the form of microvessel vasculitic occlusion (Greco et al., 2014).

Methods

For this study we conducted a case report. Consent was obtained from the patient and his family, and approval was granted from the Institutional Review Board of the Clinic Hospital of Barcelona.

Results

The patient was a 23-year-old man with a three-year history of cannabis dependence and psychostimulant abuse according to the *Diagnostic and Statistical manual of Mental Disorders*, 4th edition. There was no family history of psychiatric or autoimmune diseases. Before admission, the patient reported delusional beliefs of paranoid content and auditory hallucinations. Due to agitation and disorganized speech, the patient was admitted into the psychiatric ward. The initial evaluation revealed a psychotic state, with no focal

neurological anomalies. A computerized tomography (CT) scan was completed and showed no CNS anomalies, and a blood analysis showed no significant abnormalities. The urine drug screen result was only positive for cannabis. Haloperidol 5 mg daily was initially prescribed and, after a few days, the patient became disorganized and intermittently sleepy, and visual hallucinations appeared. Also, clear waxing and waning in his alertness was observed, indicating the development of delirium. Collaboration with the neurology department was requested two days after admission into the psychiatry ward.

Despite the patient's history, substance intoxication and abstinence were ruled out. According to the patient's inner circle, the last drug use was one week prior to admission. Results of all toxicological analyses were negative except screening for cannabis, and none of the symptoms resembled a withdrawal state. A lumbar puncture (LP) and CNS magnetic resonance imaging (MRI) were performed to expand the diagnostic process. The LP results showed signs of inflammation, with slightly elevated protein levels (238 mg/dL), a glucose concentration of 69 mg/dL, and 10 lymphocytic cells/ μ L. Results of tests searching for an infectious origin were negative, including those for cytomegalovirus, Epstein-Barr virus, parvovirus, and sexually transmitted infection. The MRI showed, on T2-weighted images, multiple hyperintense brain lesions affecting the cortex and white matter, basal ganglia, and brainstem, some with contrast

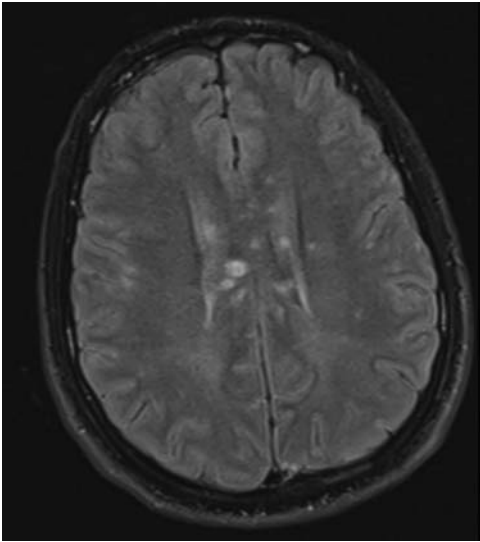


Figure 1. Flair secuencia/axial: Multiple hyperintense lesions with involvement of white and grey matter. Most of the lesions are localized in corpus callosum.

enhancement. Most of these lesions were localized in the corpus callosum. Diffusion-weighted images showed restriction in some of these lesions, pointing to an ischemic process. T1-weighted images showed multiple hypointense lesions in the corpus callosum. Fundoscopy showed anterior pole ischemic lesions involving the macula of both eyes (images not available). Taken together, the results suggested the presence of CNS vasculitis, CNS lymphoma, or a rare entity called chronic lymphocytic inflammation with pontine perivascular enhancement responsive to steroids (CLIPPERS). **Figures 1 to 3** show the MRI images.

Body positron emission tomography (PET) was conducted to rule out neurological paraneoplastic encephalitis, including anti-Ma2-mediated encephalitis, which is characterized by limbic encephalitis with diencephalic and brainstem involvement normally associated with

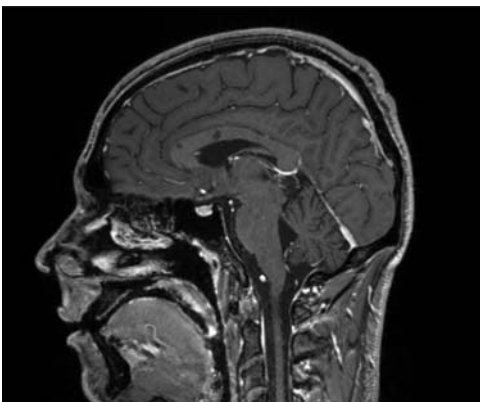


Figure 2. T1 secuencia: Multiple hypointense lesions in corpus callosum.

germinal tumors. Findings of both the PET and the anti-Ma2 antibodies (directed toward intracellular antigens expressed in tumors and neurons and highly specific of this syndrome) were negative. No other autoantibodies investigated were found, including antinuclear antibodies, antimitochondrial antibodies, anti-smooth muscle antibodies, anti-LKM antibodies, anti-DNA antibodies, and ANCA-antibodies.

Once all other possibilities were ruled out, a diagnosis of CNS vasculitis due to drug use was established. Although an unusual phenomenon, there are several reports describing vasculitic processes of the CNS triggered or caused by drug use (Graf, 2013; Buxton & McConachie, 2000; Desbois & Cacoub, 2013; Peyrot et al., 2007).

Prednisone 1 mg/kg/day was started adjunctive to cyclophosphamide 50 mg per day. A new MRI showed signs of progression, with new ischemic lesions, and as a result a bolus of cyclophosphamide was administered. The patient kept receiving haloperidol 2 mg each night for behavior control and sleep facilitation. Once medication started, the psychopathological state of the patient improved slowly. Paranoid delusions were not observed any longer, although cognitive deficits and confusion were still intermittently present.

Finally, before discharge to a convalescence center, a loss of higher visual field was detected in a routine neurological examination. The ophthalmoscopy revealed microvessel vasculitis of the lower left macular artery and the diagnosis of Susac syndrome was finally established. Auditory evoked potentials were conducted with no signs of impairment.

The review of the patient's medical records one year after the diagnosis was made revealed significant improvements in both his mental and cognitive state as well as on successive MRI, where a decrease in the vasculitic lesions was observed. MRI also revealed the appearance of hypoacusia, which could not be evaluated because the patient did not attend his scheduled audiometry. Cyclophosphamide and haloperidol were discontinued before the patient was discharged from the hospital, and prednisone was slowly tapered during the following months.

Discussion

This article reports a case of psychosis due to Susac syndrome, which is a rare disorder of unknown etiology thought to be mediated by autoantibodies, possibly against an unknown antigen in the microvessels of the brain, the retina, and the inner ear (Greco et al., 2014), although this hypothesis remains unproven. Microvessel occlusion accounts for its characteristic findings: CNS

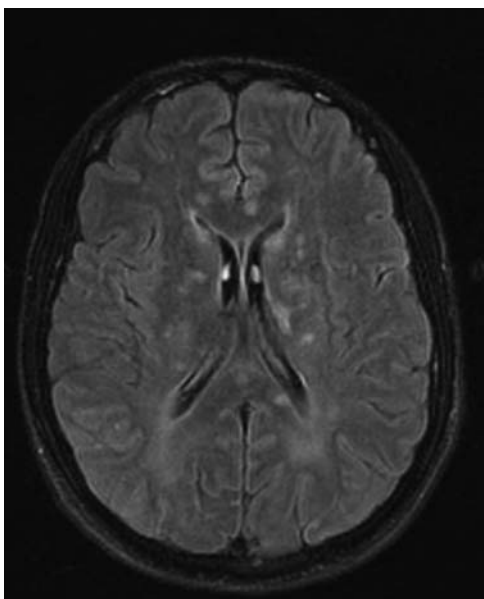


Figure 3. Flair sequence/axial: Multiple hyperintense lesions with involvement of white and grey matter.

alterations, visual disturbances, and hearing deficits. A debut with only one or two symptoms is common (Dörr, Krautwald, & Wildemann, 2013). CNS alterations might take the form of several psychiatric symptoms. In a recent review (Dörr et al., 2013), 75% of the cases showed signs of encephalopathy, including delirium, as well as other psychiatric symptoms such as emotional disturbances, behavioral changes, or psychosis.

A growing body of evidence now exists linking autoimmune diseases with psychotic disorders (Benros, Eaton, & Mortensen, 2014), suggesting that some of the autoantibodies or cytokines generated might be directed against key areas in the development of psychotic states. The specific antigen of Susac syndrome remains unknown; therefore, no specific auto antibodies can be found in this disease. Nonetheless, clear CNS involvement was observed on MRI.

Also, at some point, drug use was considered the cause of the vasculitis. Although an infrequent phenomenon, drug-induced vasculitis has been previously reported in the literature with multiple substances implicated such as cocaine, amphetamines, or cannabis (Graf, 2013; Buxton & McConachie, 2000; Desbois & Cacoub, 2013; Peyrot et al., 2007). What remains unknown is whether drug use could have precipitated the appearance of Susac syndrome or whether it might have played an interactive role between the disease and the precipitation of the psychotic state.

We expect this case to help clinicians facing the difficult differential diagnosis of organic psychosis. It also raises the question about how often and how deep clinicians should search for medical conditions when facing a psychotic disorder. In this case, the appearance of confusional signs triggered the diagnostic process; however, had they not appeared, the disease would have probably gone undetected. The only tentative answer that might be drawn from this case is that a persistent and careful clinical evaluation remains the basis for a good and thorough diagnostic investigation.

Acknowledgments

The authors would like to thank the patient and his family for their permission to report this case.

Disclosures

None of the authors has any financial statement or conflict of interest to report or any other additional income source.

References

- Benros, M. E., Eaton, W. W., & Mortensen, P. B. (2014). The epidemiologic evidence linking autoimmune diseases and psychosis. *Biological Psychiatry*, 75(4), 300–306. doi:10.1016/j.biopsych.2013.09.023
- Buxton, N., & McConachie, N. S. (2000). Amphetamine abuse and intracranial haemorrhage. *Journal of the Royal Society of Medicine*, 93(9), 472–477.
- Desbois, A. C., & Cacoub, P. (2013). Cannabis-associated arterial disease. *Annals of Vascular Surgery*, 27(7), 996–1005. doi:10.1016/j.avsg.2013.01.002
- Dörr, J., Krautwald, S., & Wildemann, B. (2013). Characteristics of Susac syndrome: A review of all reported cases. *Nature Reviews Neurology*, 9(6), 307–316. doi:10.1038/nrneurol.2013.82
- Graf, J. (2013). Rheumatic manifestations of cocaine use. *Current Opinion in Rheumatology*, 25(1), 50–55. doi:10.1097/BOR.0b013e32835b4449
- Greco, A., De Virgilio, A., Gallo, A., Fusconi, M., Turchetta, R., Tombolini, M., ... de Vicentiis, M. (2014). Susac's syndrome: Pathogenesis, clinical variants and treatment approaches. *Autoimmunity Reviews*, 13(8), 814–821. doi:10.1016/j.autrev.2014.04.004
- Peyrot, I., Garsaud, A. M., Saint-Cyr, I., Quitman, O., Sanchez, B., & Quist, D. (2007). Cannabis arteritis: A new case report and a review of literature. *Journal of European Academy of Dermatology Venereology*, 21(3), 388–391. doi:10.1111/j.1468-3083.2006.01947.x