


## Not all intermittent shakings are epilepsy

Cindy Tiseo<sup>1</sup>  · Raffaele Ornello<sup>1</sup> · Diana Degan<sup>1</sup> · Francesca Notturmo<sup>1</sup>

Received: 23 February 2017 / Accepted: 3 April 2017  
© SIMI 2017

**Keywords** Limb-shaking · Carotid artery stenosis · Haemodynamic transient ischemic attack · Involuntary movements

A 74-year-old man with a past medical history of arterial hypertension, dyslipidaemia, hyperuricemia, impaired glucose tolerance, and ex-smoker was referred to our Hospital complaining of involuntary movements affecting the left limbs. The patient reported the onset ten days prior of left limb movements described as shaking and trembling, lasting from a few seconds to three minutes, and occurring up to 5 times per day. Consciousness, speech, sensory, and motor functions were reported as normal, during and between the attacks. The episodes mainly occurred after standing up from the supine position or during a prolonged laughter.

On arrival to the Emergency Department, the patient was alert, oriented to persons, time and place, and able to perform simple and complex commands. Residual slight right facial drop following a past right facial nerve peripheral palsy was present. No motor or sensory deficits were present. Balance, gait, and coordination were normal. Deep tendon reflexes were normal with bilateral flexor plantar response.

Computed tomography (CT) of the brain was negative for space occupying lesions and recent ischaemic or haemorrhagic lesions. Calcifications of the carotid and vertebral-basilar arteries were found. Arterial blood

pressure was 110/60 mmHg, heart rate was 84 beats per minute, capillary blood glucose level was 133 mg/dL, oxygen saturation was 97% in breathing room air, body temperature was normal. No orthostatic hypotension was found. The electrocardiogram showed sinus rhythm with sporadic ectopic ventricular beats. Creatinine level was 1.41 mg/dL (normal range 0.7–1.2 mg/dL), urea 75 mg/dL (normal range 10–50 mg/dL), and total cholesterol 240 mg/dL. The white-cell count, haematocrit, haemoglobin level, platelet count, prothrombin time, international normalised ratio, and electrolytes were normal.

The patient was transferred to our Neurology Department to rule out partial motor epilepsy. At physical examination a pitched, intense, holosystolic bruit (not transmitted from the heart) could be heard over the right carotid artery. Involuntary movements were observed to be contralateral to the right carotid bruit, to occur when the patient was rising to stand or during a prolonged laughter, and their clinical features were not classifiable as typical partial motor seizures (Jacksonian march was absent; left facial muscles were not involved), leading to a different diagnostic hypothesis. An electroencephalogram (EEG) and a brain magnetic resonance imaging (MRI) were planned together with investigations aimed to identify the possible vascular origin of symptoms.

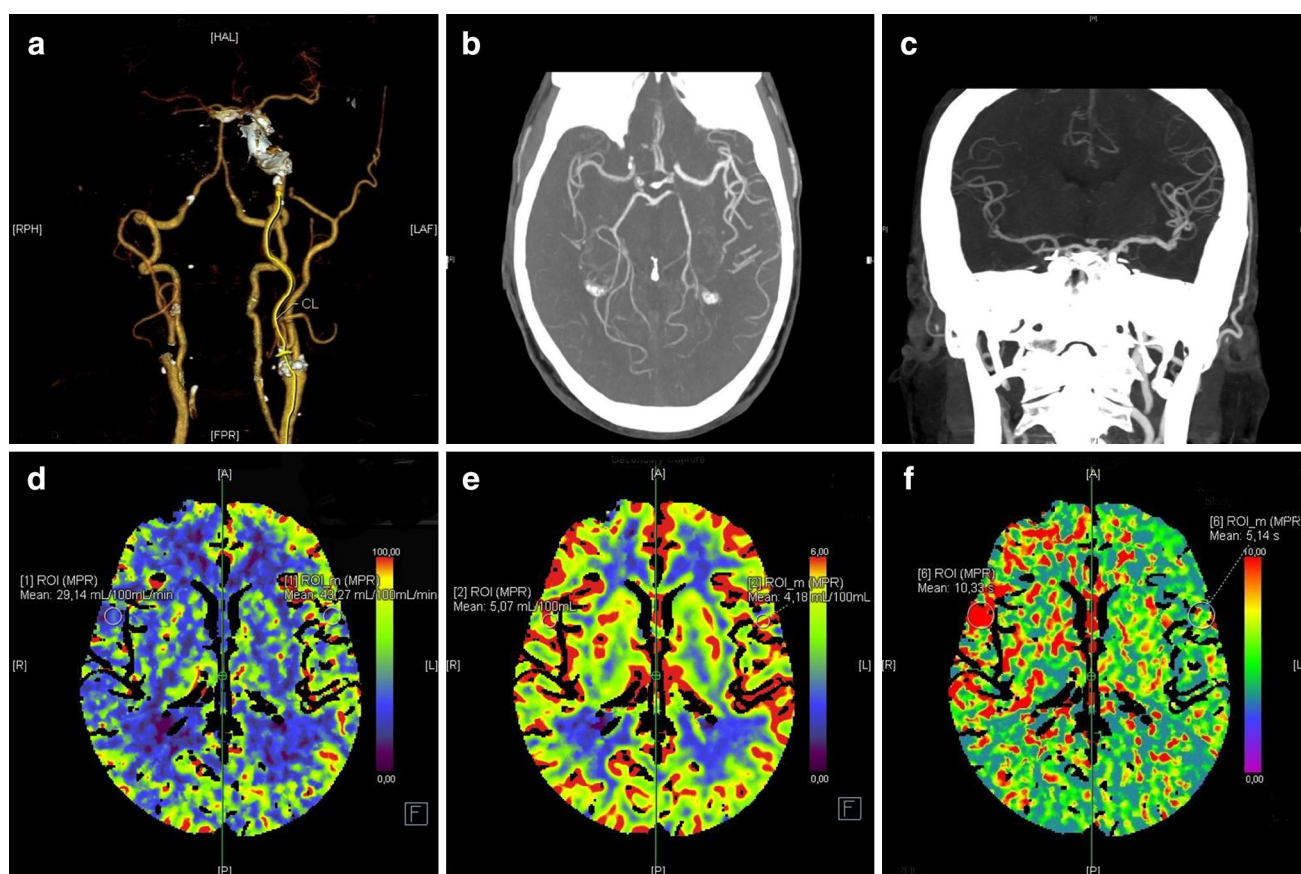
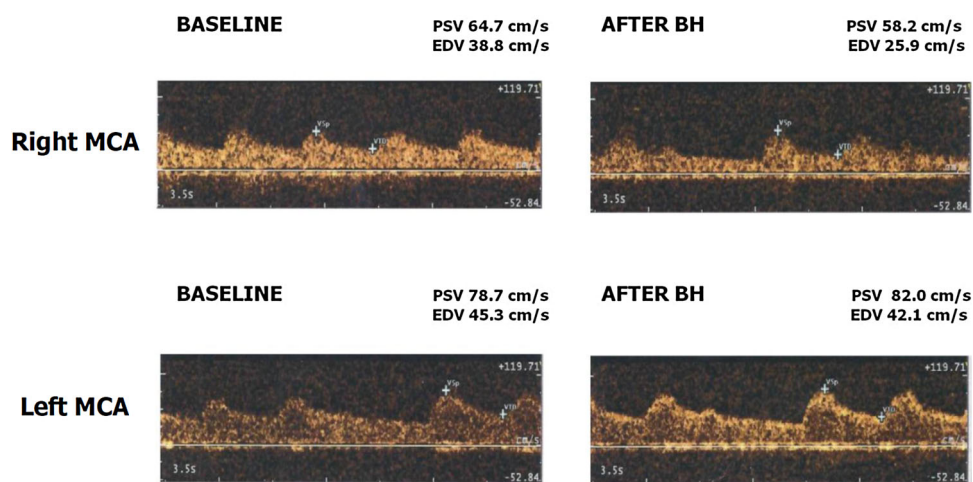
The EEG did not show any epileptic or focal slow waves activities. Brain MRI, including diffusion weighted images did not reveal acute or subacute lesions. Doppler neck ultrasound examination showed occlusion of the right internal carotid artery (ICA) and near-occlusion of the right external carotid artery (ECA), as well as moderate stenosis of the left ICA and ECA. Trans-temporal window insonation of the M1 segment of the right middle cerebral artery (MCA) showed a post-occlusive flow. Breath-holding test documented an exhausted cerebrovascular reserve (Fig. 1).

---

✉ Cindy Tiseo  
cindy.tiseo@gmail.com

<sup>1</sup> Neurology and Stroke Unit, Avezzano Hospital, Department of Applied Clinical Sciences and Biotechnology, University of L'Aquila, via Vetoio, 67100 L'Aquila, Italy

**Fig. 1** Transcranial Doppler ultrasonography with transtemporal insonation of the M1 segment of the MCAs before and after 30 s of breath-holding (BH)



**Fig. 2** CT angiography of the intra- and extra-cranial arteries of the brain showing **a** the occlusion of the right ICA and the near-occlusion of the right ECA and **b** and **c** poor collateral circulation. Brain CT perfusion study showing **d** reduced cerebral blood flow, **e** increased

cerebral blood volume, and **f** prolonged mean transit time in the right hemisphere with respect to the left hemisphere, consistent with hypoperfusion

CT angiography confirmed the occlusion of the right ICA, the near-occlusion of the right ECA, and a poor collateral circulation (Fig. 2). CT perfusion showed an extensive area of hypoperfusion involving the right anterior circulation

territory (Fig. 2). The patient refused to have performed conventional cerebral angiography.

The diagnosis of haemodynamic TIAs was duly considered. To improve cerebral perfusion and prevent further

haemodynamic episodes, we considered the possibility of revascularisation procedures. The patient was referred to the vascular surgeon who deemed the patient not eligible for any revascularisation procedure. To improve cerebral blood flow the ongoing antihypertensive treatment, consisting of losartan plus hydrochlorothiazide 50 mg/12.5 mg qd, was stopped. Moreover, acetylsalicylic acid 100 mg qd and atorvastatin 40 mg qd were introduced. Two days after discontinuation of the antihypertensive treatment, limb-shaking movements resolved and the patient remained completely asymptomatic during a 1-year follow-up period.

In our patient, symptoms and para-clinical investigations were consistent with the spectrum of a limb-shaking syndrome (LSS). This syndrome is a rare haemodynamic TIA occurring in about 11% of patients with severe stenosis or occlusion of the ICA [1]. The clinical features of LSS are temporary involuntary movements described as shaking, trembling, and twitching, affecting the limbs, and always sparing the face muscles. Involuntary movements are mostly seen to involve hand, arm, and leg contralateral to the ICA lesion, or occasionally both arms or legs in an asymmetrical way [1]. Each episode lasts less than 5 min, it usually repeats several times throughout the day, and is often, but not necessarily precipitated by activities that may compromise cerebral perfusion, such as standing up from the supine position. In agreement with the findings of other reports, orthostatic hypotension is not mandatory for the development of LSS, although it contributes to the reduction of blood pressure thus decreasing cerebral perfusion pressure with postural changes [2, 3]. During or following limb-shaking, transient limbs paresis or speech disturbances may be observed [1].

The pathogenesis of these symptoms depends on cerebral haemodynamic changes induced by the ICA stenosis or occlusion. Thanks to the anastomoses of the Willis' circle, cerebral perfusion of the anterior circulation of the hemisphere ipsilateral to the ICA stenosis or occlusion is maintained through collateral circulation from the posterior circulation arteries and from the contralateral anterior circulation. However, a severe lesion of the ICA causes chronic cerebral hypoperfusion with the subsequent activation of the autoregulation mechanism consisting of arteriolar dilatation to maintain an adequate cerebral blood flow. The maximum vasodilatation of the intracranial arteries causes the exhaustion of vasomotor reactivity that may transiently and further compromise cerebral perfusion [3], when the patient stands up from the supine position, walks, exercises, coughs, or laughs. Indeed, these conditions are responsible for a further transient critical reduction of cerebral blood flow that occurs mostly in the watershed territory of the MCA. The focal and transient cortical ischaemia in the ICA territory causes the onset of

temporary hyperkinetic involuntary limb movements through the disinhibition or release of subcortical motor areas. An EEG failed to show any epileptiform activity associated with LSS, although contralateral slow theta-delta activity has been reported in some patients with LSS [4].

In our patient, transcranial Doppler ultrasounds revealed an exhausted cerebrovascular reserve as there was no increase in blood flow velocity in the M1 segment ipsilateral to the ICA stenosis or occlusion after the breath-holding test; conversely, there was even a paradoxical decrease of blood flow velocity, a steal effect that might have been the consequence of redistribution of blood flow away from the already hypoperfused territory to cerebrovascular beds with retained capacity of arteriolar dilatation. Patients with ICA occlusion and LSS have a significant impairment of cerebral blood flow when compared to patients with ICA occlusion without LSS. In our patient the near-occlusion of the ECA probably contributed to establish the severe perfusion deficit and to the development of LSS. CT perfusion and PET scan studies are both useful to demonstrate the presence of inadequate perfusion in the anterior circulation, and may help to identify the haemispheric localisation of the focal haemodynamic TIA. Indeed, a previous report, using Xenon-133 to detect regional decreases of cerebral blood flow, found a significant hypoperfusion of the dorsofrontal and upper Rolandic regions contralateral to the shaking limbs [5].

The treatment of LSS is aimed at restoring the cerebral blood perfusion with revascularisation procedures in order to stop the symptoms and to reduce the risk of haemodynamic or atherothrombotic stroke. Among revascularisation procedures those of choice are carotid endarterectomy and carotid artery stenting; the ECA/ICA bypass surgery, and superficial temporal artery/middle cerebral artery bypass surgery could represent alternative approaches in the absence of any conclusive evidence on the outcome. Moreover, since the ECA provides an important collateral pathway in the presence of an occlusion or a severe stenosis of the ICA some evidences shows that treating the ECA's stenosis could represent an alternative therapeutic strategy in selected patients with LSS [6]. In patients who are not eligible for carotid revascularisation, an alternative and reasonable medical approach is based on the controlled increase of blood pressure that might contribute, by improving cerebral perfusion, to the regression of symptoms [7].

LSS patients are at high risk for hyperperfusion syndrome after carotid revascularisation, because maximally dilated pre-capillary distal arterioles in these patients cannot constrict normally in response to increased blood pressure after resumption of normal cerebral blood flow. It has been observed that patients with LSS have a 23% risk

**Table 1** Proposed diagnostic assessment

---

Medical history, assessment of possible precipitating factors, evaluation of the involuntary movements
Detailed neurovascular examination
Brain CT or MRI
Imaging of both the extra- and intra-cranial arteries (cervical duplex plus transcranial Doppler ultrasonography, MRI or CT angiography)
Traditional or functional neuroimaging of the brain evaluating cerebral blood flow/metabolism (CT or MRI perfusion, positron emission tomography (PET), single-photon emission computed tomography (SPECT))
EEG for the exclusion of an epileptic origin

---

of post-endarterectomy intracranial haemorrhage [8]. In order to reduce the risk of hyperperfusion a careful intra- and post-operative surveillance of systemic arterial blood pressure is mandatory.

To differentiate LSS from partial motor epilepsy, it is necessary to carefully evaluate some clinical features such as the absence of tonic-clonic jerkings and Jacksonian march, the sparing of facial muscles, the presence of precipitating factors, the absence of epileptic abnormalities on the EEG recording, and the absence of response to antiepileptic drugs. The acute onset of involuntary hyperkinetic movements of the limbs is often related to cerebrovascular lesions such as stroke, vasculitis, and vascular malformations involving the basal ganglia; such conditions need to be ruled out with brain neuroimaging studies. On the other hand, transient jerky movements are generally considered neither a typical clinical presentation of TIAs nor the manifestation of carotid artery disease.

Although the differential diagnosis of hyperkinetic movements may be challenging, the prompt recognition of LSS syndrome is crucial for preventing stroke through the implementation of medical and surgical therapeutic strategies aimed to improve cerebral perfusion. Therefore it is important to start in the emergency department an adequate diagnostic workup for LSS including imaging studies of the carotid arteries and of the brain. In Table 1 we propose a stepwise approach for the diagnostic assessment of limb-shaking TIA.

This case report highlights the importance of a careful neurovascular physical examination along with an accurate medical history in the diagnosis of this rare haemodynamic TIA.

#### Compliance with ethical standards

**Funding** No funding was obtained for this case report.

**Conflict of interest** The Authors declare that they have no conflict of interest.

**Statement of human and animal rights** All procedures performed in this study involving human participant were in accordance with the ethical standards of the institutional and/or national research committee and with the 1964 Helsinki declaration and its later amendments or comparable ethical standards.

**Informed consent** Informed consent was obtained from the patient.

## References

- Persoon S, Kappelle LJ, Klijn CJM (2010) Limb-shaking transient ischemic attacks in patients with internal carotid artery occlusion: a case-control study. *Brain* 133:915–922. doi:[10.1093/brain/awq009](https://doi.org/10.1093/brain/awq009)
- Zaidat OO, Werz MA, Landis DM, Selman W (1999) Orthostatic limb shaking from carotid hypoperfusion. *Neurology* 53:650–651. doi:[10.1212/WNL.53.3.650](https://doi.org/10.1212/WNL.53.3.650)
- Baumgartner RW, Baumgartner I (1998) Vasomotor reactivity is exhausted in transient ischaemic attacks with limb shaking. *J Neurol Neurosurg Psychiatry* 65:561–564
- Bearden S, Uthman B (2009) Cerebral hemodynamic compromise associated with limb shaking TIA and focal EEG slowing. *Am J Electroneurodiagnostic Technol* 49:225–243
- Tatemichi TK, Young WL, Prohovnik I, Gitelman DR, Correll JW, Mohr JP (1990) Perfusion insufficiency in limb-shaking transient ischemic attacks. *Stroke* 21:341–347. doi:[10.1161/01.STR.21.2.341](https://doi.org/10.1161/01.STR.21.2.341)
- Kouvelos GN, Nassis C, Papa N, Papadopoulos G, Matsagkas MI (2012) Limb-Shaking transient ischemic attacks successfully treated with external carotid artery stenting. *Case Rep Med* 2012:532329. doi:[10.1155/2012/532329](https://doi.org/10.1155/2012/532329)
- Leira EC, Ajax T, Adams HP Jr (1997) Limb-shaking carotid transient ischemic attacks successfully treated with modification of the antihypertensive regimen. *Arch Neurol* 54:904
- Switzer JA, Nichols FT (2008) Are limb-shaking transient ischemic attacks a risk factor for postendarterectomy hemorrhage? Case report and literature review. *J Neuroimaging* 18:96–100. doi:[10.1111/j.1552-6569.2007.00172](https://doi.org/10.1111/j.1552-6569.2007.00172)