

Intraoperative Tonic-Clonic Seizure Under General Anesthesia Captured by Electroencephalography: A Case Report

Mark A. Burbridge, MD,* Richard A. Jaffe, MD, PhD,* Anthony G. Doufas, MD, PhD,* and Jaime R. Lopez, MD†

We present the case of a 34-year-old man undergoing craniotomy for arteriovenous malformation resection under general anesthesia who suffered a tonic-clonic seizure captured by intraoperative electroencephalograph. The seizure was extinguished with a propofol bolus. This patient had no previous history of seizures, and no precipitating cause was identified. Intraoperative electroencephalographic seizures under general anesthesia have been recorded previously in the literature, but our observation is the first to demonstrate this with overt motor manifestations. We also discuss the differential diagnosis of an intraoperative seizure under general anesthesia and provide guidance to the anesthesiologist who encounters this event. (A&A Case Reports. 2017;XXX:00–00.)

Clinical observations of unprovoked intraoperative tonic-clonic seizures, or seizure-like activity with simultaneous electroencephalograph (EEG) recording during general anesthesia have not been reported previously. Seizures in the perioperative period have a long list of potential etiologies, including idiopathic, drug-induced, metabolic, traumatic, as well as induced by direct electrical stimulation. The list of probable etiologies is reduced dramatically under general anesthesia, owing to the mechanism of action of anesthetic agents in suppressing neuronal transmission. Indeed, propofol, a ubiquitous agent used in anesthetic practice for induction and maintenance of anesthesia, routinely is recommended for the termination of status epilepticus. Propofol itself, however, also can produce myoclonic movements that can closely resemble motor seizure activity, but the EEG morphology is not consistent with a seizure.¹ Motor manifestations may be absent during an intraoperative seizure despite the EEG demonstrating obvious seizure activity.²

We present the first case of an intraoperative generalized tonic-clonic seizure under general anesthesia captured on real-time EEG monitoring in a 34-year-old patient presenting for craniotomy for resection of a cerebral arteriovenous malformation (AVM). Written consent for this case report to be published was obtained from the patient.

CASE DESCRIPTION

A 34-year-old man (85 kg, 177 cm) presented to the operating room for a stereotactic right posterior parietal-occipital craniotomy for resection of an AVM. Over the preceding

year, he had experienced nausea, vomiting, and worsening headaches as well as a left-sided complete visual field deficit. Cerebral angiograms demonstrated a small 2-cm diameter high-flow AVM in the right posterior parietal-occipital region that was classified as a Spetzler-Martin Grade 2 AVM. Preoperative imaging demonstrated a large chronic hematoma cavity and hemosiderin-stained brain surrounding the AVM. Embolization was not considered possible, and the patient elected to proceed with open surgery versus radiosurgery due to worsening headaches and a persistent visual deficit.

His medical history included untreated sleep apnea of unclassified severity, and essential hypertension for which he took no medications. His only preoperative medication was amitriptyline 20 mg in the evenings as a sleeping aid. He had no drug allergies. He had not previously had surgery. No illicit drug use was admitted by the patient. His laboratory data revealed values all within normal limits on complete blood count, coagulation profile, urea, creatinine, and electrolytes.

After intravenous access was established in the preoperative area, the patient was premedicated with 2 mg midazolam and brought to the operating room. Anesthesia was induced with 500 µg fentanyl, 150 mg propofol, and 50 mg rocuronium. He was intubated without difficulty. Infusions of remifentanyl (0.05–0.1 µg/kg/min) and propofol (50 µg/kg/min) were commenced in addition to age-adjusted 0.5 minimum alveolar concentration sevoflurane for the maintenance of anesthesia. He also received dexamethasone 8 mg and ceftriaxone 1 g. A right radial artery catheter and left subclavian central line were then placed. The patient was cooled with an underbody water circulation blanket system for prophylactic neuroprotection.

Intraoperative neuromonitoring recording and stimulation subdermal needle electrodes were then placed to obtain transcranial electrical motor-evoked potentials (TcMEPs), somatosensory-evoked potentials, and 2 channels of EEG. Remifentanyl 150 µg was administered 90 minutes after induction to provide stable hemodynamics during Mayfield frame application. No local anesthetic was injected before incision. Approximately 180 minutes after induction, while burr holes were being drilled, the EEG showed low-voltage

From the *Department of Anesthesiology, Perioperative and Pain Medicine and †Department of Neurology, Stanford University Medical Center, Stanford, California.

Accepted for publication December 27, 2016.

Funding: None.

The authors declare no conflicts of interest.

Address correspondence to Mark A. Burbridge, MD, Department of Anesthesiology, Perioperative and Pain Medicine, Stanford University Medical Center, Stanford, CA 94304. Address e-mail to markburb@stanford.edu.

Copyright © 2017 International Anesthesia Research Society
DOI: 10.1213/XAA.0000000000000509

theta activity with brief periods of burst suppression. During the craniectomy, the patient began displaying full body rhythmic jerking movements accompanied by a generalized seizure pattern on the EEG that lasted for 100 seconds (Figure 1). Of note, neither somatosensory-evoked potentials nor TcMEPs had been attempted in the 45 minutes before the patient's seizure activity. Propofol 50 mg IV was given, and these movements quickly abated. An infusion of levetiracetam 1000 mg IV was started and the propofol infusion was increased to 75 µg/kg/min for the duration of the case for seizure prophylaxis. TcMEP stimulation was discontinued except for critical moments during the surgical resection for the duration of the case because there was a possibility that TcMEP could induce subsequent seizures.

With these prophylactic measures taken, it was decided to continue with the case, which proceeded uneventfully with complete resection of the AVM. TcMEPs were obtained on 4 subsequent occasions after the seizure without any evidence of electrographic seizure or epileptiform activity on the EEG. The patient was discharged from the hospital 4 days later and has, to our knowledge, experienced no subsequent seizures or untoward events in relation to his surgery.

DISCUSSION

Seizures under general anesthesia have occurred with a variety of common anesthetic agents.³ Intraoperative seizures captured by simultaneous EEG recording have been reported in the anesthesia literature during neurosurgical procedures but without motor manifestations.² The authors of this case series retrospectively reviewed the records of 400 patients in whom continuous EEG was recorded and analyzed these records for evidence of epileptiform activity. They found that 2 of 400 patients had suffered an electrographic intraoperative seizure. The first patient experienced an isolated epileptiform discharge on EEG out of a burst suppression pattern during pituitary adenoma resection that was attributed to surgical manipulation. The second patient presented to the operating room for clipping of an anterior communicating artery aneurysm and experienced two intraoperative seizures. The first occurred before a burst suppression pattern on the EEG was established and before surgical manipulation, but the second seizure arose while the EEG showed greater than 80% burst suppression while surgery was underway. These authors proposed that the presence of subarachnoid blood caused the seizure, which is possible considering this patient had intractable seizures postoperatively.

The precipitating cause of the seizure in our case report is uncertain. Preoperative laboratory values were all within normal limits, including complete blood count, coagulation profile, urea, creatinine, glucose, and electrolytes. A toxicology screen had not been performed because of a lack of clinical suspicion, so it remains a possibility that the patient seized due to withdrawal from substances such as alcohol or opioids. In addition, no withdrawal symptoms were noted postoperatively. Another possible explanation is that the amitriptyline taken chronically as a sleep aid induced the seizure, as this is a known side effect of this medication; however, the patient had taken this drug at the same low dose of 20 mg once per day for several years and had never had a seizure, making this unlikely. The

hemosiderin-stained brain surrounding the AVM also could have served as an origin for the seizure, but the lack of any seizure activity before or after the surgery makes this less likely.

One explanation for the seizure in our case is that one of the medications given during the anesthetic induced or facilitated the seizure. The agents used in this procedure up to the time of the seizure included fentanyl, propofol, rocuronium, sevoflurane, remifentanyl, ceftriaxone, and dexamethasone. Of these, only propofol and sevoflurane have been demonstrated to induce seizures, or seizure-like manifestations. Curiously, propofol can induce myoclonic movements resembling a tonic-clonic seizure, and it also can be administered to treat status epilepticus. Electroconvulsive therapy studies demonstrate a shorter seizure duration with propofol compared with methohexital.⁴

Conversely, propofol is recognized to induce myoclonic activity that can closely resemble physical seizure activity.⁵ This myoclonic activity has even been reported after the conclusion of surgery in the recovery room.⁶ Li et al¹ published a case report of a 23-year-old man who, while undergoing surgery, experienced generalized shaking after induction with propofol and maintenance with desflurane. Motor symptoms were terminated with a propofol bolus and a propofol infusion was started, but a subsequent episode of generalized shaking occurred, which prompted termination of the procedure. A workup for the etiology of seizure was inconclusive so the patient returned to the operating room to complete the surgery 2 days later with EEG recording. The generalized movements similarly occurred again, but without any epileptiform activity on the EEG. It was concluded that these movements were likely myoclonus caused by propofol. This case demonstrates that although myoclonus from propofol can resemble a seizure, the EEG findings are not consistent with a seizure. Tonic-clonic seizure activity with simultaneous EEG under sevoflurane anesthesia has been described in several reports. In one single-volunteer study, the participant was otherwise healthy with no history of seizures. Seizure activity took place at an end-tidal sevoflurane concentration of 4.14% and lasted for 35 seconds before propofol was given to terminate the seizure.⁷ In another study, 2 volunteer participants experienced EEG discharges at end-tidal sevoflurane concentration of approximately 4%.⁸ During our case, propofol was running simultaneously with sevoflurane at only 0.5 age-adjusted minimum alveolar concentration (0.9%), making sevoflurane an unlikely cause of the seizure.

Another possible explanation is that the electrical stimulation used to obtain the TcMEPs induced the seizure. A recently published retrospective review of more than 4000 charts of patients who underwent procedures with motor-evoked potential (MEP) monitoring investigated the incidence of seizures caused by electrical stimulation in a wide variety of surgeries including intracranial and spine surgery.⁹ The electrical stimulation used included transcranial electrical stimulation (TES) alone, or TES and direct cortical electrical stimulation (DCES). It is important to distinguish between the 2 different stimulation methods, because DCES generally is considered to carry a greater risk of seizures.

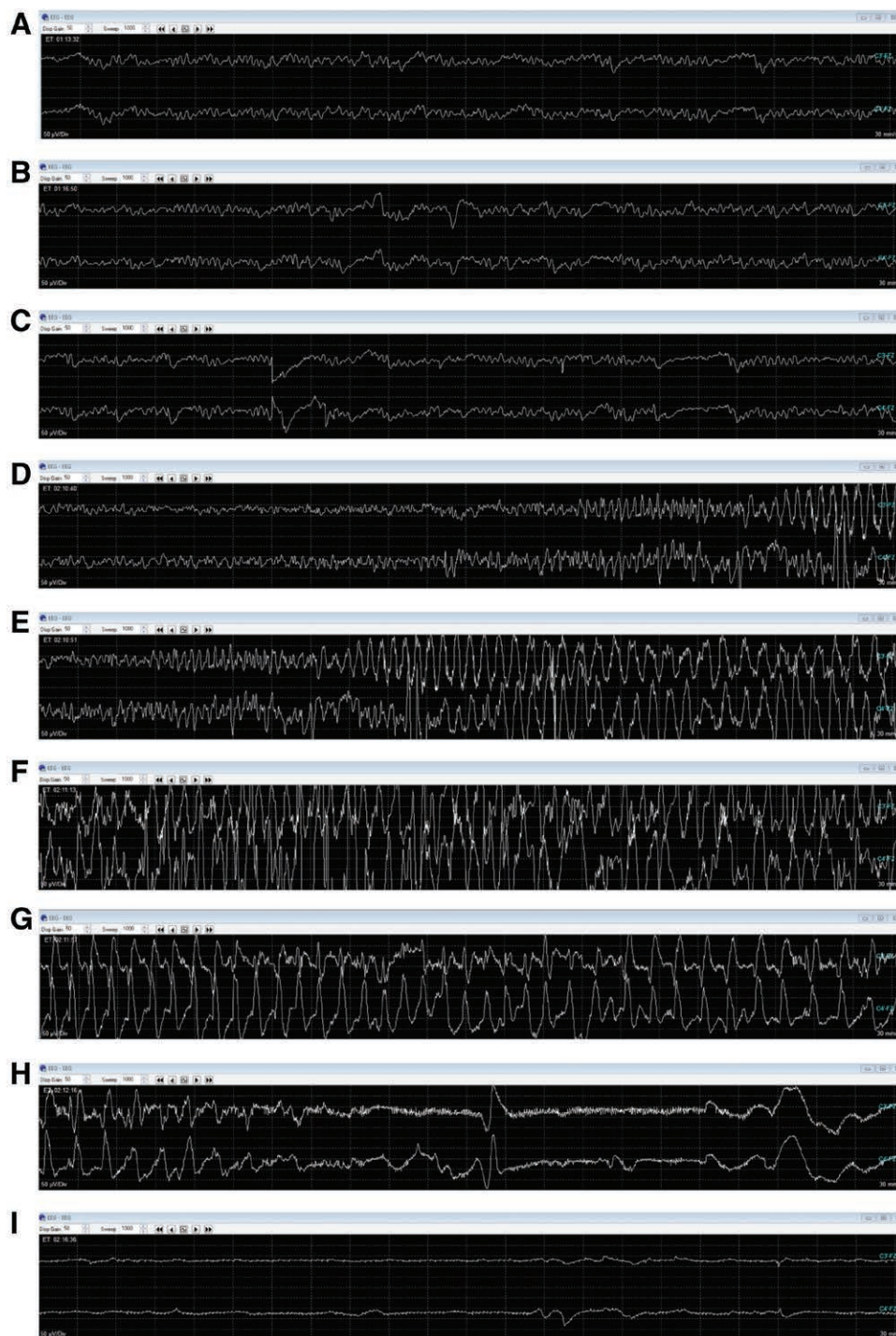


Figure 1. Evolution of the seizure is illustrated. Approximately 14 minutes before seizure, there is low-voltage bilateral, predominant theta frequency activity recorded from 2 electrodes, on the left (panel A, C3'-Fz) and right (panel B, C4'-Fz; B). C, Baseline EEG showing symmetrical low-voltage theta frequency bilaterally with a short period of burst suppression 150 seconds before seizure. D, Start of seizure activity with earlier onset on the right, C4'-Fz. E, Generalized electrographic seizure, which correlated with bilateral rhythmic upper and lower extremity movements. F, Continued seizure activity. G, Slowing of seizure activity. H, Seizure extinguished by propofol bolus 100 seconds after start of seizure activity. I, Isoelectric EEG after propofol bolus. EEG indicates electroencephalograph.

Furthermore, how a seizure is identified is equally important. In their study, seizures were defined as “detected through clinical observation of movement” and were found to have a TES and DCES seizure incidence of 0.7% and 5.4%, respectively. Of the 29 patients who had intracranial surgery and experienced an intraoperative seizure, 6 received TES

alone and 3 of these patients had a history of seizures. After occurrence of the first seizure, 69% of cases stopped using MEPs; however, 2 of 22 of patients had a second seizure and 1 of 22 had a third seizure, even though MEP monitoring was discontinued after the first seizure.⁶ Based on these data, it would appear that our patient falls into the lowest

probability category for seizures. Nonetheless, it is possible that TcMEP stimulation during our case may have contributed to the seizure, but our intraoperative neuromonitoring records showed that it had been 45 minutes since the last TcMEP when the seizure occurred. In addition, 4 separate TcMEPs were obtained subsequent to the seizure without clinical or EEG evidence of seizures. Thus, it seems unlikely that TcMEP was the sole cause or a substantial contributor to the seizure.

No published guidelines exist on the optimal management of intraoperative seizures. Medical management of an acute seizure is a medical emergency that requires immediate treatment to extinguish clinical and electrographic seizure activity. The rapid assessment and management of airway, breathing, and circulation must be the first priority. Initial drug therapy should be administered with the goal of rapidly extinguishing the seizure.

Current guidelines suggest intravenous lorazepam or midazolam as first-line agents. Maintenance therapy is then administered with the objective of obtaining rapid therapeutic levels of an anticonvulsant if the emergent initial therapy extinguishes the seizure, or if not, to further aid in extinguishing the seizure. Recommendations for maintenance therapy consist of valproate sodium, phenytoin, fosphenytoin, and levetiracetam. Evidence for the superiority of any specific agent is lacking, and treatment is determined by the clinical situation.

Simultaneously, exploring for the etiology of the seizure should be performed and consists of obtaining the following in all patients: continuous vital signs monitoring, blood glucose, complete blood count, basic metabolic panel, calcium, magnesium, computed tomography scan of head, and continuous EEG monitoring. Based on the clinical presentation, further tests, including magnetic resonance imaging of the brain, lumbar puncture, a comprehensive toxicology panel, liver function tests, arterial blood gas, and antiepileptic drug plasma levels may be useful.¹⁰⁻¹²

CONCLUSIONS

We present the first documented case of an intraoperative motor seizure under general anesthesia captured by contemporaneous EEG recording. Although the seizure in our case had no obvious etiology, the treatment goals must include rapid termination of the seizure, administration of anticonvulsant prophylaxis, and prevention of further seizures by exploring metabolic, mechanical, electrical, and drug-induced etiologies. Terminating surgery must be discussed with a

multidisciplinary approach, including the surgical, anesthesia, and neuromonitoring teams and must be balanced against the risk of not completing the surgical procedure. ■■

DISCLOSURES

Name: Mark A. Burbridge, MD.

Contribution: This author helped conceive the structure of the case report and write the manuscript.

Name: Richard A. Jaffe, MD, PhD.

Contribution: This author helped conceive the structure of the case report and write the manuscript.

Name: Anthony G. Doufas, MD, PhD.

Contribution: This author helped conceive the structure of the case report and write the manuscript.

Name: Jaime R. Lopez, MD.

Contribution: This author helped conceive the structure of the case report and write the manuscript.

This manuscript was handled by: Raymond C. Roy, MD.

REFERENCES

1. Li Y, Flood P, Cornes S. Electroencephalography of seizure-like movements during general anesthesia with propofol: seizures or nonepileptic events? *A A Case Rep.* 2015;5:195-198.
2. Howe J, Lu X, Thompson Z, Peterson GW, Losey TE. Intraoperative seizures during craniotomy under general anesthesia. *Seizure.* 2016;38:23-25.
3. Voss LJ, Sleigh JW, Barnard JP, Kirsch HE. The howling cortex: seizures and general anesthetic drugs. *Anesth Analg.* 2008;107:1689-1703.
4. Mårtensson B, Bartfai A, Hallén B, Hellström C, Junthé T, Olander M. A comparison of propofol and methohexital as anesthetic agents for ECT: effects on seizure duration, therapeutic outcome, and memory. *Biol Psychiatry.* 1994;35:179-189.
5. San-juan D, Chiappa KH, Cole AJ. Propofol and the electroencephalogram. *Clin Neurophysiol.* 2010;121:998-1006.
6. Zeiler SR, Kaplan PW. Propofol withdrawal seizures (or not). *Seizure.* 2008;17:665-667.
7. Pilge S, Jordan D, Kochs E, Schnieder G. Sevoflurane-induced epileptiform electroencephalographic activity and generalized tonic-clonic seizures in a volunteer study. *Anesthesiology.* 2012; 119: 447.
8. Kaisti KK, Jaaskelainen SK, Rinne JO, Metsahonkala L, Scheinin H. Epileptiform discharges during 2 MAC sevoflurane anesthesia in two healthy volunteers. *Anesthesiology.* 1999;91:1952-1955.
9. Ulkatan S, Jaramillo AM, Tellez MJ, Kim J, Deletis V, Seidel K. Incidence of intraoperative seizures during motor evoked potential monitoring in a large cohort of patients undergoing different surgical procedures. *J Neurosurg.* 2016;24:1-7.
10. Unterberger I. Status epilepticus: do treatment guidelines make sense? *J Clin Neurophysiol.* 2016;33:10-13.
11. Ziai WC, Kaplan PW. Seizures and status epilepticus in the intensive care unit. *Semin Neurol.* 2008;28:668-681.
12. Brophy GM, Bell R, Claassen J, et al; Neurocritical Care Society Status Epilepticus Guideline Writing Committee. Guidelines for the evaluation and management of status epilepticus. *Neurocrit Care.* 2012;17:3-23.