

## Letter to the Editor

### Saccadic hypermetria on abduction of the ipsilesional eye in internuclear ophthalmoplegia


**Keywords:**

Internuclear ophthalmoplegia  
Medial longitudinal fasciculus  
Saccadic hypermetria  
Abducting saccade

Dear Editor,

The medial longitudinal fasciculus (MLF) is a central conduit for many brainstem pathways and is the final common pathway for all classes of conjugate eye movements including saccades (rapid refixations) [1]. The most commonly recognized syndrome that results from injury to the MLF is internuclear ophthalmoplegia (INO) and is characterized by weakness or paralysis of adduction on the side of the MLF lesion during horizontal eye movements [1]. Dissociated horizontal nystagmus or saccadic overshooting during abduction in the contralesional eye is also a unique finding in patients with INO, although this does not always occur [2]. After the overshoot, the eye returns to the target with an exponentially decaying course. However, we found the saccadic overshooting during the abduction of the ipsilateral eye in patient with INO.

#### 1. Case report

A 79-year-old man with hypertension suddenly felt dizziness and diplopia. The diplopia was worsened when he looked to the left side. He swayed a little bit, but he could walk alone. He denied any other symptoms such as dysarthria, sensory change, or weakness. He had no previous history of dizziness or diplopia. The visual acuity was 20/32 in the both eyes. The patient showed torsional nystagmus toward the patient's right shoulder in the primary position and typical INO with adduction limitation in the right eye, and subtle abducting nystagmus in the left eye when he attempted to look to the left. Saccadic eye movements to the left side of both eyes were superimposed by torsional nystagmus. Saccadic hypermetria was observed in the right eye when he attempted to look to the right (Video 1). Convergence eye movement was normal. He had skew deviation with hypertropia on the right eye. Video-oculography revealed torsional spontaneous nystagmus toward the patient's right shoulder with a small upbeat component (Fig. 1A). The nystagmus was not changed when he gazed to the both sides. Because of adduction limitation, it was hard to perform exact calibration. However, even the poor calibration, saccade test of the right eye definitely showed hypermetria followed by glissade with normal saccadic velocity on abduction (i.e., right side), and slow and hypometric saccades on adduction (i.e., left side) (Fig. 1B). Saccade test of the left eye

showed abducting nystagmus, when attempting to the left side, but normal saccadic velocity and amplitude on adduction (Fig. 1B). The MRI showed focal infarction in the right paramedian pons (Fig. 1C). INO and nystagmus gradually disappeared and he did not complain any symptoms 2 weeks after admission.

#### 2. Discussion

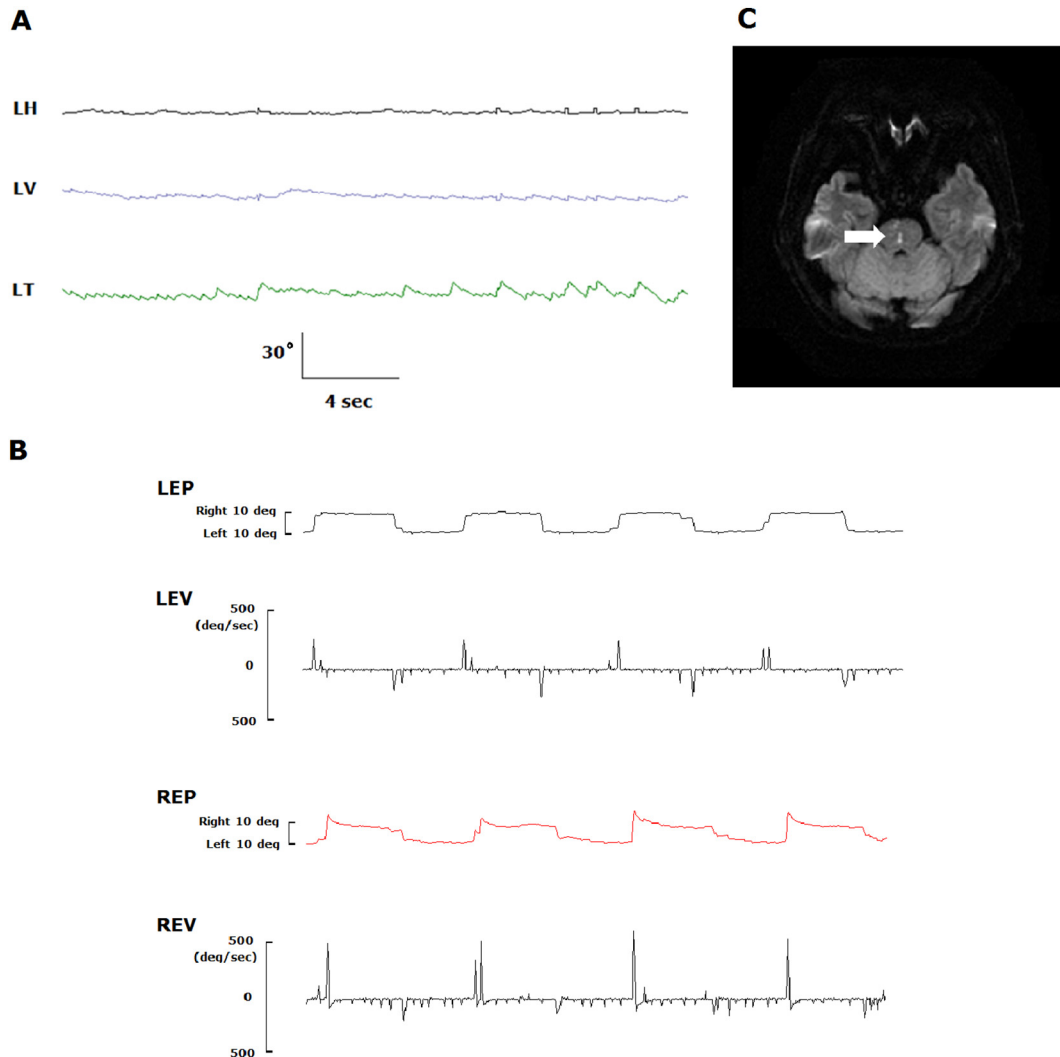
To the best of our knowledge, this study is the first to document saccadic hypermetria on abduction of the ipsilesional eye in INO.

Accurate saccadic eye movements are critical for directing the fovea to sites of interest. The posterior vermis of the cerebellar cortex and its major output, the fastigial nucleus, are related to the control of saccadic accuracy [3,4]. Saccadic hypermetria is the hallmarks of cerebellar disease, while slow saccadic velocity is usually followed by pontine lesion. However, saccadic hypermetria during abduction in the contralesional eye, generally called as 'dissociated abducting nystagmus', is frequently found in patients with INO. The one hypothesis to explain saccadic hypermetria during abduction in the contralesional eye implicates an adaptive response to overcome the weakness of the contralateral medial rectus [2]. Too large pulse for step for attempt to increase innervation to the yoke muscle by Hering's law results in an overshooting waveform of the abducting eye [5,6]. As the eye slips away from the target, another corrective abducting saccade with an overshooting waveform is generated. Repetition of this cycle produces dissociated nystagmus [6].

We can explain the saccadic hypermetria of the ipsilesional eye during abduction as similar hypothesis with the saccadic hypermetria in the paralytic strabismus. In patients with paralytic strabismus, when they need to fixate with their paretic eye, they produce abnormal saccades when refixing in the direction opposite to the paralysis. For example, in case of patients with third nerve palsy, they can show the saccadic hypermetria of the ipsilesional eye during abduction, same with our patient. This saccadic hypermetria of the ipsilesional eye in paralytic strabismus might be explained by a loss of the decrement in antagonist forces of the weak eye for the step of innervation (i.e., the paretic muscle cannot be normally relaxed) and a central misrepresentation of the position of the paretic eye by the gaze-holding network, which also can be applied to case with INO [3,7]. This misrepresentation of the position of the paretic eye may induce pulse-step mismatch and glissadic saccadic overshoot, which is usually caused by a mismatch between the pulse and step components.

Even the patient did not have any limb ataxia, but he had some truncal ataxia. Truncal ataxia in our patient may be explained by the involvement of the spinocerebellar loop in the medial pontine tegmentum [8]. The main component of the spontaneous nystagmus was the torsional one. Combined damage to the pathways from the posterior and anterior canals would give rise to conjugate ipsiversive torsional nystagmus with opposite vertical components due to partial cancellation of vertical actions by the recti and oblique muscles in each eye [9].

We found the saccadic overshooting in the lesioned eye during abduction in patients with INO, and this sign might be considered as a



**Fig. 1.** (A) Video-oculography reveals a primary torsional nystagmus toward the patient's right shoulder with a small upbeat component. (B) The patient makes saccades to targets located at 10° right and at 10° left. Right eye shows hypermetric saccades followed by glissades with normal saccadic velocity during saccades to the right side, but hypometric and slow saccades to the left side. Note that the velocity of adducting saccades of the right eye is lower than that of the corresponding abducting saccades. Saccade test of the left eye shows normal velocity and amplitude on both directions. (C) Diffusion-weighted axial brain MRI performed 7 h after the onset of symptoms shows hyperintense lesion (arrow) involving the right paramedian pons. LH = horizontal eye movement of the left eye; LV = vertical eye movement of the left eye; LT = torsional eye movement of the left eye. LEP = left eye position; LEV = left eye saccadic velocity; REP = right eye position; REV = right eye saccadic velocity.

possible additional sign of an INO. Further study will be needed for the frequency and mechanism of the saccadic overshooting of the ipsilesional eye during abduction in patients with INO.

#### Financial relationship disclosure

On behalf of all authors, the corresponding author states that there is no conflict of interest.

Dr. Lee serves on the editorial boards of the Research in Vestibular Science, Frontiers in Neuro-otology, and Current Medical Imaging Review, and received research support from DAWOONG PHARMACEUTICAL, Co. Ltd.

Dr. Kim reports no disclosures.

#### Author contributions

Dr. Kim conducted the design and conceptualization of the study, interpretation of the data, and revising the manuscript.

Dr. Lee wrote the manuscript, and analyzed and interpreted the data.

#### Ethical standards

The patient involved gave consent for publication of the case.

Supplementary data to this article can be found online at <http://dx.doi.org/10.1016/j.jns.2017.03.007>.

#### References

- [1] T.C. Frohman, S. Galetta, R. Fox, et al., Pearls & oysters: the medial longitudinal fasciculus in ocular motor physiology, *Neurology* 70 (2008) e57–e67.
- [2] D.S. Zee, T.C. Hain, J.R. Carl, Abduction nystagmus in internuclear ophthalmoplegia, *Ann. Neurol.* 21 (1987) 383–388.
- [3] R.J.Z.D. Leigh, *The Neurology of Eye Movements*, fifth ed. Oxford University Press, Philadelphia, 2015.
- [4] U. Buttner, L. Fuhry, *Eye movements*, *Curr. Opin. Neurol.* 8 (1995) 77–82.
- [5] B. Cohen, A. Komatsuzaki, Eye movements induced by stimulation of the pontine reticular formation: evidence for integration in oculomotor pathways, *Exp. Neurol.* 36 (1972) 101–117.
- [6] R.W. Baloh, R.D. Yee, V. Honrubia, Internuclear ophthalmoplegia. I. Saccades and dissociated nystagmus, *Arch. Neurol.* 35 (1978) 484–489.
- [7] D.S. Zee, R.D. Yee, Abnormal saccades in paralytic strabismus, *Am J. Ophthalmol.* 83 (1977) 112–114.
- [8] H. Mitoma, R. Hayashi, N. Yanagisawa, et al., Gait disturbances in patients with pontine medial tegmental lesions: clinical characteristics and gait analysis, *Arch. Neurol.* 57 (2000) 1048–1057.

- [9] J. Kim, H. Lee, S. Eggers, D. Zee, Vertigo and imbalance: clinical neurophysiology of the vestibular system, *Handbook of Clinical Neurophysiology*, 2010 451–477.

Hyung Lee  
Hyun Ah Kim\*

*Department of Neurology, Keimyung University School of Medicine, Daegu,  
Republic of Korea  
Brain Research Institute, Keimyung University School of Medicine, Daegu,  
Republic of Korea*

Corresponding author at: Department of Neurology, Keimyung  
University School of Medicine, 56 Dalseong-ro, Jung-gu, Daegu 700-712,  
Republic of Korea.  
*E-mail address:* [kha0206@dsmc.or.kr](mailto:kha0206@dsmc.or.kr) (H.A. Kim).

23 November 2016  
Available online 10 March 2017