



## Case Report

# Atypical moyamoya syndrome with brain calcification and stenosis of abdominal aorta and renal arteries

Hideki Uchikawa<sup>a,b,\*</sup>, Katsunori Fujii<sup>a</sup>, Mayuko Fujita<sup>a</sup>, Tomoko Okunushi<sup>a</sup>,  
Naoki Shimojo<sup>a</sup>

<sup>a</sup> Department of Pediatrics, Chiba University Graduate School of Medicine, Chiba, Japan

<sup>b</sup> Department of Pediatrics, Eastern Chiba Medical Center, Togane, Japan

Received 7 November 2016; received in revised form 27 February 2017; accepted 3 April 2017

## Abstract

Moyamoya syndrome is a progressive cerebrovascular disease that is characterized by stenosis of the terminal portion of the internal carotid artery and its main branches, in combination with an accompanying disease. We herein describe an 8-year-old boy exhibiting transient loss of consciousness, who had recurrent seizures in infancy with progressive brain calcification. On admission, he was alert but magnetic resonance angiography showed bilateral stenosis of the whole internal carotid artery and proliferation of vascular collaterals, and brain CT revealed calcification on bilateral putamen. Given that this fulfilled diagnostic criteria, we finally diagnosed him as having moyamoya syndrome, though the etiology was unclear. Interestingly, a whole vessel survey revealed vascular stenosis of abdominal aorta and renal arteries, in which the former has not been reported in moyamoya syndrome. We considered that brain calcification was gradually formed by decreased cerebral vascular flow from infancy, and stenosis of abdominal aorta was possibly extended from renal arteries. This is, moyamoya syndrome with brain calcification and stenosis of abdominal aorta, suggesting that morphological screening of whole vessels containing cerebral and abdominal arteries should be considered in cases of slowly progressive brain calcification.

© 2017 The Japanese Society of Child Neurology. Published by Elsevier B.V. All rights reserved.

**Keywords:** Moyamoya; Infantile; Calcification; Seizure; Abdominal aorta

## 1. Introduction

Moyamoya disease is characterized by progressive occlusion of the internal carotid artery or its terminal branches, which is accompanied by the formation of a collateral vascular network called as “moyamoya vessels” at the base of the brain [1]. Other vascular stenosis includes coronary artery, pulmonary artery, abdominal

artery, and renal artery, which occasionally causes renal hypertension [2]. However, to our knowledge, abdominal aorta has not been reported as an involvement of moyamoya disease.

Some of the angiographic and clinical features of moyamoya disease are sometimes observed in conjunction with congenital or acquired systemic disorders. This condition is known as moyamoya syndrome or quasi-moyamoya disease [3,4].

We herein describe an 8-year-old boy with progressive moyamoya syndrome, which is atypical case as moyamoya disease exhibiting increasing brain calcification and unusual stenosis of abdominal aorta.

\* Corresponding author at: Department of Pediatrics, Eastern Chiba Medical Center, 3-6-2 Okayamadai, Togane 283-8686, Japan. Fax: +81 475 50 1356.

E-mail address: uchikawa@chiba-u.jp (H. Uchikawa).

## 2. Case report

An 8-year-old Japanese boy was admitted to our hospital because of recurrent episodes of transient loss of consciousness during awake status. His delivery was unremarkable. At the age of 4 months, he exhibited unprovoked seizures, and revealed slight bilateral calcification in basal ganglia and temporal lobes on computed tomography (CT), which was gradually increased by 4 years (Fig. 1A, B). He was diagnosed as having epilepsy at that time, and phenobarbital was prescribed for 4 years without any additional epileptic seizure.

At the age of 8 years, he exhibited sudden loss of consciousness at school and admitted to our hospital. On admission, general physical examinations revealed unremarkable results. He also had no neurological deficit, but seemed to have mildly intellectual disability. His total intelligence quotient examination gave him the score of 78, indicating that he had mild mental retardation. Blood examinations including coagulating system (PT, APTT, TAT), inflammation (WBC, CRP, ANCA), amino acid analysis, autoimmune antibodies and calcium metabolism (intact-PTH, Ca, P) were all within normal limits.

Brain CT revealed increased bilateral calcification in basal ganglia, and frontal and temporal lobes, compared to those of 4 months and 2 years old (Fig. 1). Brain magnetic resonance angiography revealed prominent stenosis and disappearance of the whole internal carotid arteries and proliferation of vascular collaterals, which were typical for moyamoya vessels (Fig. 2A, B). Magnetic resonance imaging revealed flow voids in basal ganglia and ivy sign on the brain surface (Fig. 2B). Fluid-attenuated inversion recovery (FLAIR) image showed high intensities on deep white matter region (Fig. 2C).

We also investigated extra-cerebral systematic vascular involvements of this patient. We found moderate stenosis of abdominal aorta and renal arteries on con-

trast CT (Fig. 3A). The diameter of abdominal aorta was apparently narrow compared to the normal control that was already reported (Fig. 3B). The stenosis was limited to the range of abdominal aorta and renal arteries, and no other stenosis was identified. Single-photon emission computerized tomography (SPECT) of the brain revealed relatively preserved intracranial circulation (data not shown). The c.14429 G > A variant of *RNF213*, which are known to cause familial moyamoya disease [5], was investigated but failed to identify any mutation. Furthermore, although whole exome sequencing was performed, no pathological mutation was detected.

Though this patient fulfilled diagnostic criteria, he was unique case showing increased brain calcification and rare involvement of abdominal aorta as well as renal arteries. Therefore we finally diagnosed him as having moyamoya syndrome. Cerebral blood flow has been maintained and no other neurological findings were confirmed, so we have not performed vascular surgery for him, and currently maintained close observation at outpatient clinic.

## 3. Discussion

We described for the first time an 8-year-old Japanese boy with progressive moyamoya syndrome, exhibiting increasing brain calcification and unusual stenosis of abdominal aorta and renal arteries. This is, to our knowledge, a first report of progressive cerebral calcification and the involvement of abdominal aorta, possibly those being developed from infancy.

Extracranial vascular involvements of moyamoya disease have been widely reported, most often in the renal artery about 5% [2,6]. Renal artery stenosis tends to be located in the proximal region of the main branch. In addition to the renal artery, the coronary, pulmonary, hepatic, splenic, superior mesenteric, pancreatic, iliac, and peripheral arteries are also involved in moyamoya disease [2]. The stenosis of abdominal aorta

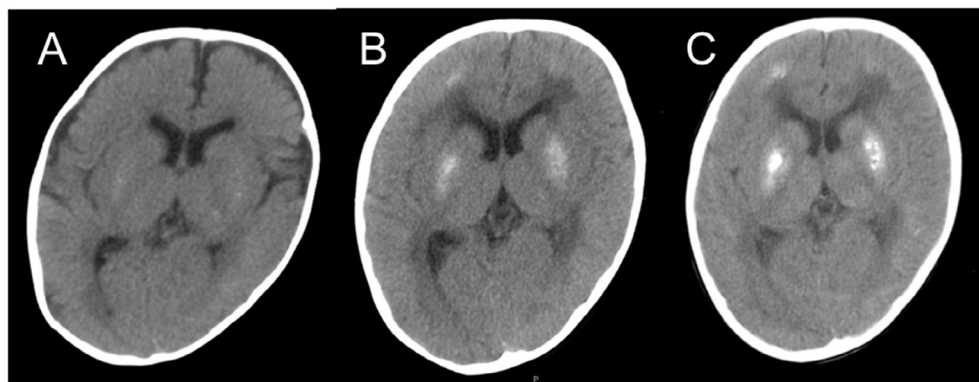


Fig. 1. Brain CT showing an increasing calcification of basal ganglia, and frontal and temporal cerebral regions at the age of (A) 4 months, (B) 2 years, and (C) 8 years, respectively.

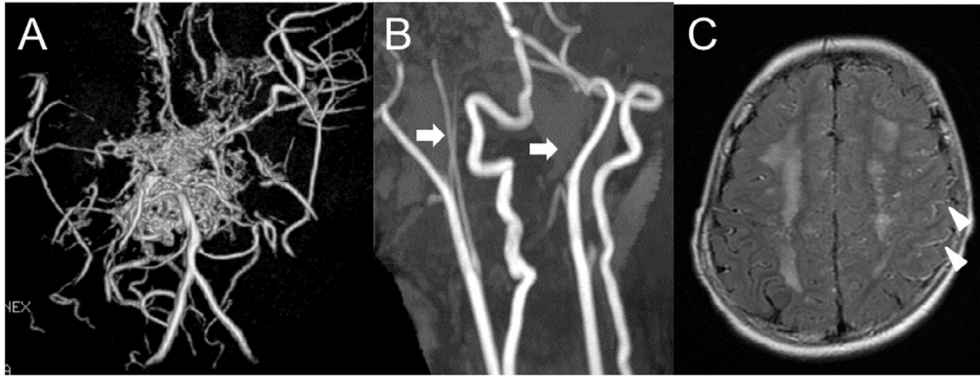


Fig. 2. Brain MRI and MR angiography at the age of 8 years. (A) MR angiography revealed moyamoya vessels and stenosis of the proximal region of the anterior and the middle cerebral arteries. (B) MR angiography indicated stenosis and disappearance (arrows) of the whole internal cerebral arteries. (C) Fluid attenuated inversion recovery images showed ivy sign (arrow heads) and high intensity lesions in the deep white matter.

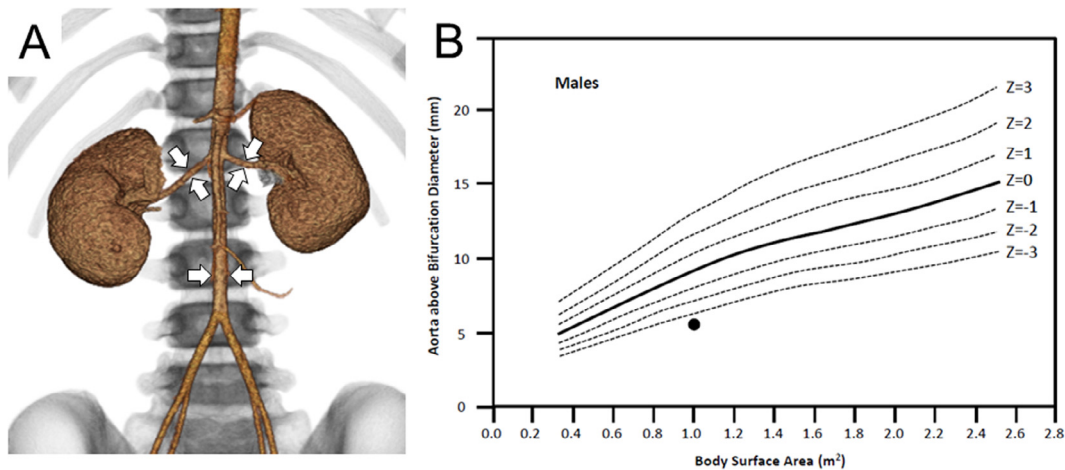


Fig. 3. Contrast CT showing a stenosis of the abdominal aorta and renal arteries. (A) Reconstruction image of the abdominal aorta and renal arteries. Arrows indicate the stenotic portion. (B) The diameter of abdominal aorta of this patient indicated less than  $-3SD$  compared to age-matched control described by Hegde et al. [12]. Filled circle depicts this patient.

might be extended from adjust renal arteries, as well as extending stenosis from the end portion of internal carotid arteries as observed in the progressed stage.

Calcification of the brain is not usually associated with moyamoya disease and syndrome. There have been some reports to exhibit calcification associated with moyamoya vessels. Moyamoya disease with *RNF 213* could show bilateral calcification in the basal ganglia [7]. Down syndrome is a chromosomal abnormality of trisomy-21, occasionally associated with moyamoya syndrome with brain calcification [8]. Systemic lupus erythematosus due to C1q deficiency is known to cause moyamoya syndrome with brain calcification [9]. Keutel syndrome is a hereditary disease to show abnormal cartilage calcification and moyamoya syndrome with brain calcification [10]. Hence, although etiology of calcification remains to be elucidated, brain calcification could be associated with not only moyamoya disease but also moyamoya syndrome.

A causative disease as homocystinuria, Down syndrome, fibromuscular dysplasia, sickle cell anemia, generalized arterial calcification of infancy, cerebral arteriopathy associate with ACTA2, vasculopathy, thrombophilia, neurofibromatosis type 1 and congenital internal carotid artery (ICA) agenesis should be discussed [3]. Most possible candidate disease is fibromuscular dysplasia, which is a congenital vascular dysplasia showing brain infarction or other ischemia of the organ. Although fibromuscular dysplasia usually shows ‘string of beads’ signs on MR angiography, which should be confirmed in 80% patients [11], and stenosis of renal arteries, which are typically recognized in distal portion, we could not confirm these findings in this patient. In addition, disease onset of fibromuscular dysplasia is usually early adulthood in women, we considered this disease seemed not to be likely for diagnosis of this patient. Congenital ICA agenesis also should be discussed. Congenital ICA agenesis is usually unilateral,

associated with unilateral closure of foramen lacerum. However, in this patient, the occlusion of ICA was bilateral, and the skull CT confirmed bilateral intact foramen lacerum, suggesting this congenital ICA agenesis is unlikely.

In conclusion, we demonstrated an 8-year-old boy with moyamoya syndrome accompanied with stenosis of the abdominal aorta with progressive brain calcification, suggesting that systematic vascular review containing brain arteries should be tried in cases with slowly progressive brain calcification in infancy.

## Acknowledgement

We thank to Prof. Kure in the Department of Pediatrics, Tohoku University for *RNF213* gene analysis and Dr. Hata in the Department of Maternal-Fetal Biology, National Research Institute for Child Health and Development for whole exome sequencing.

## References

- [1] Kuroda S, Houkin K. Moyamoya disease: current concepts and future perspectives. *Lancet Neurol* 2008;7:1056–66.
- [2] Togao O, Mihara F, Yoshiura T, Tanaka A, Kuwabara Y, Morioka T, et al. Prevalence of stenooclusive lesions in the renal and abdominal arteries in moyamoya disease. *AJR Am J Roentgenol* 2004;183:119–22.
- [3] Horn P, Pfister S, Bueltmann E, Vajkoczy P, Schmiedek P. Moyamoya-like vasculopathy (moyamoya syndrome) in children. *Childs Nerv Syst* 2004;20:382–91.
- [4] Scott RM, Smith ER. Moyamoya disease and moyamoya syndrome. *N Engl J Med* 2009;360:1226–37.
- [5] Miyatake S, Miyake N, Touho H, Nishimura-Tadaki A, Kondo Y, Okada I, et al. Homozygous c. 14576G > A variant of *RNF213* predicts early-onset and severe form of moyamoya disease. *Neurology* 2012;78:803–10.
- [6] Yamada I, Himeno Y, Matsushima Y, Shibuya H. Renal artery lesions in patients with moyamoya disease: angiographic findings. *Stroke* 2000;31:733–7.
- [7] Harel T, Posey JE, Graham BH, Walkiewicz M, Yang Y, Lalani SR, et al. Atypical presentation of moyamoya disease in an infant with a de novo *RNF213* variant. *Am J Med Genet A* 2015;167A:2742–7.
- [8] Lee KY, Lee KS, Weon YC. Asymptomatic moyamoya syndrome, atlantoaxial subluxation and basal ganglia calcification in a child with Down syndrome. *Korean J Pediatr* 2013;56:540–3.
- [9] Troedson C, Wong M, Dalby-Payne J, Wilson M, Dexter M, Rice GI, et al. Systemic lupus erythematosus due to C1q deficiency with progressive encephalopathy, intracranial calcification and acquired moyamoya cerebral vasculopathy. *Lupus* 2013;22:639–43.
- [10] Bosemani T, Felling RJ, Wyse E, Pearl MS, Tekes A, Ahn E, et al. Neuroimaging findings in children with Keutel syndrome. *Pediatr Radiol* 2014;44:73–8.
- [11] Touze E, Oppenheim C, Trystram D, Nokam G, Pasquini M, Alamowitch S, et al. Fibromuscular dysplasia of cervical and intracranial arteries. *Int J Stroke* 2010;5:296–305.
- [12] Hegde SV, Lensing SY, Greenberg SB. Determining the normal aorta size in children. *Radiology* 2015;274:859–65.