




Contents lists available at ScienceDirect

Parkinsonism and Related Disorders

journal homepage: www.elsevier.com/locate/parkreldis

Correspondence

Dystonia due to bilateral caudate hemorrhage associated with a *COL4A1* mutation

Keywords:

Stroke in young adults
Cranial MRI
Dystonia
COL4A1
Neurodegeneration with iron accumulation (NBIA)

Collagen IV alpha 1 (*COL4A1*) is one of the components of type IV collagen. Pathogenic mutations of *COL4A1* are associated with young-onset cerebrovascular disease [1]. Although patients with *COL4A1* mutations frequently manifest hemorrhagic stroke in the basal ganglia, movement disorders have not been reported. Furthermore, movement disorders have been seldom reported in basal ganglia hemorrhagic strokes [2,3]. Here, we present a case of a 32-year-old female patient with juvenile onset right hand and foot dystonia and mild mental retardation. Cranial magnetic resonance imaging (MRI) depicted hemorrhagic stroke in the bilateral caudate and dentate nuclei and abnormally high intensity in the white matter, mimicking neurodegeneration with brain iron accumulation (NBIA). The patient was genetically determined to harbor a *COL4A1* p.G832R mutation (Fig. 1A).

At birth, the patient had a high fever of unknown origin. She could not walk by herself until 18 months of age and showed abnormal posture in her right leg. At age 3, she was diagnosed with foot dystonia. At age 6, she had a seizure and was diagnosed with epilepsy. However, she has not experienced a second seizure attack. At age 17, she suddenly developed transient right leg weakness and sensory disturbance. Brain computed tomography (CT) showed an abnormal low-density area in the basal ganglia. At age 29, she experienced transient tinnitus and vertigo; at that time, cranial fluid-attenuated inversion-recovery MRI depicted an abnormal low-intensity area in the bilateral caudate head and dentate nucleus, dilated perivascular spaces, and white matter hyperintensities (Fig. 1B–E). She then consulted our hospital for diagnosis. On admission, neurological examination indicated dyscalculia without any other higher cerebral dysfunction. She had choreodystonia of the right hand and foot without parkinsonism or cerebellar ataxia. Although deep tendon reflexes were brisk, the Babinski response was bilaterally negative (suppl. video). Cranial susceptibility-weighted imaging depicted abnormal low-intensity

areas in the bilateral caudate head and dentate nucleus (Fig. 1F–I). ^{123}I -iodoamphetamine (IMP) single-photon emission CT (SPECT) revealed hypoperfusion in the bilateral caudate and dentate nuclei (Fig. 1J). Fundoscopic analysis revealed retinal arteriolar tortuosity (Fig. 1K). Blood examination, blood coagulation tests, and routine chemistry results including copper, iron, and ferritin levels were normal. Urinalysis revealed glomerular hematuria. Findings on dopamine transporter imaging, MR angiography (Fig. 1L, M), and cerebrospinal analysis were normal. Administration of trihexyphenidyl resolved her dystonia.

Supplementary video related to this article can be found at <http://dx.doi.org/10.1016/j.parkreldis.2017.04.009>.

Sequencing for *COL4A1* revealed a previously undescribed c.2494G > A mutation in exon 32, resulting in an amino acid change from glycine to arginine at position 832. *COL4A1* and *COL4A2* form heterotrimers and are crucial components of the vascular basement membranes [1]. Specific alterations of vascular basement membranes due to *COL4A1* mutations frequently result in infantile porocephaly, cerebral small vessel diseases involving both ischemic and hemorrhagic stroke, dilated perivascular spaces, intracranial aneurysm, glomerular hematuria with renal cysts, and retinal arteriolar tortuosity [4]. The patient therefore exhibited typical findings associated with *COL4A1* mutations.

COL4A1 contains three major domains: amino-terminal 7S, collagenous, and carboxy-terminal non-collagenous. The collagenous domain consists of a repeat (Gly-X-Y)_n sequence that is critical for helix formation during collagen assembly. Missense mutations of glycine in the collagen domain might disrupt assembly by a dominant-negative mechanism [1]. Glycine of codon 832 is highly evolutionarily conserved and is in the collagenous domain (Fig. 1A), which describes most identified *COL4A1* mutations [4]. Therefore, although no functional studies were performed, we concluded that this mutation could be pathogenic.

This mutation was not found in her parents, indicating it had occurred *de novo* (Fig. 1A, suppl. doc), and she had no affected family members. It is well known that pathogenic *COL4A1* mutations could occur *de novo*. Therefore, even in the absence of a familial history, a *COL4A1* mutation should be suspected in cases with compatible clinical and radiological findings.

Cranial MRI and ^{123}I -IMP SPECT suggested that hypofunction of the caudate and dentate nuclei might be associated with choreodystonia in the patient. Although mutations in other dystonia-related genes could have contributed to her symptoms, we ruled out the causative genes for primary dystonia and NBIA (suppl. doc). Demierre et al. reported an association between dystonia and the putamino-capsulo-caudate vascular region, and found

<http://dx.doi.org/10.1016/j.parkreldis.2017.04.009>

1353-8020/© 2017 Elsevier Ltd. All rights reserved.

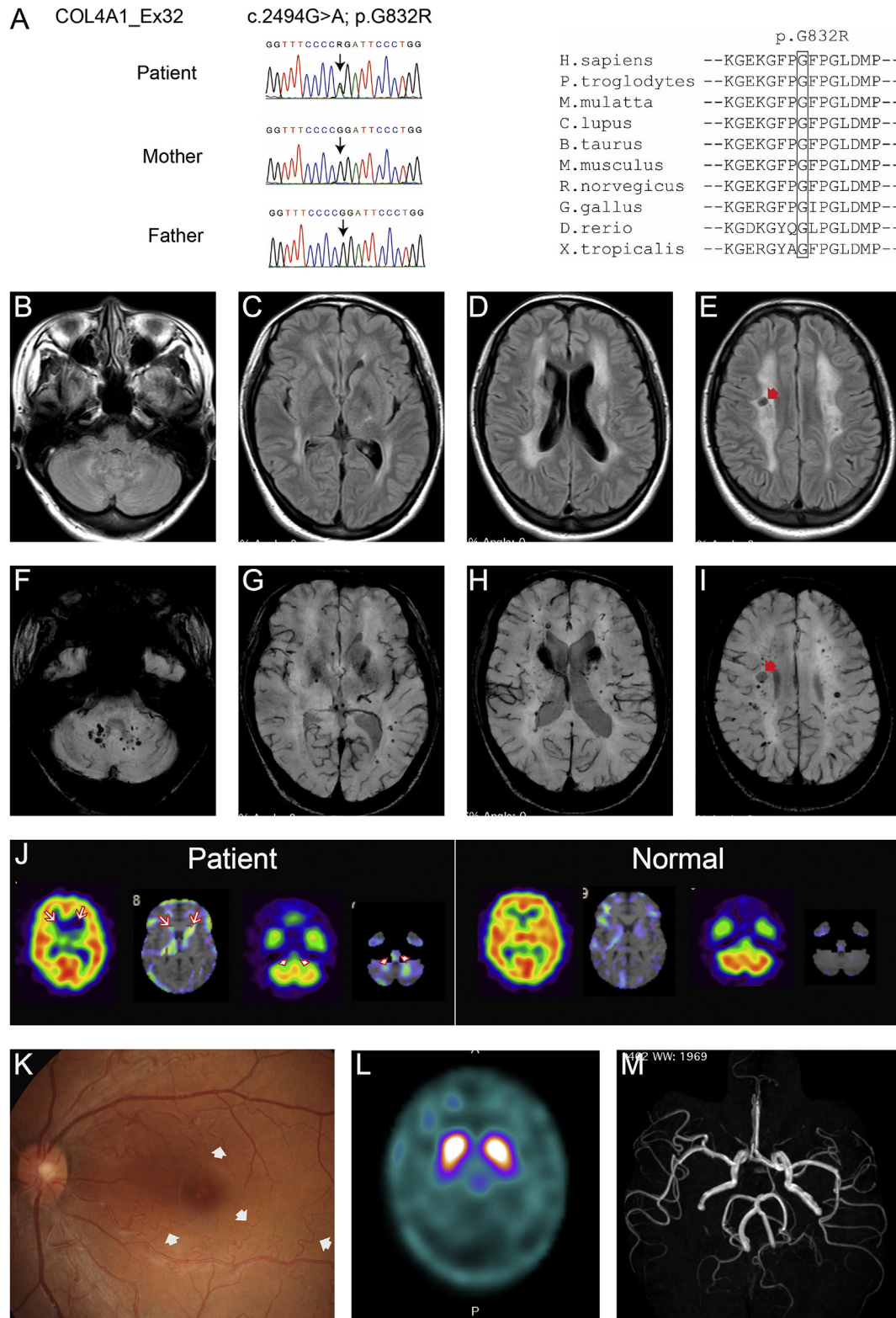


Fig. 1. Genetic, funduscopy, and neuroimaging analyses of the patient. (A) Direct sequencing analysis of *COL4A1* in the patient's family. Arrows indicate sites of heterozygous substitution of *COL4A1* c.2494G > A. Cranial fluid-attenuated inversion-recovery magnetic resonance imaging (MRI) depicted an abnormal low-intensity area in the bilateral caudate head and white matter hyperintensities (B–E). Cranial susceptibility-weighted MRI depicted abnormal low-intensity areas in the bilateral caudate head and dentate nucleus. Scattered spotty low-intensity areas might indicate microbleeds (F–I). Red arrows indicate perivascular dilatation (E, I). (J) ^{123}I -iodoamphetamine single-photon emission computed tomography (SPECT) showed reduced cerebral blood flow in the bilateral caudate (arrows) and dentate nuclei (arrow heads), compared with normal control (51 years-old, male). (K) Funduscopy analysis shows the retinal arteriolar tortuosity (white arrows). (L) Findings on ^{123}I -FP-CIT SPECT were normal, indicative of normal function of the nigrostriatal pathway. (M) Cranial MR angiography findings were normal. (For interpretation of the references to colour in this figure legend, the reader is referred to the web version of this article.)

that the age of onset was under 10 years in the majority of cases, as in this patient [3]. Additionally, hemorrhagic stroke of bilateral dentate nuclei might deteriorate dystonia [5].

To our knowledge, this is the first case of juvenile-onset dystonia likely due to a *COL4A1* mutation. Neurologists should be aware that dystonia with ferritin deposition in the brain might be associated with not only NBIA but also hereditary hemorrhagic stroke, such as *COL4A1* related cerebrovascular disease.

Disclosures

Funding sources

This work was supported by a Strategic Research Foundation Grant-in-Aid for Private Universities; Grants-in-Aid for Scientific Research on Priority Areas (16K09675 to T.H.), a grant for Research on Measures for Intractable Diseases (26310501 to N.M.); a grant for Comprehensive Research on Disability Health and Welfare (13802019 to N.M.); the Strategic Research Program for Brain Science (SRPBS) (11105137 to N.M.); Practical Research Project for Rare/Intractable Diseases (27280301); a grant for Initiative on Rare and Undiagnosed Diseases in Pediatrics (IRUD-P) (15656973 to N.M.), a grant for Initiative on Rare and Undiagnosed Diseases in Adults (IRUD-A) (15664800 to N.M.) from Japan Agency for Medical Research and Development; a Grant-in-Aid for Scientific Research on Innovative Areas (Transcription Cycle) (24118007 to N.M.) from the Ministry of Education, Culture, Sports, Science and Technology of Japan; the fund for Creation of Innovation Centers for Advanced Interdisciplinary Research Areas Program in the Project for Developing Innovation Systems (11105305 to N.M.) from the Japan Science and Technology Agency; and the Takeda Science Foundation (to S.A. and N.M.).

Conflict of interest

The authors have no relevant affiliation or financial involvement with any organization or entity with a financial interest in or financial conflict with the subject matter or materials discussed in the manuscript.

Ethical compliance statement

We confirm that we have read the journal's position on issues involved in ethical publication and affirm that this work is consistent with those guidelines.

Author contributions

T.H. drafting/revising the manuscript, study concept and design, analysis and interpretation of data; accepts responsibility for conduct of research and final approval, acquisition of data, obtaining funding.

K.D. revising the manuscript, analysis and interpretation of data, acquisition of data, study supervision. Y.H. revising the manuscript, analysis and interpretation of data, acquisition of data, study supervision.

Y.L. revising the manuscript, analysis and interpretation of data, acquisition of data, study supervision.

H.S. drafting/revising the manuscript, analysis and interpretation of data; accepts responsibility for conduct of research and final approval, acquisition of data, obtaining funding.

N.M. revising the manuscript, analysis and interpretation of data; accepts responsibility for conduct of research and final

approval, acquisition of data, obtaining funding.

N.H. revising the manuscript, study concept and design, analysis and interpretation of data; accepts responsibility for conduct of research and final approval, acquisition of data.

Appendix A. Supplementary data

Supplementary data related to this article can be found at <http://dx.doi.org/10.1016/j.parkreldis.2017.04.009>.

References

- [1] D.B. Gould, F.C. Phalan, S.E. van Mil, J.P. Sundberg, K. Vahedi, P. Massin, M.G. Bousser, P. Heutink, J.H. Miner, E. Tournier-Lasserre, S.W.M. John, Role of *COL4A1* in small-vessel disease and hemorrhagic stroke, *N. Engl. J. Med.* 354 (2006) 1489–1496.
- [2] T. Hatano, S. Kubo, Y. Nijjima-Ishii, N. Hattori, Y. Sugita, Levodopa-responsive Parkinsonism following bilateral putaminal hemorrhages, *Park. Relat. Disord.* 19 (2013) 477–479.
- [3] B. Demierre, P. Rondot, Dystonia caused by putamino-capsulo-caudate vascular lesions, *J. Neurol. Neurosurg. Psychiatry* 46 (1983) 404–409.
- [4] K. Vahedi, M. Boukobza, P. Massin, D.B. Gould, E. Tournier-Lasserre, M.G. Bousser, Clinical and brain MRI follow-up study of a family with *COL4A1* mutation, *Neurology* 69 (2007) 1564–1568.
- [5] V.G. Shakkottai, A. Batla, K. Bhatia, W.T. Dauer, C. Dresel, M. Niethammer, D. Eidelberg, R.S. Raike, Y. Smith, H.A. Jinnah, E.J. Hess, S. Meunier, M. Hallett, R. Fremont, K. Khodakhah, M.S. LeDoux, T. Popa, C. Gallea, S. Lehericy, A.C. Bostan, P.L. Strick, Current opinions and areas of consensus on the role of the cerebellum in dystonia, *Cerebellum* 16 (2017) 577–594.

Taku Hatano, M.D., PhD.*

Department of Neurology, Juntendo University Graduate School of Medicine, Tokyo, Japan

Kensuke Daida, M.D.

Department of Neurology, Juntendo University Graduate School of Medicine, Tokyo, Japan

Yasunobu Hoshino, M.D.

Department of Neurology, Juntendo University Graduate School of Medicine, Tokyo, Japan

Yuanzhe Li, PhD.

Department of Neurology, Juntendo University Graduate School of Medicine, Tokyo, Japan

Hiroto Saitsu, M.D. PhD

Department of Biochemistry, Hamamatsu University School of Medicine, Hamamatsu, Japan

Department of Human Genetics, Yokohama City University Graduate School of Medicine, Yokohama, Japan

Naomichi Matsumoto, M.D., PhD

Department of Human Genetics, Yokohama City University Graduate School of Medicine, Yokohama, Japan

Nobutaka Hattori, M.D., PhD.

Department of Neurology, Juntendo University Graduate School of Medicine, Tokyo, Japan

* Corresponding author. Department of Neurology, Juntendo University, School of Medicine, 2-1-1 Hongo, Bunkyo-ku, Tokyo 113-8421, Japan.

E-mail address: thatano@juntendo.ac.jp (T. Hatano).

4 December 2016