

# A case report of Sjögren syndrome manifesting bilateral basal ganglia lesions

Bing Niu, PhD, Zhenzhen Zou, MMed, Yuqin Shen, MMed, Bingzhen Cao, MD\*

## Abstract

**Rationale:** Peripheral neurological complications in primary Sjögren's syndrome (pSS) seem the most common, however the involvement of central nervous system (CNS) remains unclear. While abnormalities in pSS revealed by brain magnetic resonance imaging (MRI) are usually small discrete hyperintense areas in the white matter on T2-FLAIR weighted MRI, massive brain lesions have been rarely reported, particularly in bilateral basal ganglia.

**Patient concerns:** A 51-year-old woman exhibited dizziness, slurred speech and hemiplegia as a manifestation of pSS. Brain MRI revealed bilateral and symmetrical lesions extending into the basal ganglia, corona radiata and corpus callosum.

**Diagnoses:** Primary Sjögren's syndrome was diagnosed on the basis of clinical features, abnormal Schirmer's test and tear break-up time (BUT) findings, high levels of anti-Sjögren's-syndrome-related antigen A (anti-SSA) (Ro) and anti-Sjögren's-syndrome-related antigen B (anti-SSB) (La) antibodies, and positive labial minor salivary gland biopsy results.

**Interventions:** She was treated with intravenous methylprednisolone and discharged on oral steroid therapy of prednisolone acetate.

**Outcomes:** The patient had an excellent response to steroid therapy.

**Lessons:** The present case suggests that symmetry bilateral lesions can occur as a symptom of pSS, which could be induced by an autoimmune mechanism.

**Abbreviations:** CNS = central nervous system, MRA = magnetic resonance angiography, MRI = magnetic resonance imaging, SS = Sjögren syndrome.

**Keywords:** basal ganglia, magnetic resonance imaging, pathology, Sjögren syndrome

## 1. Introduction

Sjögren syndrome (SS) is a systemic autoimmune disorder that affects the exocrine glands. The syndrome is characterized by the presence of an inflammatory infiltrate of lymphocytes interfering with the function of the glands confirmed by a biopsy of the labial gland.<sup>[1]</sup> There are 2 clinical forms of SS. The primary form (pSS)

is characterized by dry eye conjunctiva and hyposalivation and the secondary form occurs in conjunction with other connective tissue diseases such as rheumatoid arthritis and lupus erythematosus.<sup>[2]</sup> SS affects 0.01% to 0.1% of the adult population and is more prevalent in women than in men.<sup>[3–5]</sup> The disease overwhelmingly affects middle-aged women but may also affect children, men, and elderly people.<sup>[6]</sup>

Neurological manifestations of pSS are multiple and appear frequently, and peripheral and central neurological manifestations can be found in about 15% and 5% of the pSS cases.<sup>[7]</sup> Peripheral neurological complications are well-defined, particularly sensory-motors axonal neuropathies. The central manifestations of pSS are not uncommon but remains controversial and its clinical presentation varies considerably leading to delay in diagnosis.<sup>[8,9]</sup> Thus, we report a patient with pSS featured brain lesions in bilateral basal ganglia, thalamus, and corona radiata.

## 2. Patient information

A 51-year-old woman was admitted to a community hospital due to numbness and weakness in her left extremities and diagnosed as cerebral infarction in July 2015. Magnetic resonance imaging (MRI) revealed lesions in bilateral basal ganglion and corona radiata (Fig. 1). The symptoms were ameliorated after a therapy of cerebral infarction. However, in October 2015 she developed a symptom of dizziness without obvious predisposing causes, which was followed by right-sided hemiplegia, slurred speech and spotted vision.

### 2.1. Clinical findings

On admission to our hospital, she underwent brain magnetic resonance angiography (MRA) examination, which did not show abnormal blood vessels. Neurological examination showed

Editor: Raouf Hajji.

B.N., Z.Z., and Y.S. contributed equally to this work.

**Informed Consent Statement:** Signed written informed consent forms were obtained from the patient. Because it was not a clinical trial and no off-label drugs were used, the ethical approval is not necessary for this case report.

This work was financially supported by the General Financial Grant from the China Postdoctoral Science Foundation (grant number 2015M572806).

**Authors' contribution:** Y.S., B.C., and Z.Z. diagnosed the patient and made the treatment; B.N. and Z.Z. contributed to the acquisition of the clinical data; B.N. and Z.Z. drafted the manuscript; B.C. revised the manuscript.

The authors report no conflicts of interest.

Department of Neurology, General Hospital of Jinan Military Region, Jinan, Shandong Province, China.

\* Correspondence: Bingzhen Cao, Department of Neurology, General Hospital of Jinan Military Region, Jinan, Shandong Province 250031, China (e-mail: cbzxia2011@163.com).

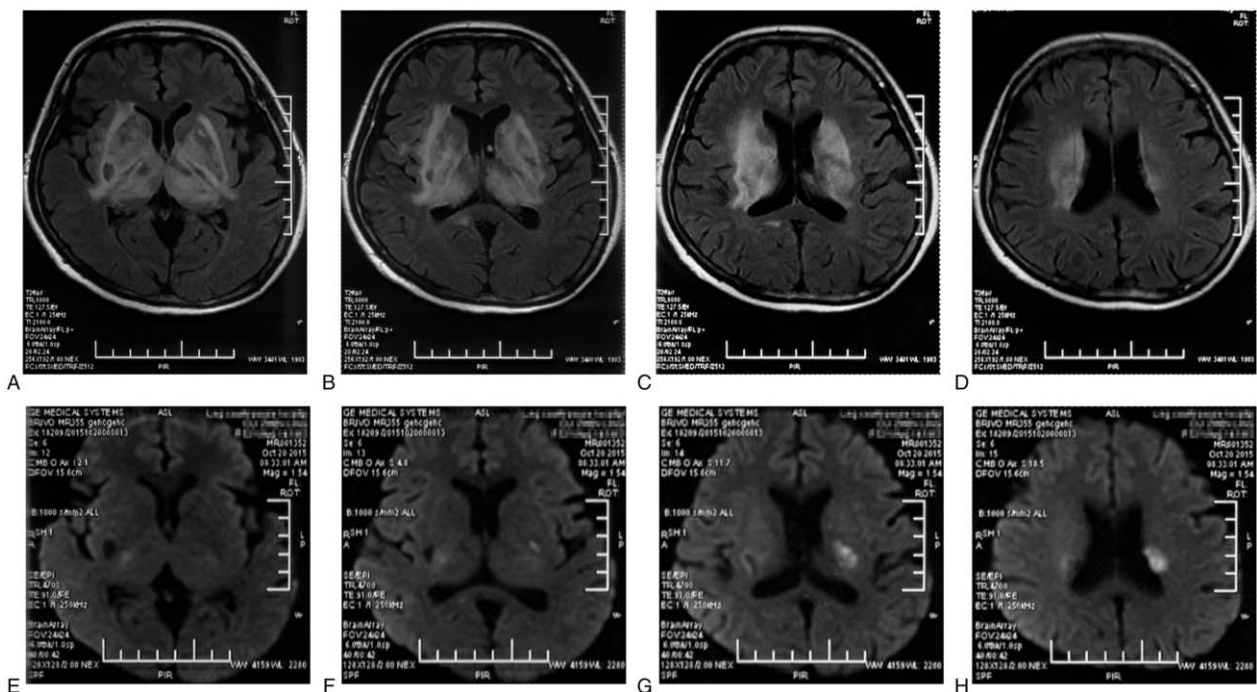
Copyright © 2017 the Author(s). Published by Wolters Kluwer Health, Inc. This is an open access article distributed under the terms of the Creative Commons Attribution-Non Commercial License 4.0 (CCBY-NC), where it is permissible to download, share, remix, transform, and buildup the work provided it is properly cited. The work cannot be used commercially without permission from the journal.

Medicine (2017) 96:17(e6715)

Received: 21 December 2016 / Received in final form: 27 February 2017 /

Accepted: 23 March 2017

http://dx.doi.org/10.1097/MD.0000000000006715



**Figure 1.** Axial magnetic resonance imaging (MRI) revealed massive brain lesions. The lesions were patchy hyperintense on the T2-FLAIR-weighted MRI in bilateral basal ganglion, thalamus (A-C), corona radiata (D), and right corpus callosum (B and C). Diffusion weighted imaging showed hyperintense in bilateral basal ganglion (E-G) and left corona radiata (H).

weakness of extremities and hypermyotonia of left upper limb. Finger-to-nose and heel-to-shin testing revealed dysmetria. Rapid alternating movements were slowed and awkward bilaterally. Deep tendon reflex was graded 3 in the left upper extremity. Bilateral Babinski reflexes and Holmes rebound phenomena were positive.

## 2.2. Diagnostic assessment

Laboratory blood tests reported that the erythrocyte sedimentation rate was 22 mm/h. A lumbar puncture was performed and the intracranial pressure was 160 mmH<sub>2</sub>O. Laboratory examination of the cerebrospinal fluid (CSF) showed increased levels of total protein (0.79 g/L), immunoglobulin (Ig)G (197 mg/L), and CSF albumin (462 mg/L). Glucose and chloride levels were normal. Microbial smear and culture were negative. Isoelectric focusing revealed oligoclonal bands of Ig in serum and CSF.

Immunologic laboratory tests found positive anti-nuclear antibodies at a titer of 1:1000, and positive anti-Sjögren's-syndrome-related antigen A (anti-SSA) (Ro), anti-Sjögren's-syndrome-related antigen B (anti-SSB) (La) and anti-Ro-52 antibodies in serum. However, other immunologic tests of anti-cardiolipin antibodies, beta-2 glycoprotein 1 antibodies, serum protein electrophoresis, anti-NMDAR antibodies in CSF, and anti-AQP4 antibodies and myelin basic protein levels in serum and CSF were negative. The levels of IgG (20.6 g/L), IgE (954 IU/mL), Ig light chain kappa (Igk 5.68 g/L), and Ig light chain lambda (Igl 2.77 g/L) were also detected in serum. Test of serum anti-neutrophil cytoplasmic antibodies (ANCA) showed negative ANCA target myeloperoxidase and ambiguous ANCA target proteinase 3 (PR3), which were both negative in a follow-up examination.

The patient had no history of hypertension, diabetes, hyperlipidemia, and coronary disease. She was a nonsmoker

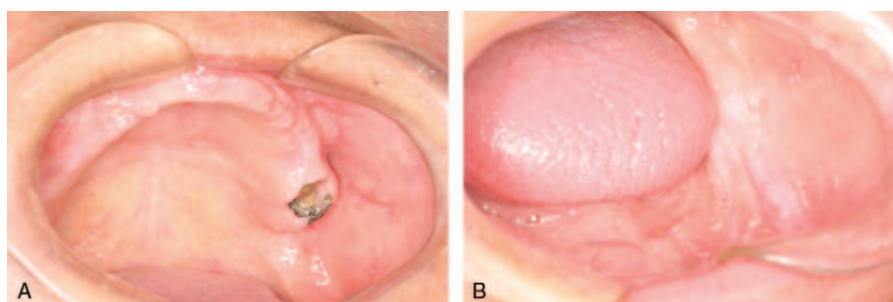
and never drank alcohol. As MRA did not reveal abnormal variation, and the distribution and size of brain lesions were inconsistent with that in atherosclerotic cerebral infarction, we considered that she might experience autoimmune diseases. Thus, we made a detailed inquiry into her medical history and detected some immunological indices, and found that the symptoms of conjunctival dryness, cough, arthralgias, and long-term low-grade fever had frequently manifested since she was about 40 years' old. The patient had been wearing denture, as her teeth turned black gradually in her adolescence and all the teeth were lost in her late 30s (Fig. 2). These symptoms and the immunologic tests suggested that she might experience SS. Then the labial minor salivary gland biopsy, tear break-up time (BUT) test, and Schirmer test were performed. The eye examination revealed a positive Schirmer test (right eye 1.5 mm, left eye 1.5 mm in 5 minutes) and a positive BUT (right eye 8 s, left eye 9 s). The biopsy revealed inflammatory changes with a focus score of 10.7 (Fig. 3). The patient was diagnosed with pSS according to the American-European Consensus Criteria for SS.<sup>[10]</sup>

## 2.3. Therapeutic intervention

She was treated with pulse intravenous methylprednisolone, up to 520 mg/day, for a total of 5 days. The intravenous methylprednisolone was subsequently tapered to 240 mg/day for additional 3 days. She was discharged on oral steroid therapy of 60 mg/day prednisolone acetate.

## 2.4. Follow-up and outcomes

The patient had an excellent response to the treatment, with significant improvement in her dizziness, slurred speech, and right-sided hemiplegia. After 1-month follow-up, she returned to normal except the left-sided hemiplegia, which was a sequela



**Figure 2.** The oral implication. (A and B) Clinical view of the oral cavity showed rampant caries, which suggested an oral implication of Sjögren syndrome.

after the treatment for cerebral infarction in July 2015. Brain MRI showed alleviative lesions (Fig. 4).

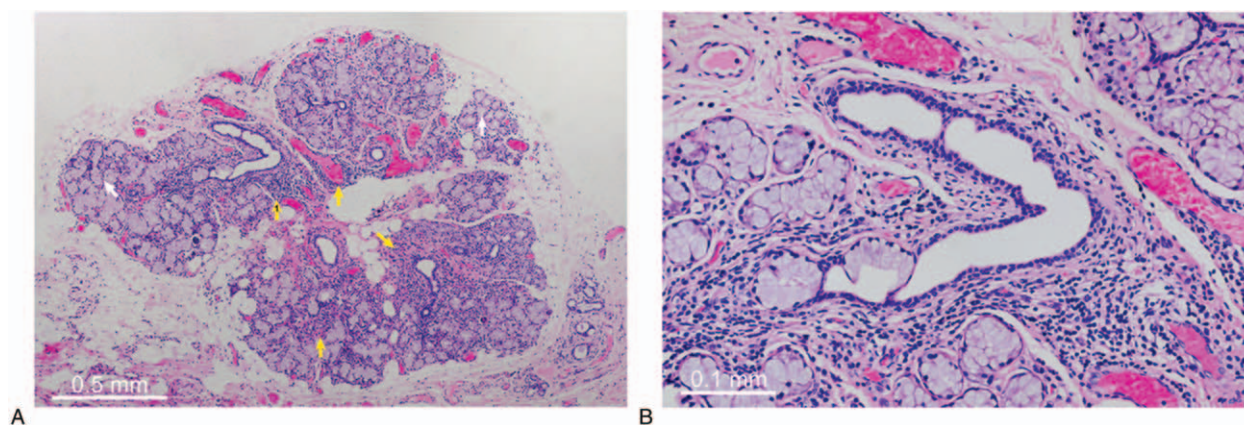
### 3. Discussion

In this report, we describe a case of pSS with massive cerebral lesions, especially in bilateral basal ganglia, as well as thalamus and corona radiata, who had been misdiagnosed with cerebral infarction on admission. Her initial symptoms were a sudden attack of dizziness, slurred speech, and right-sided hemiplegia and MRI revealed T2-weighted hyperintense lesions. As she was middle-aged, these symptoms were similar to the common manifestations of cerebral ischemia. Considering that the patient had no exposure to risk factors for atherosclerosis, the MRA did not reveal abnormal blood vessels, and the lesions showed by MRI were not consistent with the distribution of arteries; she might not be suffering from cerebral ischemia. According to the results of lacrimal gland function examinations, autoantibody investigations, pathological examinations, and the symptom of rampant caries, the patient fulfilled the diagnostic criteria of SS.<sup>[10]</sup>

SS is an autoimmune disease characterized primarily by exocrine gland dysfunction, specifically of the salivary and lacrimal glands, resulting in dry mouth and dry eyes symptoms.<sup>[11–13]</sup> Nervous system involvement has been frequently reported in cases of pSS. The peripheral nervous system neuropathies had been well defined, but the central nervous system (CNS) involvement reports remain controversial. The CNS involvement affects about 5% of the pSS

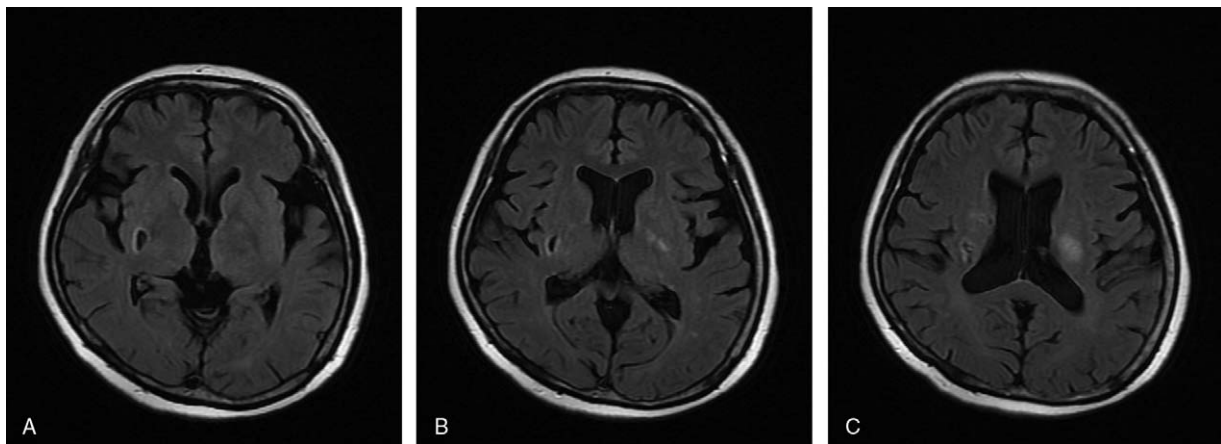
patients,<sup>[7]</sup> and occurs in multiple CNS regions, which may precede or follow the onset of sicca symptoms.<sup>[14]</sup> The CNS involvement is composed by multiple and diffuse manifestations, including cognitive dysfunction, subacute aseptic meningitis, encephalopathy, psychiatric symptoms, chorea, and seizures.<sup>[15]</sup>

The common brain MRI abnormalities in pSS are discrete hyperintense or hypointense areas around the ventricles and subcortical white matter predominantly, without abnormal enhanced scanning. T2-weighted imaging (WI) is more sensitive than T1WI in detection of lesions, and inferior to T2-FLAIR in revealing the extent of lesions.<sup>[16]</sup> The lesion size varies from dot to big flake. However, our patient presented an atypical acute and recurrent clinical symptom mimicking a vascular stroke, and unusual neuroimaging features which showed massive lesions in bilateral basal ganglia, corona radiata, and right corpus callosum. These lesion areas are rarely described in previous reports. Min et al<sup>[17]</sup> reported a 72-year-old pSS patient with swelling in bilateral basal ganglia lesions, which is similar to our case. The underlying pathogenesis of CNS complications in pSS remains unknown. Previous studies have suggested mechanisms of ischemia, mononuclear cell infiltration, and immunologically mediated CNS vascular damage.<sup>[18]</sup> Autopsies found perivascular lymphocytic infiltration and demyelination in the CNS of pSS patients.<sup>[19,20]</sup> The lymphocytic infiltration in the labial salivary gland and the excellent response to steroid therapy of basal ganglia lesions indicated autoimmunity induced by lymphocytic infiltration in the CNS of our patient. CNS vasculitis



**Figure 3.** The salivary gland biopsy. Hematoxylin and eosin staining of the minor labial salivary gland biopsy specimen, obtained through normal-appearing mucosa. The focus score was defined as the number of lymphocytic foci containing >50 lymphocytes, adjacent to normal-appearing mucous acini, per 4 mm<sup>2</sup> of glandular tissue. 22 lymphocytic foci were found in the salivary gland tissue, and the total area of the glands was 8.2 mm<sup>2</sup>. (A) A part of the gland tissue at low power magnification. The image was merged from photos at 100× magnification, showing several lymphocytic foci (yellow arrows) and intact acinar units (white arrows). (B) A high-power magnification view was merged from images at 400× magnification, showing a lymphocytic focus (yellow arrow #1 in A).





**Figure 4.** The lesions were partially resolved on a follow-up magnetic resonance imaging (MRI) examination performed 1 month after discharge. The T2-FLAIR-weighted MRI showed that the lesions in bilateral basal ganglion, thalamus, and corpus callosum were resolved (A and B). The hyperintense remained in left corona radiata (C).

might also be involved considering the small foci of encephalomalacia in MRI.

Many studies suggest that IgA play an important role in the pathological mechanism of pSS,<sup>[21]</sup> but in this patient it is the serum IgG and IgE that increased significantly. Perhaps the CNS lesions in pSS may be induced by IgG and IgE, whereas the gland lesions may be mediated by IgA. The increased levels of IgG and IgE reflect the disorder of B lymphocytes. Accumulated evidence has suggested that B cells play an important role in the pathogenesis of pSS.<sup>[22]</sup> Recently, the polymorphisms of *BANK1* (B-cell scaffold protein with ankyrin repeats 1) and *FAM167A* (family with sequence similarity 167 member A) are reported as susceptibility factors for SS.<sup>[23,24]</sup> Thus, the dysfunction of B cells may be a therapeutic target for pSS.

In conclusion, this case suggests that SS should be considered in case of bilateral basal ganglia lesions. The pathogenesis of CNS lesions may be autoimmunity induced by lymphocytic infiltration, which has an excellent response to steroid therapy.

## Acknowledgments

The authors thank Dr. Shucui Wang (Department of Neurology, General Hospital of Jinan Military Region) for advice and Wei Wang (Department of Medical Imaging, General Hospital of Jinan Military Region) for technical assistance.

## References

- [1] Fisher BA, Brown RM, Bowman SJ, et al. A review of salivary gland histopathology in primary Sjogren's syndrome with a focus on its potential as a clinical trials biomarker. *Ann Rheum Dis* 2015;74:1645–50.
- [2] Baldini C, Talarico R, Tzioufas AG, et al. Classification criteria for Sjogren's syndrome: a critical review. *J Autoimmun* 2012;39:9–14.
- [3] Maldini C, Seror R, Fain O, et al. Epidemiology of primary Sjogren's syndrome in a French multiracial/multiethnic area. *Arthritis Care Res* 2014;66:454–63.
- [4] Qin B, Wang J, Yang Z, et al. Epidemiology of primary Sjogren's syndrome: a systematic review and meta-analysis. *Ann Rheum Dis* 2015;74:1983–9.
- [5] Maciel G, Crowson CS, Matteson EL, et al. Prevalence of primary Sjogren's syndrome in a population-based cohort in the United States. *Arthritis Care Res* 2016;DOI 10.1002/acr.23173.
- [6] Ramos-Casals M, Brito-Zeron P, Siso-Almirall A, et al. Primary Sjogren syndrome. *Bmj* 2012;344:e3821.
- [7] Carvajal Alegria G, Guellec D, Mariette X, et al. Epidemiology of neurological manifestations in Sjogren's syndrome: data from the French ASSESS Cohort. *RMD Open* 2016;2:e000179.
- [8] Soliotis FC, Mavragani CP, Moutsopoulos HM. Central nervous system involvement in Sjogren's syndrome. *Ann Rheum Dis* 2004;63:616–20.
- [9] Carvajal Alegria G, Guellec D, Devauchelle-Pensec V, et al. Is there specific neurological disorders of primary Sjogren's syndrome? *Joint, Bone, Spine* 2015;82:86–9.
- [10] Vitali C, Bombardieri S, Jonsson R, et al. Classification criteria for Sjogren's syndrome: a revised version of the European criteria proposed by the American-European Consensus Group. *Ann Rheum Dis* 2002;61:554–8.
- [11] Nguyen CQ, Peck AB. Unraveling the pathophysiology of Sjogren syndrome-associated dry eye disease. *Ocul Surf* 2009;7:11–27.
- [12] Lee BH, Tudares MA, Nguyen CQ. Sjogren's syndrome: an old tale with a new twist. *Arch Immunol Ther Exp* 2009;57:57–66.
- [13] Delaleu N, Jonsson R, Koller MM. Sjogren's syndrome. *Eur J Oral Sci* 2005;113:101–13.
- [14] Mori K, Iijima M, Koike H, et al. The wide spectrum of clinical manifestations in Sjogren's syndrome-associated neuropathy. *Brain* 2005;128(Pt 11):2518–34.
- [15] Fauchais AL, Magy L, Vidal E. Central and peripheral neurological complications of primary Sjogren's syndrome. *Presse Med* 2012;41(9 pt 2):e485–93.
- [16] Manabe Y, Sasaki C, Warita H, et al. Sjogren's syndrome with acute transverse myelopathy as the initial manifestation. *J Neurol Sci* 2000;176:158–61.
- [17] Min JH, Youn YC. Bilateral basal ganglia lesions of primary Sjogren syndrome presenting with generalized chorea. *Parkinsonism Relat Disord* 2009;15:398–9.
- [18] Delalande S, de Seze J, Fauchais AL, et al. Neurologic manifestations in primary Sjogren syndrome: a study of 82 patients. *Medicine* 2004;83:280–91.
- [19] Ichikawa H, Ishihara K, Fujimoto R, et al. An autopsied case of Sjogren's syndrome with massive necrotic and demyelinating lesions of the cerebellar white matter. *J Neurol Sci* 2004;225:143–8.
- [20] Yaguchi H, Houzen H, Kikuchi K, et al. An autopsy case of Sjogren's syndrome with acute encephalomyelopathy. *Intern Med* 2008;47:1675–80.
- [21] Selmi C, Meroni PL, Gershwin ME. Primary biliary cirrhosis and Sjogren's syndrome: autoimmune epithelitis. *J Autoimmun* 2012;39:34–42.
- [22] Mariette X. Therapeutic potential for B-cell modulation in Sjogren's syndrome. *Rheum Dis Clin North Am* 2008;34:1025–33. x.
- [23] Reksten TR, Johnsen SJ, Jonsson MV, et al. Genetic associations to germinal centre formation in primary Sjogren's syndrome. *Ann Rheum Dis* 2014;73:1253–8.
- [24] Sun F, Xu J, Wu Z, et al. Polymorphisms in the *FAM167A*-*BLK*, but not *BANK1*, are associated with primary Sjogren's syndrome in a Han Chinese population. *Clin Exp Rheumatol* 2013;31:704–10.