

Spontaneous Resolution of Cerebral Pial Arteriovenous Fistula After Angiography: Report of Two Cases

Takeshi Satow¹, Megumu Suzuki¹, Taro Komuro¹, Masafumi Ogawa², Akira Kobayashi¹, Sei Nishida³

Key words

- Cerebral angiogram
- Cerebral blood flow
- Headache
- Pial arteriovenous fistula
- Spontaneous resolution

Abbreviations and Acronyms

AVF: Arteriovenous fistula

CT: Computed tomography

MRI: Magnetic resonance imaging

SPECT: Single-photon emission computed tomography

From the Departments of ¹Neurosurgery and ²Neurology, Nagahama City Hospital, Nagahama; and ³Department of Neurosurgery, Kyoto University Graduate School of Medicine, Kyoto, Japan

To whom correspondence should be addressed:

Takeshi Satow, M.D., Ph.D.

[E-mail: satowtake@gmail.com]

Citation: *World Neurosurg.* (2017).

<http://dx.doi.org/10.1016/j.wneu.2017.04.155>

Journal homepage: www.WORLDNEUROSURGERY.org

Available online: www.sciencedirect.com

1878-8750/\$ - see front matter © 2017 Elsevier Inc. All rights reserved.

INTRODUCTION

Pial arteriovenous fistula (AVF) is an extremely rare intracranial vascular lesion, consisting of 1 or more supply arteries in direct connection to the venous drainage without any intervening nidus. Because of its rarity, its natural history and appropriate treatment are yet to be established. Most investigators have proposed the efficacy of disconnection of AVF via direct surgery or endovascular surgery, but not observation.^{1,2}

Many cases of spontaneous closure of dural AVF³⁻⁸ or carotid cavernous sinus fistula⁹⁻¹² have been reported in the literature, whereas spontaneous resolution of pial AVF is extremely rare; only a single case has been reported.¹³ We present here 2 further cases of pial AVF that resolved spontaneously soon after cerebral angiogram, in association with normalization of cerebral blood flow. We emphasize the importance of considering pial AVF as a possible cause

■ **BACKGROUND:** Cerebral pial arteriovenous fistula (AVF) is a rare disorder, and its natural course is uncertain. The present article reports 2 rare cases of pial AVF that underwent spontaneous cure after diagnostic cerebral angiogram.

■ **CASE DESCRIPTIONS:** A 73-year-old man presented with generalized seizure and reported severe but intermittent headache in the right temporo-occipital area. Single-photon emission computed tomography (SPECT) showed hyperperfusion in that area. The main finding of a cerebral angiogram was an arteriovenous shunt at the cortical surface of the right temporal area. Soon after this diagnostic angiogram, the symptoms vanished. A further cerebral angiogram showed the disappearance of this pial AVF, and a SPECT study showed resolution of the hyperperfusion of the affected area.

A 69-year-old man, with a history of intracerebral hemorrhage on the left parietal area 3 years earlier, presented with speech disturbance and headache on his left side. SPECT showed hyperperfusion in the left temporoparietal area. A cerebral angiogram showed an arteriovenous shunt at the surface of the left parietal area. During the same cerebral angiogram session, the pial AVF disappeared after the third injection of a contrast medium with magnification. Two days after the cerebral angiogram, the patient's headache disappeared and speech disturbance gradually improved. SPECT also showed disappearance of the hyperperfusion.

■ **CONCLUSIONS:** It is possible that pial AVF is a cause of headache and neurologic symptoms in association with focal hyperperfusion. Diagnostic cerebral angiography should be performed to make a definite diagnosis; after this, pial AVF sometimes disappears.

in patients manifesting localized headache and neurologic deficits or seizure disorders.

CASE DESCRIPTIONS

Patient 1

A 73-year-old man with a history of atrial fibrillation, hypertension, and migraine was taken to our hospital by ambulance because of a sudden disturbance of consciousness followed by generalized tonic-clonic seizure. Diazepam readily put an end to the seizure, and he was admitted for further evaluation. He also had a history of head injury without neurosurgical intervention at age around 20 years. For the last 3 years, he had had several episodes of migraine, with visual aura.

Lomerizine was prescribed and gave partial relief of this symptom.

On the next day after admission, the patient was alert and oriented. He did not show any deficit in cranial nerves or sensorimotor function of extremities. He showed hemispatial neglect on the left side and reported severe but intermittent headache in the right temporoparieto-occipital area. Acetaminophen was partially effective for relieving this headache, but rizatriptan was not. Antiepileptic drugs (levetiracetam and topiramate) controlled his epileptic seizure; he did not experience any seizure after hospitalization.

Blood examination was unexceptional. Viral encephalitis and metabolic encephalopathy were considered as possible causes, but the results of a cerebrospinal fluid study

were not abnormal, including cell count, protein, glucose, and lactic and pyruvic acids. Brain computed tomography (CT) did not show any hemorrhagic abnormality. Magnetic resonance imaging (MRI) of the brain showed a slight hyperintensity area in the right temporal area on diffusion-weighted imaging, distinct from old ischemic changes (**Figure 1A** and **B**). Electroencephalography showed focal slowing in the frontotemporal area on the

right side. ^{99m}Tc -single-photon emission CT (SPECT) showed hyperperfusion in the right temporoparietal area (**Figure 1C**). Antiepileptic drugs were gradually increased and other migraine relief was added, but the patient's migrainous headache did not improve. About 2 weeks after admission, MRI of the brain showed an apparent relative high intensity of the cortical ribbon in the right temporoparietal area (**Figure 1D** and **E**).

SPECT at this time showed persistent hyperperfusion in the corresponding areas (**Figure 1F**). A cerebral angiogram was then performed with the use of Oypalomin 300 (FujiPharma Co., Ltd., Toyama, Japan). On a right internal carotid angiogram, the vein of Labbé was opacified through the branches of the middle cerebral artery in the later arterial phase (**Figure 2A** and **B**). As a result, a pial AVF was diagnosed. Other pathologic

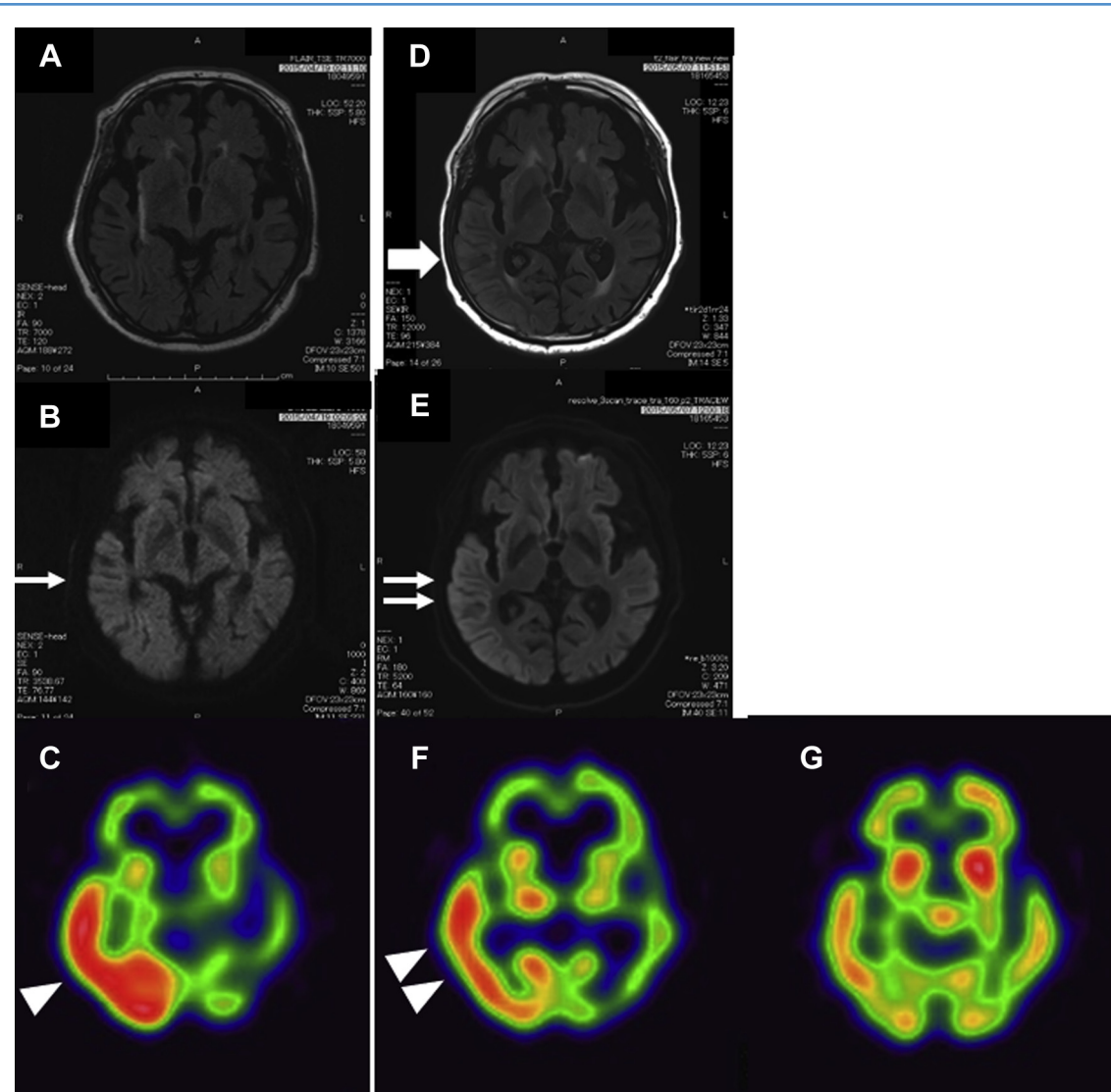


Figure 1. Patient 1. (**A**) Fluid-attenuated inversion recovery and (**B**) diffusion-weighted imaging (DWI) magnetic resonance imaging on admission showed only slight hyperintensity in the right temporal lobe (white arrow) according to DWI. Single-photon emission computed tomography (SPECT) 2 days after admission (**C**) showed hyperperfusion in the corresponding area (white arrowhead). Repeated magnetic resonance imaging

taken 18 days after admission clearly showed hyperintensity not only with DWI (**E**) (double white arrows) but also with fluid-attenuated inversion recovery (**D**) (thick white arrow), whereas SPECT (**F**) showed persistent hyperperfusion (double white arrowhead). SPECT (**G**) taken when the headache had disappeared showed that hyperperfusion had ceased.

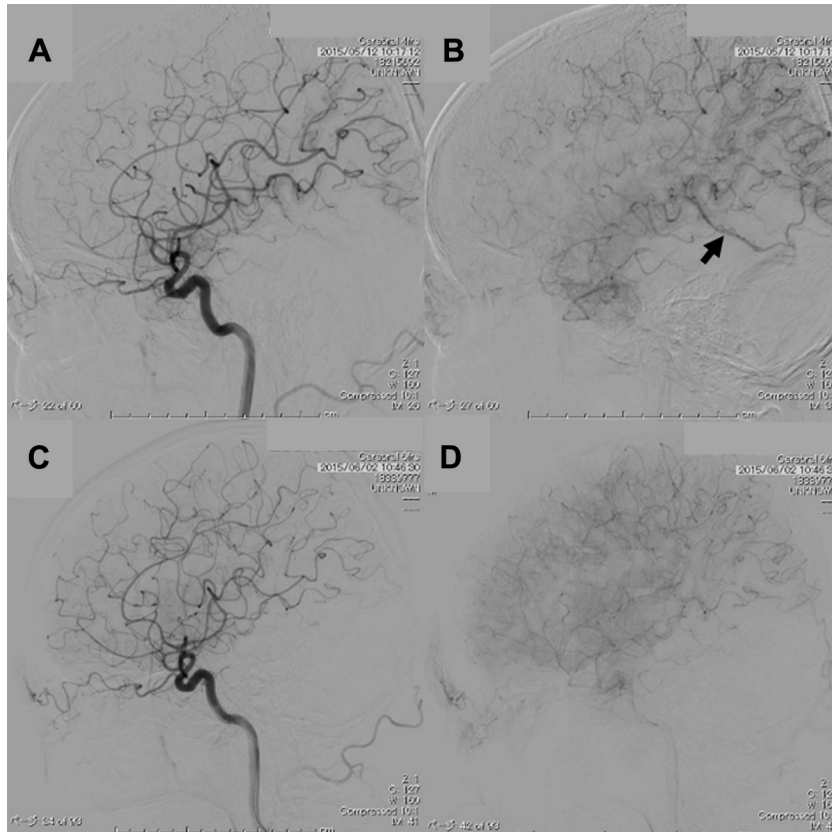


Figure 2. Right internal carotid angiogram of patient 1. Arterial (A) and late arterial phase (B) of initial angiogram. Vein of Labbé (arrow) was opacified through the cortical branch of the middle cerebral artery. Repeated angiogram showed that the early filling of vein of Labbé disappeared in the arterial (C) and late arterial phase (D).

findings, such as dural sinus thrombosis, atherosclerotic steno-occlusive disease, and so on, were not observed.

Immediately after the angiogram, the patient's headache subsided, without prescription of analgesics. SPECT was repeated at 17 days after the cerebral angiogram and showed the normalization of cerebral blood flow (Figure 1G). A cerebral angiogram performed 21 days after the first angiogram confirmed complete disappearance of all arteriovenous shunt (Figure 2C and D). The hemispatial neglect also recovered, and the patient was discharged home without any neurologic deficits.

During hospitalization, the patient did not experience any episode of hypotension.

During the follow-up period, lasting 21 months, his headache and other symptoms did not recur and he was able to resume social activities as before. However, MRI showed an atrophic change of the right temporo-occipital area.

Patient 2

A 69-year-old man, who had a history of hypertensive subcortical intracranial hemorrhage in the left parietal area 3 years earlier, visited our outpatient clinic reporting aphasia, alexia, and a headache in the left temporoparietal area. CT and MRI (Figure 3A and B) did not show any recent hemorrhagic or ischemic strokes, and electroencephalography did not show any epileptiform discharges. Antiepileptics were prescribed on the assumption of subclinical seizure, but were not effective.

^{99m}Tc-SPECT showed a region of hyperperfusion in the left parietal area (Figure 3C). A diagnostic cerebral angiogram was conducted with the use of Oypalomin 300 (FujiPharma Co., Ltd., Toyama, Japan). On an angiogram of the left internal carotid artery, the ascending cortical vein at the parietal area was opacified through the cortical branch of the middle cerebral artery in the late

arterial phase (Figure 4A and B). Injection into the left carotid artery of a contrast medium was repeated twice more, to elucidate the shunt point on magnification. Surprisingly, at the third injection before a left carotid angiogram, the arteriovenous shunt disappeared (Figure 4C and D). No other pathologic conditions were found.

Two days after the cerebral angiogram, the patient's headache disappeared and his speech disturbance gradually improved. MRI (Figure 3D and E) did not show any obvious change, but SPECT (Figure 3F) conducted 11 days after the cerebral angiogram showed that the hyperperfusion had disappeared. Repeated cerebral angiography also confirmed that the pial AVF had been cured.

The patient did not experience any episode of hypotension during hospitalization. During the follow-up period of 6 months, the patient did not experience any recurrent symptoms.

DISCUSSION

We have documented 2 cases of pial AVF manifesting headache and neurologic deficits/seizure. Both showed hyperperfusion in the affected area, which resolved reasonably soon after a diagnostic cerebral angiogram, in parallel with improvement in neurologic symptoms.

Intracranial pial AVFs have only recently been considered as distinct from AVMs.¹⁴ They consist of 1 or more arterial connections to a single venous channel without any intervening nidus. Isolated pial AVF comprises rare congenital lesions, usually presenting during infancy or early childhood, which may occur sporadically or be associated with hereditary disorders such as Rendu-Osler-Weber disease,¹⁵ or other genetic vasculopathies. Extremely rarely, acquired pial AVF in adults has been reported as an idiopathic form¹⁶ or in association with trauma,¹⁷ or as cerebral venous thrombosis¹⁸ or as part of a history of neurosurgical treatment.¹⁹ According to the recent review by Yang et al.,²⁰ cerebral pial AVF presents most commonly with a mass (45.8%), seizure disorder (27.7%), or hemorrhage (32.5%). After treatment with surgical or endovascular flow disconnection, the total obliteration rate was found to be 90.2%. In the present 2

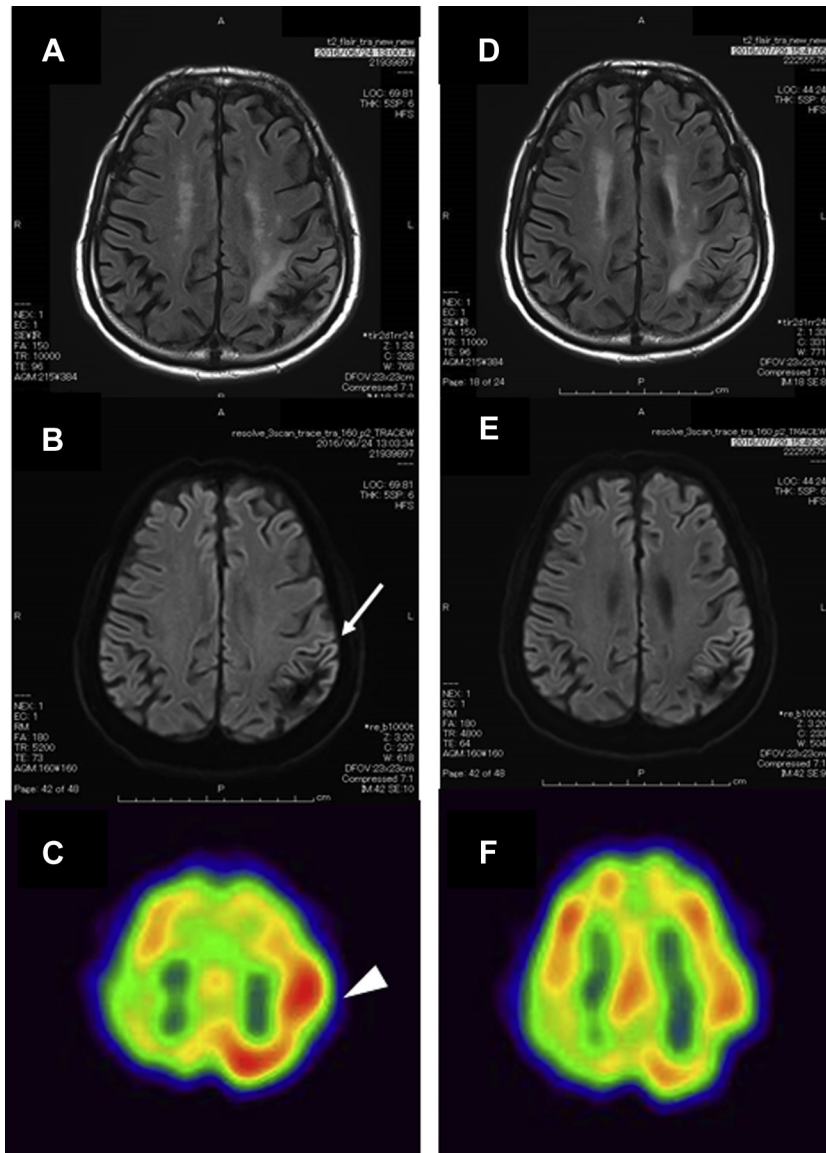


Figure 3. Patient 2. (A) Fluid-attenuated inversion recovery and (B) diffusion-weighted imaging (DWI) magnetic resonance imaging on admission show only slight hyperintensity of the cortical ribbon around a trace of previous intracerebral hemorrhage on DWI (white arrow) in association with hyperperfusion on single-photon emission computed tomography (C) (white arrowhead). When the patient's symptoms subsided after diagnostic cerebral angiography, magnetic resonance imaging (D, fluid-attenuated inversion recovery; E, DWI) did not show any apparent change, but single-photon emission computed tomography (F) showed recovery of hyperperfusion in the left parietal area.

cases, patient 1 had a history of head trauma about 50 years previously (no detailed description could be given), and patient 2 had a history of intracerebral hemorrhage. Neither had a history of neurosurgical intervention. The causal relationship between their medical history and the emergence of pial AVF remains uncertain.

Several cases of spontaneous closure of cavernous sinus fistula after angiography have been reported.⁹⁻¹² Postulated mechanisms include systemic hypotension,⁹ local pressure gradient induced by cerebral angiography,¹² and irritability induced by the contrast medium.^{10,11} Spontaneous cure of dural AVF has also been reported.³⁻⁸ Plausible mechanisms for this

situation include recanalization of the occluded dural sinus,⁸ thrombosis caused by intravascular turbulence,⁴ and compression of the unique feeding artery by hematoma or edema.³ The 2 patients in the present report did not have systemic hypotension during hospitalization, acute hemorrhage, edema, or occlusion of dural sinuses before the spontaneous cure of their pial AVF. We therefore believe that diagnostic cerebral angiography per se could be a factor in the spontaneous cure of pial AVF, at least, in our 2 patients.

Radiologic contrast media are known to have endothelial toxicity, causing inflammation, thrombosis, altered vasomotor balance with predominant vasoconstrictive response, and other effects,²¹ particularly in the presence of underlying vascular disease.²² Among various factors of contrast agent, it is well known that hyperosmolality of the contrast media (Oypalomin 300 used in the present study is about twice the serum osmolality) can cause injury or dysfunction of vascular endothelial cells²³; one of the mechanisms is advocated to be apoptosis.²⁴ Furthermore, although contrast media injection is known to cause both vasodilation and vasoconstriction, vasoconstriction is reported to predominate in patients with atherosclerosis.²⁵ Because the patients' symptoms improved soon after the cerebral angiogram, it is reasonable that diagnostic cerebral angiography or contrast media used plays some role in closure of pial AVF in these patients.

Santosh et al.¹³ reported the only case of pial AVF to disappear spontaneously 10 days after cerebral angiogram. Three days before confirmation that pial AVF had been cured (i.e., 7 days after the initial cerebral angiogram), the patient experienced sudden onset of localized headache and cessation of tinnitus. The investigators suggested that the angiogram hastened the natural process of spontaneous thrombosis within the fistula.

Reul et al.⁵ included, in their case series of anterior cranial fossa dural AVF, the situation of spontaneous cure during cerebral angiogram, as in our patient 2. These investigators did not discuss any mechanism related to cerebral angiography. Based on the finding that pial AVF disappeared relatively soon after cerebral angiography

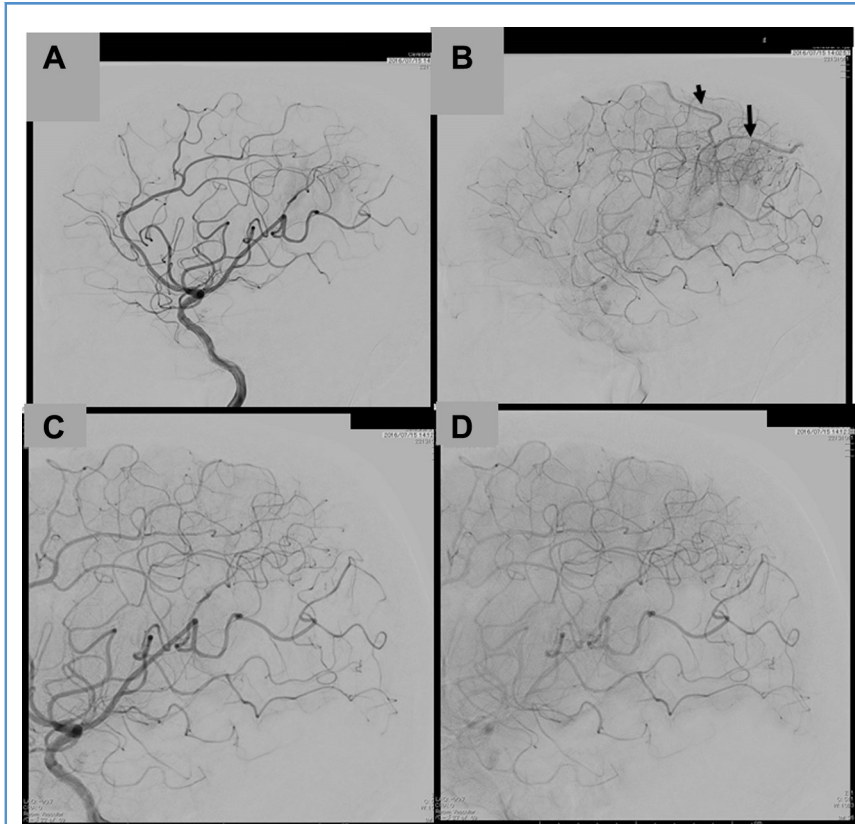


Figure 4. Left internal carotid angiogram of patient 2. Arterial (A) and late arterial phase (B) of initial angiogram. Ascending cortical veins (arrows) were opacified through the cortical branch of the middle cerebral artery in the late arterial phase. Repeated angiogram in the same session showed that the early filling of veins disappeared in the arterial (C) and late arterial phase (D).

in patient 1, or even during the same angiography session as in patient 2, the direct effect of contrast media on the fistula is a plausible cause.

In a 2-case report of spontaneous closure of dural AVF after digital subtraction angiography, Voormolen et al.⁷ proposed an effect of contrast media on the endothelium of the feeding arteries as a cause of spontaneous closure after digital subtraction angiography. Importantly, they used the similar contrast medium Ominipaque 300 as we did. They postulated that thrombi, formed where the contrast medium contacts the vascular endothelium, occlude the shunt point. The effect of the contrast medium need not be direct on the feeding arteries, because 1 report⁶ described a patient whose transverse sinus dural AVF closed spontaneously after cardiac angiography.

We do not necessarily recommend the policy of observation of pial AVF.

Although no neurologic sequelae have taken place in patient 1, the right temporal lobe, which was exposed to the congestive state because of untreated pial AVF, underwent remarkable atrophic change. It is therefore important to keep in mind and to diagnose this disease as early as possible. In addition, pial AVF might be concealed in a subset of patients with migraine,²⁶ because a patient with migraine manifesting hemiparesis is usually diagnosed as having hemiplegic migraine. Cerebral pial AVF should be considered on encountering a patient showing a combination of neurologic deficits/seizure disorder, headache, and hyperperfusion according to cerebral blood flow study.

CONCLUSIONS

Spontaneous resolution of cerebral pial AVF might occur in association with

normalization of impaired cerebral blood flow. This situation might be caused by a reaction to the contrast medium during cerebral angiography.

REFERENCES

1. Hoh BL, Putman CM, Budzik RF, Ogilvy CS. Surgical and endovascular flow disconnection of pial single-channel arteriovenous fistulae. *Neurosurgery*. 2001;49:1351-1364.
2. Nelson PK, Niimi Y, Lasjaunias P, Berenstein A. Endovascular embolization of congenital intracranial pial arteriovenous fistulas. *Neuroimaging Clin North Am*. 1992;2:309-317.
3. Clarençon F, Biondi A, Sourour NA, Maria FD, Iosif C, Nouet A, et al. Spontaneous closure of intracranial dural arteriovenous fistulas: a report of 3 cases. *Clin Neurol Neurosurg*. 2013;115:971-975.
4. Kataoka K, Taneda M. Angiographic disappearance of multiple dural arteriovenous malformations. Case report. *J Neurosurg*. 1984;60:1275-1278.
5. Reul J, Thron A, Laborde G, Brückmann H. Dural arteriovenous malformations at the base of the anterior cranial fossa: report of nine cases. *Neuroradiology*. 1993;35:388-393.
6. Saito A, Furuno Y, Nishimura S, Kamiyama H, Nishijima M. Spontaneous closure of transverse sinus dural arteriovenous fistula: case report. *Neurol Med Chir (Tokyo)*. 2008;48:564-568.
7. Voormolen V, Geens K, Van Den Hauwe L, Parizel PM. Spontaneous closure of cerebral dural arteriovenous fistulas with direct cortical venous drainage. A case report. *Interv Neuroradiol*. 2009;15:359-362.
8. Warren DJ, Craven I, Romanowski CA, Coley SC. Spontaneous closure of a type 2a dural arteriovenous fistula following late recanalization of the occluded sinus. *Interv Neuroradiol*. 2010;16:282-285.
9. Bennett DR, Van Dyk HJL, Davis DO. Carotid cavernous sinus fistula closure following angiography. *JAMA*. 1973;224:1637-1639.
10. Parsons TC, Guller EJ, Wolff HG, Dunbar HS. Cerebral angiography in carotid cavernous communications. *Neurology*. 1954;4:65-68.
11. Potter JM. Carotid-cavernous fistula: five cases with "spontaneous" recovery. *BMJ*. 1954;2:786-788.
12. Voigt K, Sauer M, Dichgans J. Spontaneous occlusion of a bilateral carotid-cavernous fistula studied by serial angiography. *Neuroradiology*. 1971;2:207-211.
13. Santosh C, Teasdale E, Molyneux A. Spontaneous closure of an intracranial middle cerebral arteriovenous fistula. *Neuroradiology*. 1991;33:65-66.
14. Lasjaunias P, Manelfe C, Chiu M. Angiographic architecture of intracranial vascular malformations and fistulas: pretherapeutic aspects. *Neurosurg Rev*. 1986;9:253-263.
15. Garcia-Monaco R, Taylor W, Rodesch G, Alvarez H, Burrows P, Coubes P, et al. Pial arteriovenous fistula in children as presenting manifestation of Rendu-Osler-Weber disease. *Neuroradiology*. 1995;37:60-64.

16. Yamashita K, Ohe N, Yoshimura S, Iwama T. Intracranial pial arteriovenous fistula. Case report. *Neurol Med Chir (Tokyo)*. 2007;47:550-554.
17. Nomura S, Ishikawa O, Tanaka K, Otani R, Miura K, Maeda K. Pial arteriovenous fistula caused by trauma: a case report. *Neurol Med Chir (Tokyo)*. 2015;55:856-858.
18. Phatouros CC, Halbach VV, Dowd CF, Lempert TE, Malek AM, Meyers PM, et al. Acquired pial arteriovenous fistula following cerebral vein thrombosis. *Stroke*. 1999;30:2487-2490.
19. Schuette AJ, Blackburn SL, Barrow DL, Cawley CM. Pial arteriovenous fistula resulting from craniotomy. *World Neurosurg*. 2012;77:785.e1-785.e2.
20. Yang WH, Lu MS, Cheng YK, Wang TC. Pial arteriovenous fistula: a review of literature. *Br J Neurosurg*. 2011;25:580-585.
21. Scoditti E, Massaro M, Montinari MR. Endothelial safety of radiological contrast media: why being concerned. *Vascul Pharmacol*. 2013;58:48-53.
22. Junck L, Marshall WH. Neurotoxicity of radiological contrast agents. *Ann Neurol*. 1983;13:469-484.
23. Zhang H, Holt CM, Malik N, Shepherd L, Morcos SK. Effects of radiographic contrast media on proliferation and apoptosis of human vascular endothelial cells. *Br J Radiol*. 2000;73:1034-1041.
24. Sawmiller CJ, Powell RJ, Quader M, Dudrick SJ, Sumpio BE. The differential effect of contrast agents on endothelial cell and smooth muscle cell growth in vitro. *J Vasc Surg*. 1998;27:1128-1140.
25. Limbruno U, Petronio AS, Amoroso G, Baglini R, Paterni G, Merelli A, et al. The impact of coronary artery disease on the coronary vasomotor response to nonionic contrast media. *Circulation*. 2000;101:491-497.
26. Headache Classification Committee of the International Headache Society (IHS). The International Classification of Headache Disorders, 3rd edition (beta version). *Cephalalgia*. 2013;33:629-808.

Conflict of interest statement: The authors declare that the article content was composed in the absence of any commercial or financial relationships that could be construed as a potential conflict of interest.

Received 22 February 2017; accepted 24 April 2017

Citation: *World Neurosurg*. (2017).

<http://dx.doi.org/10.1016/j.wneu.2017.04.155>

Journal homepage: www.WORLDNEUROSURGERY.org

Available online: www.sciencedirect.com

1878-8750/\$ - see front matter © 2017 Elsevier Inc. All rights reserved.