

JNS 03094

Progression from MERRF to MELAS phenotype in a patient with combined respiratory complex I and IV deficiencies

Edward Byrne¹, Ian Trounce¹, Xenia Dennett², Bernard Gilligan³,
J. Barrie Morley⁴ and Sangkot Marzuki¹

¹*St. Vincent's Hospital*, ²*Royal Children's Hospital*, ³*Alfred Hospital*, ⁴*Monash Medical Centre, Victoria (Australia)*

(Received 26 February, 1988)

(Revised, received 26 August, 1988)

(Accepted 27 August, 1988)

SUMMARY

Identical twins developed myoclonic epilepsy in their teens. One twin remained mildly affected but the other went on to develop sensorineural deafness and ataxia with lactic acidosis and ragged red fibres leading to a diagnosis of mitochondrial encephalopathy. Multiple stroke-like episodes with hemiparesis followed, indicating progression from a MERRF to a MELAS phenotype. Biochemical studies revealed a severe deficiency of mitochondrial NADH-ubiquinone reductase and a moderate deficiency of cytochrome *aa*₃. Western immunoblotting experiments using polyclonal antibodies raised against human placental cytochrome oxidase identified a similar profile of bands to those seen in controls, supporting the view that cytochrome *aa*₃ deficiency in this case may be a secondary consequence of a failure of assembly related to a severe proximal respiratory chain defect.

Key words: Mitochondrial encephalopathy; Respiratory chain defects; MERRF; MELAS; Cytochrome *aa*₃; NADH-ubiquinone reductase; Mitochondrial respiratory complex I

Correspondence to: Dr. E. Byrne, St. Vincent's Hospital, Fitzroy Victoria, 3065, Australia.

INTRODUCTION

Specific defects in the mitochondrial respiratory chain may present with a predominantly myopathic or an encephalopathic picture (see Byrne 1983; Morgan Hughes 1983; DiMauro et al. 1985). A number of patients have been reported with a predominant CNS illness where muscle biopsy revealed structural or functional mitochondrial abnormalities, leading to an inference that mitochondrial failure was also responsible for CNS involvement.

The mitochondrial encephalomyopathies with ragged red fibres in skeletal muscle have a varied presentation. The Kearns Sayre syndrome characterised by tapetoretinal degeneration, heart block and external ophthalmoplegia is a relatively discrete entity which may be due to a defective mitochondrial genome (Byrne et al. 1987). Pavlakis et al. (1984) defined a syndrome with short stature, episodic headache, and multiple stroke-like episodes, the MELAS syndrome, which had been suggested to be a discrete entity (Rowland 1983). Myoclonic epilepsy with ragged red fibres (MERRF) has also been suggested as a discrete entity (Fukuhara et al. 1980; Rosing et al. 1985).

Dispute has existed almost since the discovery of human mitochondrial diseases as to whether discrete syndromes based on clinical features can be reliably identified or whether these disorders represent a continuum among the mitochondrial myopathies. This argument remains unresolved, especially within the rapidly expanding field of the mitochondrial encephalomyopathies.

Recent evidence from three laboratories has implicated deficiency of the mitochondrial respiratory complex I, NADH-ubiquinone reductase, in the MELAS syndrome (Hayes et al. 1985; Kobayashi et al. 1987; Nishizawa et al. 1987). In this paper, we report twin sisters who presented with severe myoclonus, ataxia and nerve deafness. After many years, the more severely affected sister developed stroke-episodes and was found to have a severe NADH-ubiquinone reductase deficiency in muscle mitochondria. An associated partial deficiency of cytochrome *aa₃* was identified, which Western immunoblotting studies suggested to be related to a failure of complex assembly. The evolution of MERRF syndrome into MELAS syndrome and the identification of a deficiency identical to that reported in other recent studies supports the view of mitochondrial encephalomyopathies as a continuum.

CASE HISTORY

Index case

The index case gave a history of onset of myoclonic epilepsy at the age of 19 associated with falls. Developmental milestones had been normal. She had suffered from anorexia nervosa in her teenage years. Myoclonic epilepsy became more severe over the next 2 decades with a combination of generalised myoclonic jerks and multifocal limb myoclonus. She developed increasing unsteadiness of fine hand movements, slurred speech and nerve deafness in her 30 s. A CT scan, at age 44, revealed moderate cerebral atrophy only and the EEG showed a diffuse excess of medium voltage theta activity with occasional bursts of synchronous bilateral spike activity. A diagnosis of dyssynergia cerebellaris myoclonica (Ramsay Hunt syndrome) was made at the age of 46. Myoclonic epilepsy became progressively worse with the development of increasing movement-induced myoclonus leading to several admissions to hospital in her 50th year. Gait ataxia progressed to a point where she required assistance to walk.

On examination, aged 51, she had severe multifocal myoclonus involving the head and all limbs

worsened by voluntary movement. In addition, the speech was slurred and there was a moderately severe symmetrical ataxia with finger–nose and heel–shin testing. Tone was increased in all limbs with generalised deep tendon hyperreflexia but plantar responses were flexor. A nerve deafness was evident. Stature was normal and there was no retinitis pigmentosa or limitation of ocular movement.

Her mother was 80 and had developed dementia late in life. Her twin sister had a similar disorder to the patient. No other relatives were affected and there was no history of consanguinity.

Random resting serum lactate was moderately elevated on several occasions at a time when myoclonus was not severe (3.5 mmol/l, 3.5 mmol/l, 4.0 mmol/l; normal range 0.4–3.2). A CT head scan revealed a low density area in the left caudate nucleus but no other abnormality. Carbamazepine, phenytoin and clonazepam were continued for treatment of myoclonus. She presented 6 months later with acute exacerbation of generalised myoclonus and focal epilepsy in the left arm associated with flaccid paresis of the left arm and mild face and left leg weakness. CT scan was unchanged. Strength improved considerably over 2 weeks and ECG was normal. She represented several months later with right hemiparesis followed by progressive coma. A muscle biopsy was taken from the right vastus lateralis at that time under local anaesthesia to confirm the clinical diagnosis of mitochondrial encephalopathy. The patient failed to improve and developed pneumonia with a fatal outcome. No embolic source was identified at autopsy.

Case II

The identical twin sister of the index case developed myoclonic epilepsy in her teenage years, worse when tired. She fell with occasional myoclonic episodes. This was not of great severity. An EEG revealed bilateral paroxysmal features. On examination at the age of 46, she had no ataxia or deafness. An EEG revealed paroxysmal medium voltage activity in the 3–5 oscillations/sec range associated with low voltage spikes. A CT head scan suggested a small right thalamic infarction which had been asymptomatic. Myoclonic epilepsy was reasonably controlled with clonazepam. When reviewed at the age of 50, she had developed a mild bilateral nerve deafness, mild slurring of speech and a mild limb ataxia but was not disabled and continued to lead an active life.

MATERIALS AND METHODS

Published procedures were employed for histochemical and ultrastructural studies (Byrne et al. 1985a), mitochondrial isolation, polarographic studies, oxidation/reduction difference spectra recording, and respiratory enzyme assay in mitochondrial fractions or muscle homogenate (Byrne and Trounce 1985; Byrne et al. 1985b, 1987). Western immunoblotting was carried out with polyclonal antibodies raised in rabbits against human placental cytochrome oxidase (manuscript in preparation) as described by Jean-Francois et al. (1986).

RESULTS

Muscle biopsy: histological studies

Prominent ragged red fibres were evident with the modified Gomori trichrome stain, and mitochondrial enzyme activity staining (NADH-tetrazolium reductase, succinic dehydrogenase) confirmed the presence of ragged red fibres. Cytochrome oxidase activity was low in most fibres. Electron microscopy confirmed the presence of bizarre intramitochondrial inclusions in many fibres.

Mitochondrial respiratory enzyme activities and cytochrome spectra

State III respiration rates were severely depressed with the site I (NAD-linked) substrates glutamate, pyruvate/malate and ketoglutarate (Fig. 1, Table 1). In contrast,

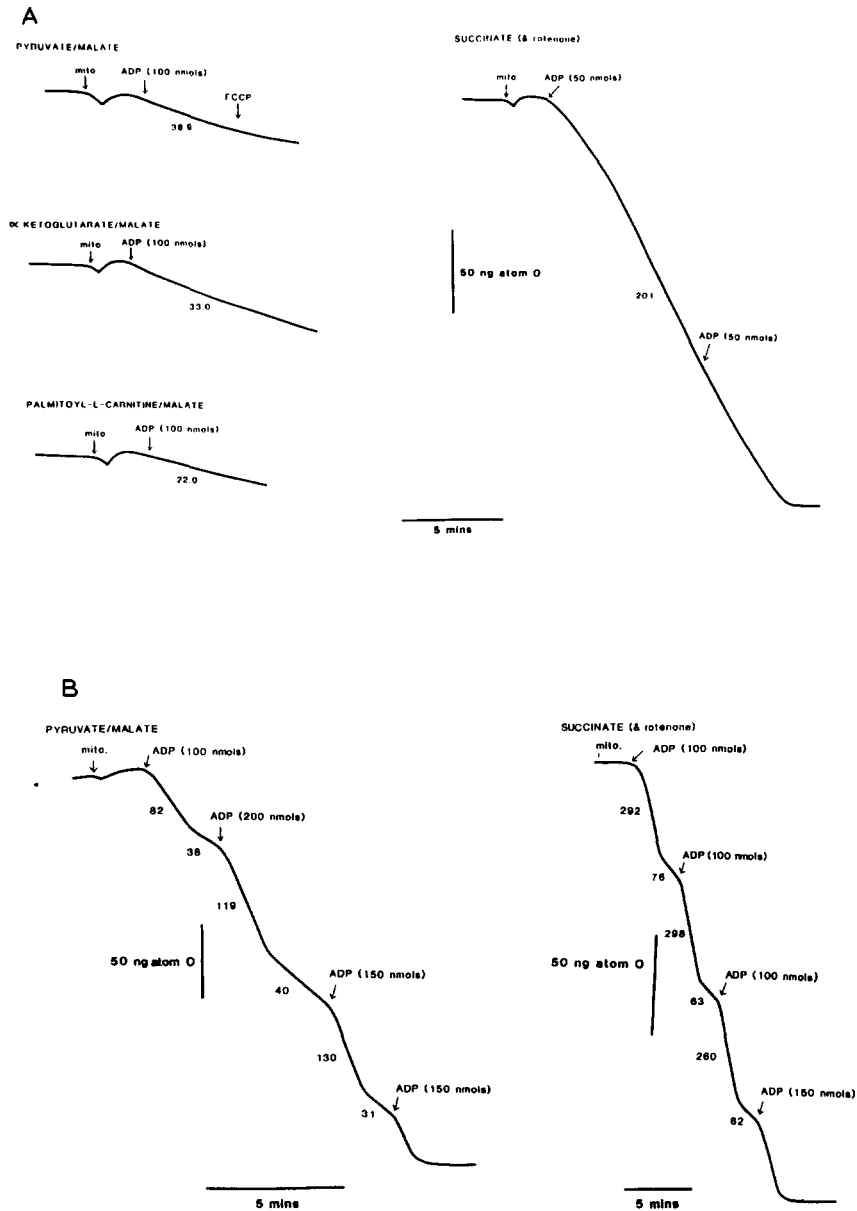


Fig. 1. Polarograph traces showing respiratory activity of (A) isolated patient mitochondria (0.122 mg protein in all experiments) and (B) isolated mitochondria from a control patient with various substrates. Numbers below the traces indicate state 3 respiratory rate (ng-atom O/min per mg mitochondrial protein in the presence of ADP) while additions to the electrode chamber are indicated above the traces. FCCP = carbonyl 4-(trifluoromethoxy)phenylhydrazone ($1.0 \mu\text{M}$). Rates with all site 1 substrates are severely depressed, while succinate-dependent respiration (a site 2 substrate) is relatively preserved.

TABLE 1

STATE 3 RESPIRATION RATES OF ISOLATED SKELETAL MUSCLE MITOCHONDRIA FROM PATIENT AND CONTROLS

Figures represent ng-atom O used/min/per mg mitochondrial protein in the presence of ADP. Figures in parentheses in patient column indicate number of observations with each substrate, while 'n' indicates the number of control biopsies studied with each substrate.

Substrate	Patient	Controls (mean \pm SD)
Pyruvate ^a	26.3 (3)	241 \pm 101 (n = 17)
Glutamate ^a	46.8 (1)	277 \pm 103 (n = 18)
α -Ketoglutarate ^a	33.0 (1)	310 \pm 74 (n = 3)
Palmitoyl-L-carnitine ^a	22.0 (1)	312 (n = 2)
Succinate (+ rotenone)	194 (2)	350 \pm 120 (n = 18)

^a Plus malate.

respiration rates with the site II (FAD-linked) substrate succinate were only slightly below mean control values.

NADH-cytochrome *c* reductase and succinate-cytochrome *c* reductase activities, measured in mitochondrial fractions as described by Moreadith et al. (1984), confirmed a depression of NADH-ubiquinone reductase activity (Table 2).

Cytochrome oxidation/reduction difference spectra revealed normal levels of cytochrome *cc*₁, while cytochrome *b* levels corresponded to the low end of the control range and the level of reducible cytochrome *aa*₃ was markedly depressed (Fig. 2, Table 3).

Western immunoblotting studies

The above results suggest that the primary biochemical defect in the patient's mitochondria is in the respiratory chain NADH-ubiquinone reductase. However, the reduction in the cytochrome *aa*₃ level, albeit with the relatively normal rate of mitochon-

TABLE 2

ACTIVITIES OF NADH-CYTOCHROME *c* REDUCTASE^a AND SUCCINATE CYTOCHROME *c* REDUCTASE IN ISOLATED SKELETAL MUSCLE MITOCHONDRIA FROM PATIENT AND CONTROLS

Figures show activities as nmol cytochrome *c* reduced/min per mg protein. Range of control results is shown in parentheses.

Enzyme	Patient	Controls (n = 5)
NADH-cyt. <i>c</i> reductase	44	151 \pm 67 (75-231)
Succ.-cyt. <i>c</i> reductase	89	98 \pm 28 (62-134)

^a Rotenone-sensitive activity.

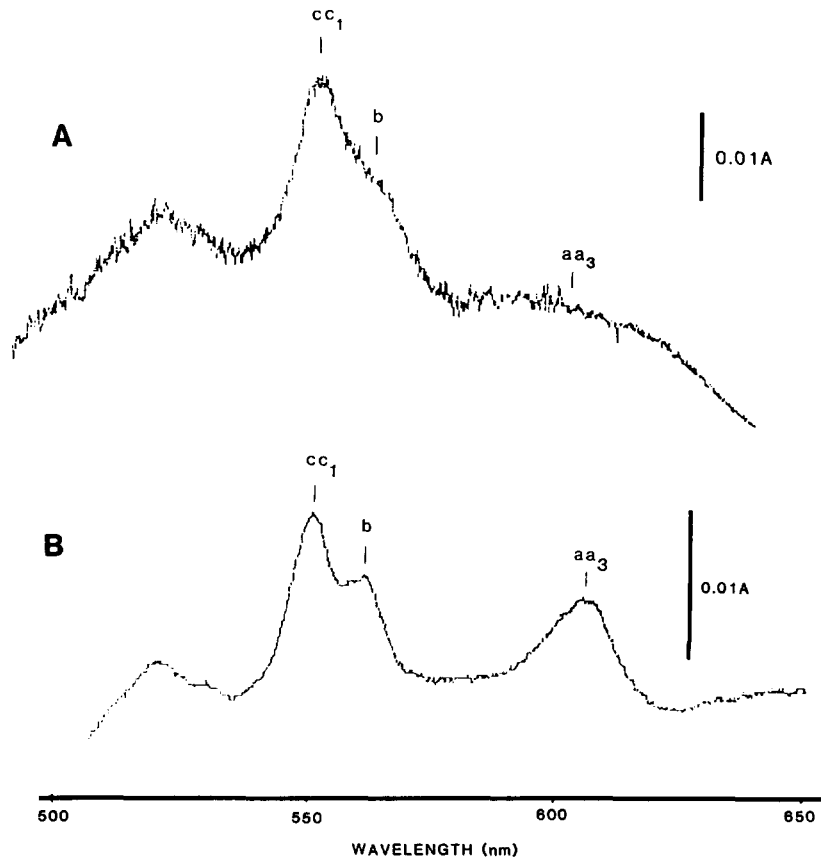


Fig. 2. Reduced minus oxidised spectra of patient (A) and control (B) skeletal muscle mitochondria. The cytochrome aa_3 peak (604 nm) appears greatly diminished in the patient mitochondria.

TABLE 3

CYTOCHROME CONTENT OF ISOLATED SKELETAL MUSCLE MITOCHONDRIA IN PATIENT AND CONTROLS

Figures show pg cytochromes/mg mitochondrial protein. Figures in parentheses show levels of cytochromes aa_3 and b as a percentage of $c + c_1$ levels.

Cytochrome	Patient	Controls (n = 6)
aa_3	227 (23%)	793 ± 110 (66 ± 5.2%)
b	586 (58%)	1069 ± 175 (86 ± 7.8%)
$c + c_1$	1006	1235 ± 200

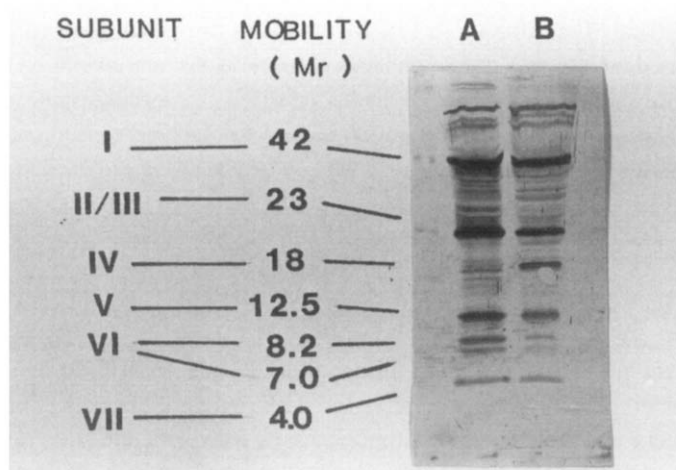


Fig. 3. Western immunoblot of control (A) and patient (B) skeletal muscle mitochondria. Mitochondrial proteins (15 $\mu\text{g}/\text{lane}$) were separated by polyacrylamide gel electrophoresis in the presence of urea and SDS, electrophoretically transferred to nitrocellulose and incubated with anti-sera raised in rabbits against human placenta cytochrome oxidase. Both samples show a similar subunit profile, indicating the normal synthesis of these subunits by the patients' mitochondria. Molecular weights are indicated in kilodaltons.

drial respiration in the presence of complex II substrate, indicates that the cytochrome oxidase complex is also partially affected. The assembly of functional cytochrome oxidase is frequently affected secondary to defects in other mitochondrial respiratory enzyme complexes (Jean-Francois et al. 1986). We have, therefore, examined the presence of the protein subunits of the cytochrome oxidase in the patient's mitochondria by Western immunoblotting with rabbit antibodies raised against human placental holo-cytochrome oxidase. These antibodies showed 7 reacting bands when used against skeletal muscle mitochondria from normal individuals, as illustrated in Fig. 3a. The patient's mitochondria showed a similar reactivity profile (Fig. 3b), indicating normal synthesis of the detected cytochrome oxidase protein subunits, supporting the suggestion that the partial reduction in the cytochrome aa_3 level is due to an assembly problem.

DISCUSSION

Both sisters in this study presented with severe myoclonic epilepsy and went on to develop ataxia and nerve deafness. Resting lactic acidosis and prominent ragged red fibres on muscle biopsy were detected in the index case. These clinical findings suggested a diagnosis of mitochondrial encephalopathy of the myoclonic epilepsy with ragged red fibre (MERRF) type (Fukuhara et al. 1980). The index case went on to develop cerebrovascular events with no obvious carotid or cardiac embolic source. The development of strokes or stroke-like episodes in 3 patients with the MERRF syndrome has been reported previously from Japan (Kuriyama et al. 1984; Kobayashi et al. 1984) and

has been high-lighted by Fukuhara (1985) who first drew attention to the MERRF syndrome. The development of stroke-like episodes in mitochondrial encephalopathy was first noted by Pavlakis et al. (1984) who reported two sibling pairs with a history of stunted growth, episodic vomiting and stroke-like episodes resulting in hemiparesis or cortical blindness (MELAS syndrome). Rowland identified 11 cases in the literature characterised by deafness, recurrent vomiting attack in infancy and stroke-like episodes with mitochondrial abnormalities in skeletal muscle (Rowland 1983). The evolution from a MERRF to a MELAS phenotype in our cases supports the view expressed in the literature that these syndromes are not discrete entities but different points in a continuum.

The development of a similar mitochondrial encephalopathy in two identical twins is of interest. A family has been reported with mitochondrial encephalopathy and myoclonus where a cytoplasmic inheritance pattern was probable (Rosing et al. 1985). Familial cases of MELAS syndrome are also well recognised with affected siblings and a probable affected mother in one family (Shapira et al. 1975) and 4 affected siblings in one other family (Hurko et al. 1986). Two families where one sibling had a MELAS presentation and a second a MERRF presentation have also been reported (Hart et al. 1977; Danks et al. 1987). In another report of a familial series, 2 affected siblings met the criteria for MELAS while 3 other affected siblings could not be classified into the described syndromes (Ishitsu et al. 1987). As in most other familial aggregations of mitochondrial encephalopathy, the development of encephalopathy in a monozygotic twin pair does not allow definite differentiation between autosomal and cytoplasmic inheritance of the defect. It was not possible to examine the demented mother in this study.

Studies with intact skeletal muscle mitochondria in this report, revealed abnormally low respiration rates with 3 NAD-linked substrates but relatively preserved respiration rates with the flavoprotein linked substrate succinate. The detection of a similar reduction in respiration rates with 3 distinct NAD-linked substrates excluded a deficiency in pyruvate dehydrogenase or in a specific substrate translocase. The pattern of depression of state III respiration rate with NAD-linked substrates with reference to the FAD-linked substrate succinate resembled that in other putative cases of NADH-ubiquinone reductase reported (Morgan-Hughes et al. 1979, 1982; Land et al. 1981; Hayes et al. 1985; Nishizawa et al. 1987). We have reported that a small fall in NADH-ubiquinone reductase activity may be seen in some normal subjects either as a normal variant or as an artifact of isolation, but the level of depression of activity in the index case in this study was much greater than in any control subject. There is no doubt, therefore, that a major deficiency in NADH-ubiquinone reductase was present in this patient. In addition, the respiratory activities with succinate as a substrate were marginally depressed and a partial depletion of cytochrome aa_3 was confirmed with difference spectroscopy.

The deficiency in cytochrome aa_3 was not nearly as significant as the NADH-ubiquinone reductase deficiency and the question needs consideration as to whether both defects are primary, possibly as a consequence of a mitochondrial genome abnormality, or whether one deficit is a secondary effect of the primary lesion. A similar

question arises in a second case of combined NADH-ubiquinone reductase and cytochrome oxidase deficiency identified in another laboratory (Sherratt et al. 1984). Studies with yeast mutants have clearly established that a primary abnormality in one respiratory chain complex may lead to defective assembly of a second complex, with defective assembly of cytochrome oxidase (aa_3) being the most frequently observed. This, for example, is well documented in yeast mutants with defective ATP synthase, due to mutations in the mitochondrial structural genes coding for its membrane sector protein subunits (Jean-Francois et al. 1986). It has also been suggested that partial cytochrome oxidase deficiency in adult CPEO patients may be a secondary phenomenon (Byrne et al. 1985). Support for the possibility of a secondary complex IV (cytochrome oxidase) deficiency was obtained in the present study from Western immunoblot studies which revealed a similar subunit profile in the patient's mitochondria to that seen in control mitochondria. However, while these data clearly indicate a defect in assembly rather than in a major subunit deficiency, the reason for the assembly defect cannot be conclusively ascribed as secondary to the defect in the NADH-ubiquinone reductase. A mutation in one of the identified subunits insufficient to alter electrophoretic mobility or a deficiency in a smaller subunit not detected by our probe has not been excluded, and these can equally result in assembly defects.

Three presentations of NADH-ubiquinone reductase deficiency can be identified in the literature. Presentation with myopathy has been reported by several groups, often with severe non-myasthenic fatigability (Morgan Hughes et al. 1979; 1985; Land et al. 1981; Arts et al. 1983; Sherratt et al. 1984 – some cases). CNS manifestations have been either absent or minor in these patients. A number of patients have been reported with a predominant encephalopathic presentation of NADH-ubiquinone reductase deficiency where diagnosis was achieved by demonstrating morphological and functional mitochondrial abnormalities in skeletal muscle (Prick et al. 1981; Morgan Hughes et al. 1982; Hayes et al. 1985; Kobayashi et al. 1987; Nishizawa et al. 1987; Van Erven et al. 1987). Myoclonus was prominent in 3 cases, dementia in 6, ataxia in 3, nerve deafness in 2, and stroke-like episodes in 5. Familial involvement has been seen in only 2 families. The encephalomyopathic variant of NADH-ubiquinone reductase deficiency may therefore present with features of myoclonic epilepsy, MELAS and mitochondrial dementia, indicating that the view gained from a review of clinical facets of mitochondrial encephalopathy that these presentations represent a continuum rather than indicating discrete syndromes with a distinct biochemical basis is correct. The third well characterised presentation of mitochondrial NADH-ubiquinone reductase deficiency is with fulminant rapidly fatal lactic acidosis in infancy (Moreadith et al. 1984; Robinson et al. 1986). The case of Moreadith et al. (1984) is of special interest in that deficiency of an iron-sulfur complex in site I has now been related to deficiency of 2 polypeptide subunits (Moreadith et al. 1987). The phenotypic variation of mitochondrial NADH-ubiquinone reductase deficiency is therefore considerable.

ACKNOWLEDGEMENTS

Dr. John Niall gave permission to study the index case, and his help and encouragement with this study is gratefully acknowledged. Dr. Andrew Danks carried out the muscle biopsy. Thanks are given to St. Vincent's Hospital for permission to present the findings. S.M. is on study leave from the Department of Biochemistry, Monash University, Melbourne, Australia.

REFERENCES

- Arts, W.F.M., H.R. Scholte, J.M. Bogaard, K.F. Kerrebijn, and I.E.M. Luyt-Houwen (1983) NADH-CoQ reductase deficient myopathy: successful treatment with riboflavin. *Lancet*, 2: 581-582.
- Berenberg, R.A., J.M. Pelluck, S. DiMauro, D.L. Schotland, E. Bonilla, A. Eastwood, A. Hayes, C.T. Vicale, M. Behrens, A. Chutorian and L.P. Rowland (1977) Lumping or splitting? "Ophthalmoplegia-plus" or Kearns-Sayre Syndrome? *Ann. Neurol.*, 1: 37-54.
- Byrne, E. (1983) Historical and current concepts in mitochondrial myopathies. *Aust. N.Z.J. Med.*, 13: 299-305.
- Byrne, E. and I. Trounce (1985) Oxygen electrode studies with human skeletal muscle mitochondria in vitro - A reappraisal. *J. Neurol. Sci.*, 69: 319-333.
- Byrne, E., X. Dennett, I. Trounce and R. Henderson (1985a) Partial cytochrome oxidase (aa_3) deficiency in chronic progressive external ophthalmoplegia. *J. Neurol. Sci.*, 71: 257-271.
- Byrne, E., X. Dennett, I. Trounce and J. Burdon (1985b) Mitochondrial myoneuropathy with respiratory failure and myoclonic epilepsy. A case report with biochemical studies. *J. Neurol. Sci.*, 71: 273-281.
- Byrne, E., S. Marzuki, N. Sattayasai, X. Dennett and I. Trounce (1987) Mitochondrial studies in Kearns Sayre syndrome: normal respiratory chain function with absence of a mitochondrial translation product. *Neurology*, 37: 1530-1534.
- Danks, R.A., J.T. Cummins, M. Dorevitch and E. Byrne (1987) Mitochondrial myopathy, encephalopathy, lactic acidosis and stroke-like episodes (MELAS): adolescent onset with severe cerebral oedema. *Aust. N.Z. J. Med.*, 18: 69-72.
- DiMauro, S., E. Bonilla, M. Zeviani, M. Nakagawa and D.C. DeVivo (1985) Mitochondrial myopathies. *Ann. Neurol.*, 17: 521-538.
- Fukuhara, N. (1983) Myoclonus epilepsy and mitochondrial myopathy. In: G. Scarlato and C. Cerri (Eds.), *Mitochondrial Pathology and Muscle Diseases*. Piccin Medical Books, Padua, pp. 90-190.
- Fukuhara, N. (1985) Stroke-like episodes in MERRF. *Ann. Neurol.*, 18: 368.
- Fukuhara, N., S. Tokiguchi, K. Shirakawa and T. Tsubaki (1980) Myoclonus epilepsy associated with ragged red fibres (mitochondrial abnormalities): disease entity or a syndrome? *J. Neurol. Sci.*, 47: 117-133.
- Hart, Z.H., C. Chang, E.V. Perrin, J.S. Neerunjun and R. Ayyar (1977) Familial poliodystrophy, mitochondrial myopathy and lactate acidemia. *Arch. Neurol.*, 34: 180-185.
- Hayes, D.J., D. Hilton-Jones, D.L. Arnold, G. Galloway, P. Styles, J. Duncan and G.K. Radda (1985) A mitochondrial encephalomyopathy. A combined ^{31}P magnetic resonance and biochemical investigation. *J. Neurol. Sci.*, 71: 105-118.
- Hurko, O., E. Feldman, R. Kuncl, S. Caplan, B. Stern and A. Krumholz (1985) Mitochondrial encephalomyopathy, lactic acidosis and stroke (MELAS): multiple instances within a kindred. *Muscle Nerve*, 9 (Supp. 5): 179.
- Ishitsu, T., T. Mikke, A. Kitano, Y. Haraguchi, Y. Ohtani, I. Matsuda, A. Shimoji and H. Kimura (1987) Heterogeneous phenotypes of mitochondrial encephalomyopathy in a single kindred. *Neurology*, 37: 1867-1869.
- Jean-Francois, M.J.B. R.G. Hadikusumo, L.C. Watkins, H.B. Lukins, A.W. Linnane and S. Marzuki (1986) Correlation of defined lesions in the N,N' -dicyclohexylcarbodiimide-binding proteolipid with defects in the function and assembly of yeast mitochondrial H^+ -ATPase and other respiratory enzyme complexes. *Biochem. Biophys. Acta*, 852: 133-143.
- Kobayashi, Y., S. Miyabayashi and G. Takada (1984) Ultrastructural study on the mitochondrial myopathy associated with lactic acidosis. *No To Hattatsu*, 16: 253-261.

- Kobayashi, M., H. Morishita, N. M. Sugiyama, K. Yokochi, M. Nakano, Y. Wada, Y. Hotta, A. Terauchi and I. Nonaka (1987) Two cases of NADH-Coenzyme Q reductase deficiency: relationship to MELAS syndrome. *J. Pediatr.*, 110: 223–227.
- Kuriyama, M., H. Umezaki, Y. Fukuda, M. Osame, K. Koika, J. Tataishi and A. Igata (1984) Mitochondrial encephalomyopathy with lactate pyruvate elevation and brain infarctions. *Neurology*, 34: 72–77.
- Land, J. M., J. A. Morgan-Hughes and J. B. Clarke (1981) Mitochondrial myopathy. Biochemical studies revealing a deficiency of NADH-cytochrome *b* reductase activity. *J. Neurol. Sci.*, 50: 1–13.
- Moreadith, R. W., M. L. Batshaw, T. Ohnishi, D. Kerr, B. Knox, D. Jackson, R. Hruban, J. Olson, B. Reynafarje and A. L. Lehninger (1984) Deficiencies of the iron sulfur clusters of mitochondrial reduced nicotinamide adenine dinucleotide-ubiquinone oxidoreductase (complex I) in an infant with congenital lactic acidosis. *J. Clin. Invest.*, 74: 7685–7697.
- Moreadith, R. W., M. W. Cleeter, C. I. Ragan, M. L. Batshaw and A. L. Lehninger (1987) Congenital deficiency of two polypeptide subunits of the iron protein fragment of mitochondrial complex I. *J. Clin. Invest.*, 79: 463–467.
- Morgan-Hughes, J. A. (1983) Disorders of mitochondrial metabolism – Some clinical and biochemical mechanisms. In: K. B. Saunders (Ed.), *Advanced Medicine, Vol. 19*, Pitman Publ., London, pp. 243–260.
- Morgan-Hughes, J. A., D. N. Landon, J. M. Land and J. B. Clarke (1979) A mitochondrial myopathy with a deficiency of respiratory chain NADH-CoQ reductase activity. *J. Neurol. Sci.*, 43: 27–46.
- Morgan-Hughes, J. A., D. J. Hayes, J. B. Clarke, D. N. Landon, M. Swash, R. J. Stark and P. Rudge (1982) Mitochondrial encephalomyopathies. Biochemical studies in two cases revealing defects in the respiratory chain. *Brain*, 105: 553–582.
- Morgan-Hughes, J. A., D. J. Hayes, M. Cooper and J. B. Clarke (1985) Mitochondrial myopathies: deficiencies localised to complex I and complex III of the mitochondrial respiratory chain. *Biochem. Soc. Trans.*, 13: 684–690.
- Nishizawa, M., K. Tanaka, K. Shinozawa, T. Kuwabara, T. Atsumi, T. Miyatuke and E. Ohama (1987) A mitochondrial encephalomyopathy with cardiomyopathy. A case revealing a defect of complex I in the respiratory chain. *J. Neurol. Sci.*, 78: 189–201.
- Pavlakis, S. G., P. G. Phillips and S. DiMauro (1984) Mitochondrial myopathy, encephalomyopathy lactic acidosis and stroke-like episodes: a distinctive clinical syndrome. *Ann. Neurol.*, 16: 481–488.
- Prick, M. J. J., J. M. Gabreels, W. O. Renier, J. M. F. Trijbels, R. C. A. Sengers and J. L. Slooff (1981) Progressive infantile poliodystrophy. Association with disordered pyruvate oxidation in muscle and liver. *Arch. Neurol.*, 38: 767–772.
- Robinson, B. H., J. Ward, P. Goodyear and A. Beaudet (1986) Respiratory chain defects in the mitochondria of cultured skin fibroblasts from three patients with lactic acidemia. *J. Clin. Invest.*, 77: 1422–1427.
- Rosing, H. J., L. C. Hopkins and D. C. Wallace (1985) Maternally inherited mitochondrial myopathy and myoclonic epilepsy. *Ann. Neurol.*, 17: 228–237.
- Rowland, L. P. (1983) Molecular genetics, pseudogenetics and clinical neurology. *Neurology*, 33: 1179–1195.
- Shapira, Y., S. D. Cederbaum, P. A. Cancilla, D. Nielsen and B. M. Lippe (1975) Familial poliodystrophy, mitochondrial myopathy and lactic acidemia. *Neurology*, 25: 614–621.
- Sherratt, H. S. A., N. E. F. Cartledge, M. A. Johnson and D. M. Turnbull (1984) Mitochondrial myopathy and partial cytochrome oxidase deficiency and impaired oxidation of NADH-linked substrates. *J. Inher. Metab. Dis.*, 7 (Suppl. 2): 107–108.
- Van Erven, P. M. M., F. J. M. Gabreels, W. Ruitenbeek, W. O. Renier and J. C. Fischer (1987) Mitochondrial encephalomyopathy. Association with an NADH dehydrogenase deficiency. *Arch. Neurol.*, 44: 775–778.