

Stroke-like attack: first episode of sporadic hemiplegic migraine

Enrico Ferrante¹ · Valentina Prone² · Marco Longoni² · Elio Clemente Agostoni²

© Springer-Verlag Italia 2017

Abstract Hemiplegic migraine (HM) is a rare migraine with aura; it can be familiar or sporadic. A 46-years-old man presented left migraine followed by right hemiparesis with bilateral plantar flexion of cutaneous plantar reflex (CPR). Brain CT and CT-angiography were normal. The next day patient got worse. The EEG showed left fronto-temporal cuspidate delta waves and brain MRI showed a minimal hyperintensity at T2-sequences in the left frontal cortex with a minor representation of the cortical veins at susceptibility weighted imaging sequences. After 3 days, he had a progressive neurological improvement. After 2 weeks, EEG and brain MRI were normal. He was discharged with diagnosis of probably first attack of sporadic HM and after 8 months he was asymptomatic. The normal CPR on the hemiplegic side might be a clinical marker of functional hemiplegia. For the international classification of headache disorder (ICHD-3) two attacks are necessary for HM diagnosis. We propose for the first attack of HM to make diagnosis of “probable” HM as expected to the same ICHD-3 for migraine. Further studies are necessary to support our hypotheses.

Keywords Headache · Hemiplegic migraine · Stroke-like attack · Cutaneous plantar reflex

Introduction

Hemiplegic migraine (HM) is a rare subtype of migraine with aura that includes motor weakness [1, 2]. The attacks of sporadic HM (SHM) have identical clinical characteristics as the familial type, but patients have negative family history of first- or second-degree relatives. The sporadic and familial forms occur rarely with an equal prevalence of 0.01% [1]. The familial type is caused by mutations in membrane channels (CACNA1A, ATP1A2 or SCN1A) [2]. The average age of onset is 12–17 years (range 1–51 years) [3, 4]. Like other form of migraine, women have a higher prevalence of HM, with female to male ratios ranging from 2.5:1 to 4.3:1 [4, 5]. The aura associated with HM attacks is characterized by motor weakness, but is often associated with sensory, visual or language disturbances. In rare cases, patients may present cerebellar ataxia, encephalopathy or coma [2]. The first attack of SHM needs an accurate clinical evaluation of the other potential causes of acute onset of neurological deficits and headache (mainly ischaemic stroke). It is a diagnosis of exclusion [1].

Case report

On 7 June 2016 at 8.00 p.m., a 46-years-old man, diabetic, with episodic tension type headache since one year, suddenly presented a confusional state, unknowing the road to home. After few minutes the patient had dysphasia, paresthesia from right hand dating back to the elbow and moderate left button migraine with nausea and vomiting. At midnight in emergency room he presented right hemiparesis. Neurological exam showed dysphasia, slight right hemiparesis, lower right facial nerve paresis and bilateral plantar flexion of cutaneous plantar reflex (CPR). Brain CT and CT-angiography were

✉ Enrico Ferrante
enricoferrante@libero.it

¹ Headache Centre, Neurosciences Department, Niguarda Ca' Granda Hospital, Milan, Italy

² Neurosciences Department, Niguarda Ca' Granda Hospital, Milan, Italy

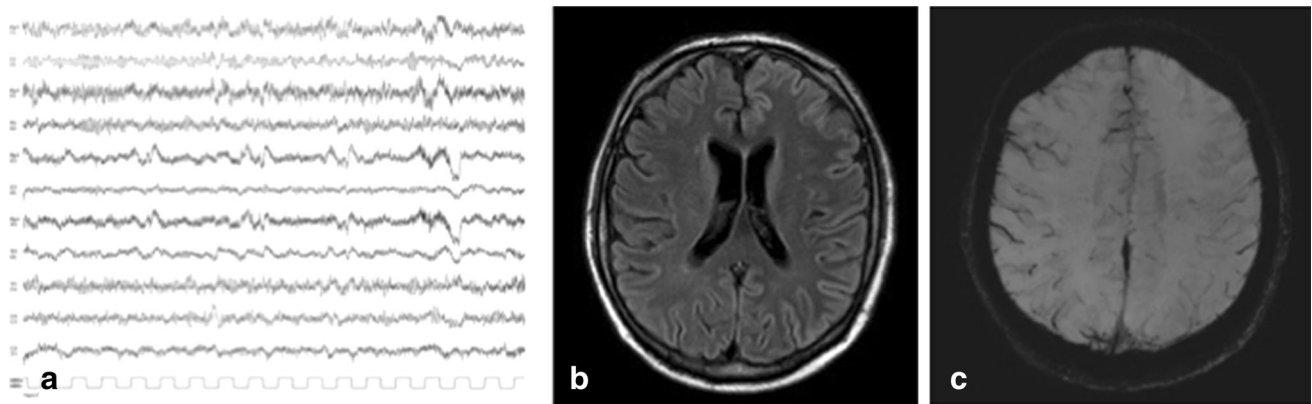


Fig. 1 During the attack, EEG showed left fronto-temporal cuspidate delta waves with slow pseudo-periodic trend (a). After 2 days Gadolinium MRI showed a minimal diffuse signal alteration at T2

normal. On 8 June at 11.00 a.m. neurological examination showed stupor, aphasia, right flaccid hemiplegia and bilateral plantar flexion of CPR. The EEG showed left fronto-temporal cuspidate delta waves with slow pseudo-periodic trend (Fig. 1a); the control brain CT was normal. For a slight fever a lumbar puncture was performed with a protein increased (103.1 mg/dl). On 9 June the gadolinium brain MRI showed a minimal diffuse hyperintensity at T2 sequences in the left frontal cortex (Fig. 1b) and a minor representation of the cortical veins in the same zone at susceptibility weighted imaging (SWI) sequences (Fig. 1c), with negative DWI for acute ischaemic lesions. After 3 days he had a progressive neurological improvement with complete recovery in 5 days. After 2 weeks EEG and brain MRI were normal. The patient was discharged with diagnosis of probably first attack of SHM. Genetic test for familial HM was negative. After 8 months the patient was asymptomatic.

Discussion

Patients with SHM can arrive at the emergency room mimicking an acute ischaemic stroke [2]. The absence of acute ischaemic lesions at brain CT and DWI-MRI and normal CPR on the hemiparetic side exclude the ischaemic etiology and the consequent procedure of intravenous thrombolysis. In our cases the encephalitic etiology was excluded too for the normalization of the EEG. The CSF protein increase was probably due to the alteration of the encephalic blood barrier secondary to the cortical spreading depression (CSD) associated with the migraine attack. The CSD cause a reversible cerebral cortical dysfunction characterized by a neuronal excitation followed by a prolonged inhibition of neurological activity. Increased excitatory glutamate release caused a higher oxygen extraction fraction and veins alterations on SWI sequences [1]. Brain MRI SWI sequences provide information about any tissue with

sequences in the left frontal cortex (b) and a minor representation of the cortical veins in the same zone at susceptibility weighted imaging (SWI) sequences (c)

magnetic susceptibility that differs from neighboring structures [6]. Iron and calcium-rich tissues increase magnetic susceptibility. SWI generates a source of contrast from the relative differences in tissue-iron content and generally shows asymmetrical prominence of the cerebral veins during SHM aura [1]. In our case, MRI was made 2 days after the attack and SWI sequences show a minor representation of the cortical veins likely caused by CSD. The CPR is in plantar flexion on the hemiplegic side probably for the reversible neuronal dysfunction during CSD. The diagnosis of first attack of SHM remains a diagnosis of exclusion.

Conclusion

Brain MRI SWI sequences might have diagnostic value for the hemiplegic aura. For the International Classification of Headache Disorder (ICHD-3) two attacks are necessary for HM diagnosis. We propose for the first attack of HM to make diagnosis of “probable” HM as expected to the same ICHD-3 for migraine. Furthermore, considering that in emergency room neuroradiological exams are generally normal, the possibility to have a clinical marker like normal CPR on the hemiplegic side can be helpful in differential diagnosis between ischaemic stroke and stroke mimics (e.g. SHM) and to avoid intravenous thrombolysis with consequent bleeding risk. Further studies are necessary to support our hypothesis.

Compliance with ethical standards

Conflict of interest I certify that there is no actual or potential conflict of interest in relation to this article.

Ethical standards The studies have been performed in accordance with the ethical standards as laid down in the 1964 Declaration of Helsinki and latest revisions (the latest in 2013). Patient informed consent to be included in the study has been obtained”

References

1. Fedak EM, Zumberge NA, Heyer GL (2013) The diagnostic role for susceptibility-weighted MRI during sporadic hemiplegic migraine. *Cephalalgia* 33(15):1258–1263
2. Bosemani T, Burton VJ, Felling RJ, Leigh R, Oakley C, Poretti A, Huisman TAGM (2014) Pediatric hemiplegic migraine: role of multiple MRI techniques in evaluation of reversible hypoperfusion. *Cephalalgia* 34(4):311–315
3. Ducros A, Denier C, Joutel A et al (2001) The clinical spectrum of familial hemiplegic migraine associated with mutation in a neuronal calcium channel. *N Engl J Med* 345:17
4. Thomsen LL, Eriksen MK, Roemer SF et al (2002) A population-based study of familial hemiplegic migraine suggests revised diagnostic criteria. *Brain* 125:1379
5. Thomsen LL, Ostergaard E, Olesen J, Russell MB (2003) Evidence for a separate type of migraine with aura: sporadic hemiplegic migraine. *Neurology* 60:595
6. Haacke EM, Mittal S, Wu Z et al (2009) Susceptibility-weighted imaging: technical aspects and clinical applications, part 1. *Am J Neuroradiol* 30:19–30