

Correspondence

A Case of Recovery After Delayed Intracranial Hemorrhage After Deep Brain Stimulation for Treatment-Resistant Depression

To the Editor:

Deep brain stimulation (DBS) is an invasive neuromodulation treatment that has been employed for treatment-resistant depression (TRD) during the last decade (1–3). The safety and tolerability of DBS have been established in neurological disorders and might not present greater risks in psychiatric conditions (1). The most feared complication of this surgery is an intracerebral hemorrhage (ICH) due to the electrode placement, with the average risk varying between 0.2% and 5.6% in the literature (4). Here, we report a case of a delayed ICH after DBS for TRD and discuss possible causes and outcome comparing with previous literatures.

The patient was a 54-year-old French Caucasian man with a 9-year history of major depressive disorder. He presented with high severity associated with impaired global functioning (Hamilton Depression Rating Scale (17 items) score: 22; Global Assessment Functioning: 30/100) and severe TRD [stage V of the classification of Thase and Rush (5)]. Indeed, he received numerous and adequate traditional methods, including a combination of pharmacological treatments, psychotherapy, 40 repetitive transcranial magnetic stimulation sessions, and a course of 12 electroconvulsive therapies, without improvement.

Our multidisciplinary team hypothesized that this patient could benefit from DBS. He provided his written informed consent to participate in a multicenter randomized controlled trial to assess the therapeutic value of nucleus accumbens (N Acc)-DBS (registered NCT01973478).

Perioperatively, medical assessment showed moderate obesity (body mass index = 33), stabilized hypertension, and hyperlipidemia, treated with amlodipine (5 mg/day), valsartan (160 mg/day), and rosuvastatin (5 mg/day), respectively, for 4 years. Pharmacotherapy was used as maintenance treatment (duloxetine [180 mg/day] and quetiapine [300 mg/day]) and was kept constant during follow-up.

At day 0, a Leksell stereotactic frame (Elekta Instrument, Stockholm, Sweden) was applied under local anesthesia. Nonstereotactic anatomical magnetic resonance images were coregistered on the stereotactic images. According to the Yelnik and Bardinat atlas (6), the stereotactic coordinates of the target were defined using SurgiPlan software (Elekta Instrument) as 5 mm below, 4.5 mm anterior, and 9 mm lateral to the anterior commissure. Two quadripolar DBS electrodes (Medtronic model 3389; Medtronic, Minneapolis, MN) were implanted bilaterally. According to the local vascularization, the cerebral enter point was chosen at the gyrus crown with no sulcal or ventricular incursion. The electrode trajectory was calculated to pass through the anterior part of the middle frontal gyrus (Brodmann area 9/46) and the anterior limb of the internal capsule before ending in the ventral striatum, N Acc (Figure 1A, B). An immediately postoperative cranial computed

tomography scan (Figure 1B) was coregistered and fused with the preoperative magnetic resonance imaging. This immediate postoperative imaging confirmed the correctness of the final implantation of the two electrodes in terms of location and the total absence of hemorrhage. A pacemaker (Activa PC, model 37601, Medtronic) was implanted at day 2, while the medical device could be activated after randomization at day 30. Vital signs for surgery were normal. Moreover, no complication occurred during 7 days after surgery. At day 8, the patient presented with an acute confusional syndrome with aphasia and psychomotor retardation without tonic-clonic seizures. Computed tomography showed a voluminous left frontal hematoma along the electrode (diameter 55 mm) with perihematomal edema, a deletion of cortical sulci, and a mild deflection of the midline (Figure 1C). His ICH was managed conservatively, without surgical evacuation, and it resolved spontaneously. After 1 month, computed tomography showed a resorption of the hematoma with the presence of a sequellar hypodense range (Figure 1D). No mass effect or sign of commitment remained, and the DBS leads did not shift away from the original target. The ICH caused slurred speech and a frontal syndrome with predominant apathy, which entirely recovered after a 3-month rehabilitation course. Because of persistent depression, programming of the internal pulse generator was started. During 1 year, we used bipolar contact, and the amplitude was gradually increased to 4.9 V (130 Hz, 60 μ s) without side effects but no improvement. We changed to a monopolar stimulation with the same frequency and pulse width by gradually adjusting the amplitude. At 4 V, the patient improved immediately; after a few seconds, he reported “a puff of well-being.” The antidepressant effect remains for more than a year afterward (Hamilton Depression Rating Scale (17 items) score: 9; Global Assessment Functioning: 65/100).

We first reported the case of ICH 8 days after N Acc-DBS for TRD. The effectiveness of DBS and the choice of the stimulation site remain debated in the treatment of depression (1). This case confirms the antidepressant efficacy of N Acc-DBS suggested in previous studies (3,7). We also found the acute effect of DBS as described by Schlaepfer *et al.* when optimal parameters were determined (3). Thereby, N Acc-monopolar stimulation seems in this case to be more effective than bipolar stimulation.

In general, ICH due to DBS surgery is described during surgery or during the early postoperative phase, that is, diagnosed during the first 24 hours after surgery (4). The pathogenesis of delayed ICH remains unclear. Various intervals of ICH after lead implant are 36 hours to 3 months (8). The use of microelectrode recording, the number of microelectrode recording penetrations, and the sulcal or ventricular incursion confer significantly greater surgery-related risk (4,9). Moreover, some patient-related risk factors have been identified as older age, taking antiplatelet or anticoagulation agents, and history of hypertension (4). Our patient had presented with one hypertensive crisis 5 years ago and was stabilized with the same treatment without any other risk factor.

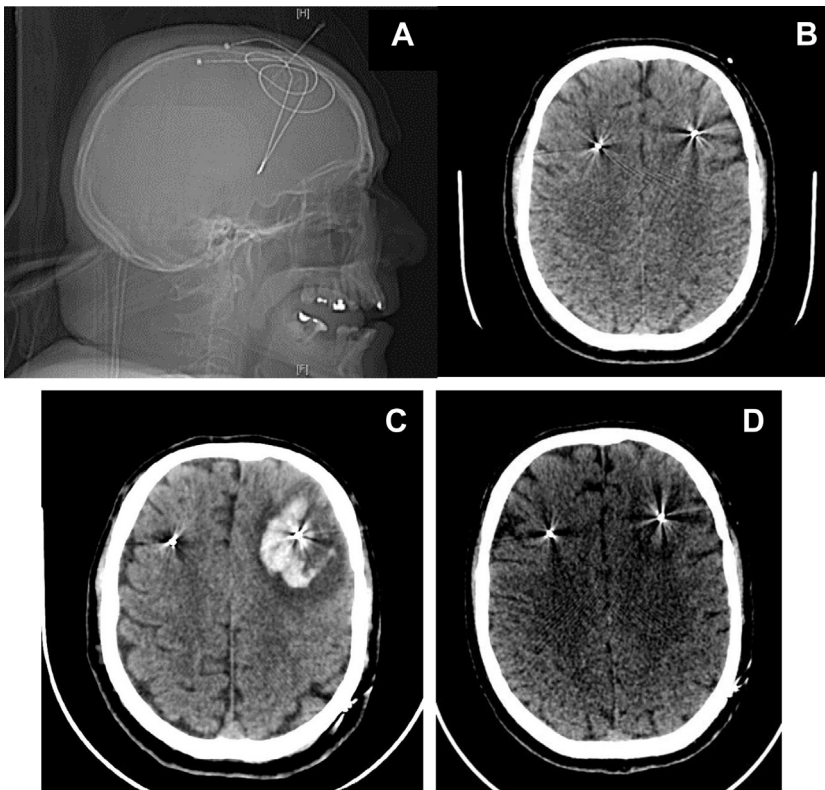


Figure 1. (A, B) The electrode trajectory was calculated to pass through the anterior part of the middle frontal gyrus (Brodmann area 9/46) and the anterior limb of the internal capsule before ending in the ventral striatum, nucleus accumbens. (C) Computed tomography showed a voluminous left frontal hematoma along the electrode (diameter 55 mm) with perihematomal edema, a deletion of cortical sulci, and a mild deflection of the midline. (D) After 1 month, computed tomography showed a resorption of the hematoma with the presence of a sequellar hypodense range.

Finally, ICH related to DBS frequently causes mass effect and significant displacement of the brain and the leads and may need surgical evacuation (4). However, as described in previous reports, when the leads return to near their initial position, stimulation success may still be achieved (8,10).

Such a rare hemorrhagic event, although not clearly explained, exists. Awareness is important for proper clinical management of patients after DBS.

In summary, this case report confirms that with allowed time, after the hematoma has resolved, an antidepressant effect from bilateral DBS therapy can occur on follow-up.

Raphaëlle Richieri
Pierre-Yves Borius
Michel Cermolacce
Bruno Millet
Christophe Lançon
Jean Régis

Acknowledgments and Disclosures

This trial was supported by a grant from the French Ministry of Health (Grant No. PHRC 2013).

The authors report no biomedical financial interests or potential conflicts of interest.

Article Information

From the Department of Psychiatry, Addictology and Child Psychiatry (RR, MC, CL), La Conception University Hospital, and Department of Neurosurgery (JR), La Timone Hospital, Public Assistance Marseille

Hospitals, Health, Chronic Diseases and Quality of Life (RR, CL), EA 3279 Research Unit, and Institut de Neurosciences des Systèmes (JR), Institut National de la Santé et de la Recherche Médicale UMR 1106, Aix Marseille University, Marseille; Department of Neurosurgery (P-YB) and Department of Psychiatry (BM), Pitié-Salpêtrière University Hospital, Public Assistance Paris Hospitals, Paris, France.

Address correspondence to Raphaëlle Richieri, M.D., Ph.D., Hôpital Sainte Marguerite, Pôle Psychiatrie Addictologie et Pédopsychiatrie, 270, Boulevard Sainte Marguerite, 13009 Marseille, France; E-mail: raphaellemarie.richieri@ap-hm.fr.

Received Apr 19, 2017; accepted Apr 19, 2017.

References

1. Fitzgerald PB, Segrave RA (2015): Deep brain stimulation in mental health: Review of evidence for clinical efficacy. *Aust N Z J Psychiatry* 49:979–993.
2. Lozano AM, Mayberg HS, Giacobbe P, Hamani C, Craddock RC, Kennedy SH (2008): Subcallosal cingulate gyrus deep brain stimulation for treatment-resistant depression. *Biol Psychiatry* 64:461–467.
3. Schlaepfer TE, Cohen MX, Frick C, Kosel M (2008): Deep brain stimulation to reward circuitry alleviates anhedonia in refractory major depression. *Neuropsychopharmacology* 33:368–377.
4. Zrinzo L, Foltynie T, Limousin P, Hariz MI (2012): Reducing hemorrhagic complications in functional neurosurgery: A large case series and systematic literature review. *J Neurosurg* 116:84–94.
5. Thase ME, Rush AJ (1997): When at first you don't succeed: Sequential strategies for antidepressant nonresponders. *J Clin Psychiatry* 58(suppl 13):23–29.
6. Yelnik J, Bardinet E, Dormont D, Malandain G, Ourselin S, Tandé D, et al. (2007): A three-dimensional, histological and deformable atlas of the human basal ganglia: I. Atlas construction based on immunohistochemical and MRI data. *NeuroImage* 34:618–638.

Correspondence

7. Bewernick BH, Hurlemann R, Matusch A, Kayser S, Grubert C, Hadrysiewicz B, *et al.* (2010): Nucleus accumbens deep brain stimulation decreases ratings of depression and anxiety in treatment-resistant depression. *Biol Psychiatry* 67:110–116.
8. Oyama G, Okun MS, Zesiewicz TA, Tamse T, Romrell J, Zeilman P, *et al.* (2011): Delayed clinical improvement after deep brain stimulation-related subdural hematoma: Report of 4 cases. *J Neurosurg* 115:289–294.
9. Gorgulho A, De Salles AA, Frighetto L, Behnke E (2005): Incidence of hemorrhage associated with electrophysiological studies performed using macroelectrodes and microelectrodes in functional neurosurgery. *J Neurosurg* 102:888–896.
10. Henderson EY, Goble T, D'Haese PF, Pallavaram S, Oluigbo C, Agrawal P, *et al.* (2015): Successful subthalamic nucleus deep brain stimulation therapy after significant lead displacement from a subdural hematoma. *J Clin Neurosci* 22:387–390.