

# Transcortical Sensory Aphasia after Left Frontal Lobe Infarction: Loss of Functional Connectivity

Miseon Kwon<sup>a</sup> Woo Hyun Shim<sup>b</sup> Sang-Joon Kim<sup>b</sup> Jong S. Kim<sup>a</sup>

Departments of <sup>a</sup>Neurology and <sup>b</sup>Radiology, Asan Medical Center, University of Ulsan College of Medicine, Seoul, South Korea

## Keywords

Functional MRI · Frontal lobe · Transcortical aphasia

## Abstract

**Background:** The underlying mechanism of transcortical sensory aphasia (TSA) caused by lesions occurring in the left frontal lobe remains unclear. We attempted to investigate the mechanism with the use of functional MRI (fMRI). **Methods:** We studied 2 patients with TSA after a left frontal infarction identified by diffusion-weighted MRI. As control subjects, a patient with transcortical motor aphasia and a healthy normal adult were chosen. The Korean version of Western Aphasia Battery was performed initially and at 3 months post stroke. We performed fMRI using verb generation and sentence completion tasks. Resting-state fMRI (rs-fMRI) was also obtained for network-level analysis initially and at 3 months post stroke. **Results:** The results of diffusion- and perfusion-weighted MRI revealed no diffusion-perfusion mismatch. Initial fMRI in patients with TSA showed no reversed inter-/intra-hemispheric activation patterns. rs-fMRI showed significantly decreased resting-state functional connectivity in the language network in patients with TSA compared with the control subjects. Follow-up rs-fMRI studies showed improvement in functional connectivity along with the recovery of patients' language function. **Conclusion:** Our data showed that the auditory comprehension deficits in patients with frontal lobe infarcts is attributed to

difficulty accessing the posterior language area due to functional disconnection between language centers in the acute stage of stroke.

© 2017 S. Karger AG, Basel

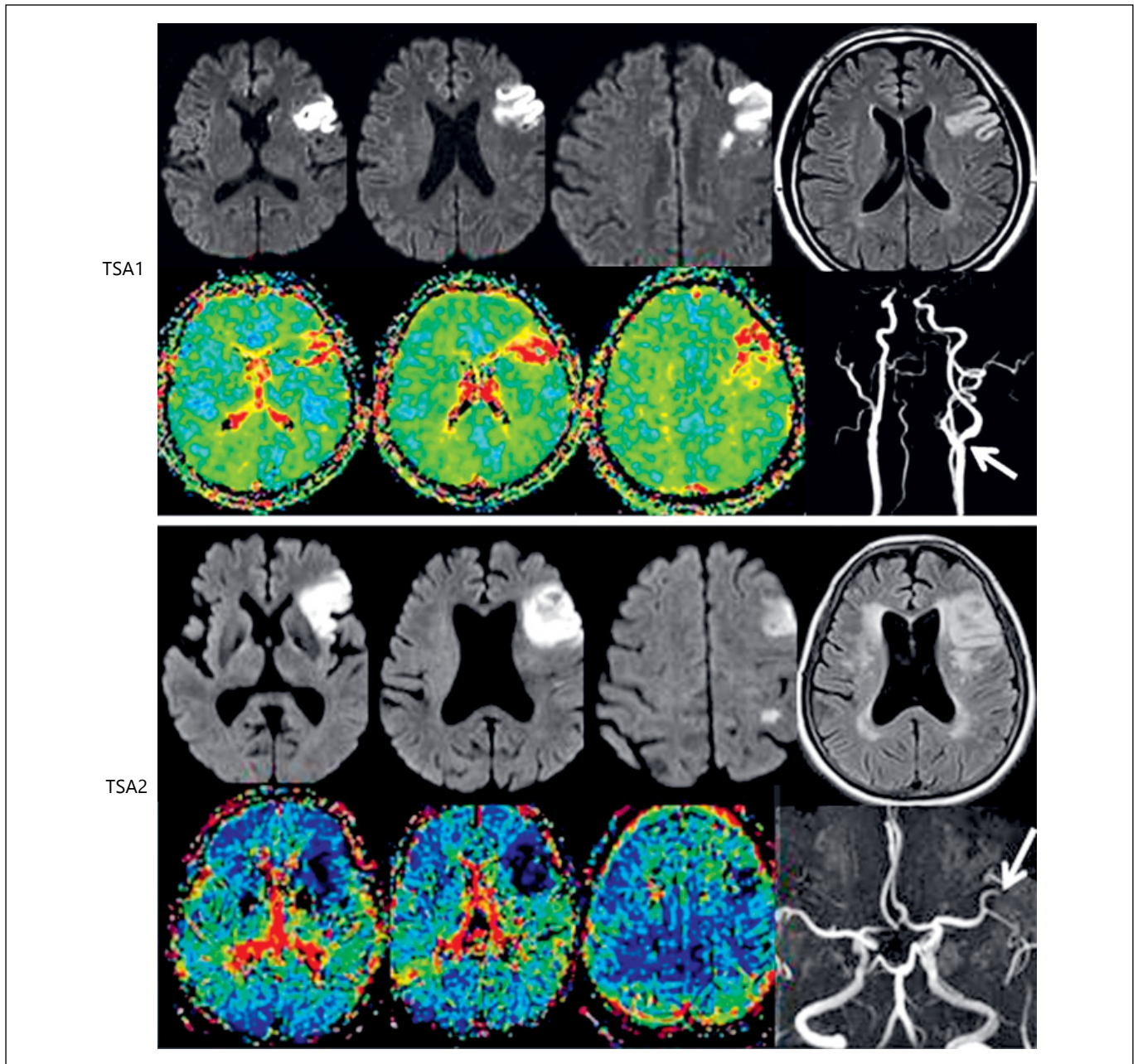
## Introduction

Transcortical sensory aphasia (TSA), characterized by impairment of auditory comprehension with preserved speech fluency and repetition, is usually attributed to temporal or parietal lesions [1]. Rarely, patients with left frontal lobe lesions presenting with TSA have been reported [2–6], but the underlying mechanisms remain unclear. We studied 2 patients with TSA due to left frontal lobe lesions using multimodal MRIs to clarify the mechanism. The results were compared with those of a patient with transcortical motor aphasia (TMA) caused by left frontal infarction and of a healthy, normal subject.

## Materials and Methods

### Patients

We studied 2 patients (TSA1 and TSA2) who presented with TSA due to acute ischemic stroke and were admitted to the Asan Medical Center, Seoul, South Korea. TSA1 was a right-handed, 65-year-old man with 12 years of education. He was a current cigarette smoker and had hyperlipidemia. On the day of stroke



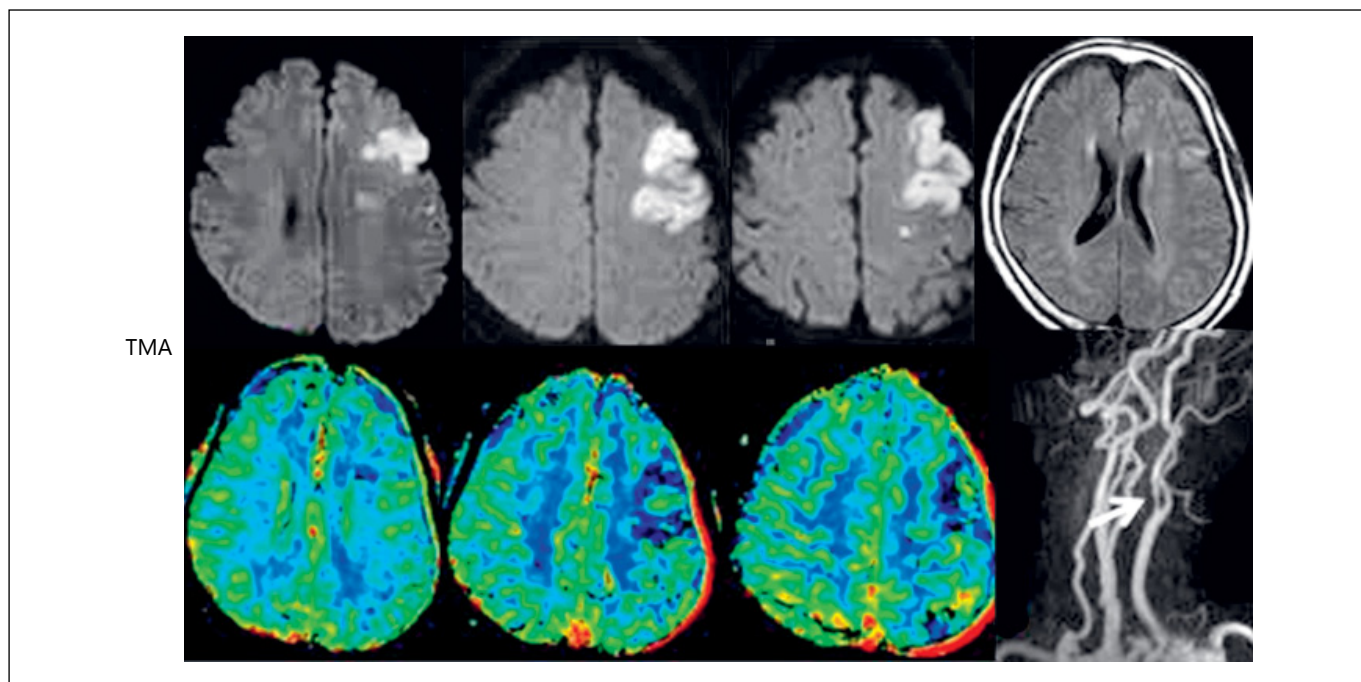
**Fig. 1.** Diffusion (first 3 figures in upper rows) and perfusion (first 3 figures in lower rows) MRIs showing an acute infarction in the left frontal areas without diffusion-perfusion mismatches. TSA2 had a small additional infarct in the left parietal area. Fluid attenuated inversion recovery images (last images in upper rows) showed moderate periventricular and white matter ischemic changes in

TSA2 patient. MR angiography showed left carotid artery stenosis (arrows) in TSA1 and TMA, and occlusion of superior branch of the middle cerebral artery in TSA2 patients. TSA1, patient 1 with transcortical sensory aphasia; TSA2, patient 2 with transcortical sensory aphasia; TMA, patient with transcortical motor aphasia.

(Figure 1 continued on next page.)

onset, his wife found that he produced inappropriate speech such as “I cannot turn on the TV” while he was watching TV, and kept saying things out of context. On neurological examination, he did not have any neurologic deficits other than prominent aphasia. Diffusion-weighted imaging (DWI) MRI per-

formed on the day of symptom onset showed a left frontal infarct (Fig. 1, TSA1). MR angiography (MRA) and carotid duplex scan showed moderate (55%) stenosis of the left carotid artery, and artery-to-artery embolism was considered a presumed stroke mechanism.



**Table 1.** Results of language assessment in patients with aphasia and controls

K-WAB	Subjects (sex/age) initial/follow-up test			
	TSA1 (M/65)	TSA2 (F/75)	TMA (F/74)	HN (M/67)
Spontaneous speech (20)	15/18	9/15	10/-	19/-
Fluency (10)	8/9	7/8	5/-	10/-
Information contents (10)	7/9	2/7	5/-	9/-
Auditory comprehension (10)	6.85/9.80	2.90/5.55	8.60/-	9.2/-
Yes/no question (60)	39/60	42/51	51/-	60/-
Word recognition (60)	50/59	7/41	57/-	60/-
Sequential commands (80)	48/77	9/19	64/-	64/-
Repetition (10)	9.0/9.9	8.3/7.7	8.1	10/-
Naming (10)	6.2/9.3	0.9/5.4	7.9	9.6/-
Object naming (60)	47/60	7/42	56/-	60/-
Word fluency (20)	3/13	0/0	3/-	16/-
Sentence completion (10)	6/10	2/8	10/-	10/-
Responsive naming (10)	6/10	0/4	10/-	10/-
AQ total (100)	74.1/94.0	42.2/67.3	69.2/-	95.6/-

K-WAB, Korean version of Western Aphasia Battery; AQ, aphasia quotient; TSA1, patient 1 with transcortical sensory aphasia; TSA2, patient 2 with transcortical sensory aphasia; TMA, patient with transcortical motor aphasia; HN, healthy normal adult; NA, not applicable.

TSA2 was a 75-year-old woman with 12 years of education, and had had hypertension, diabetes mellitus, and atrial fibrillation. She was reported to have irrelevant speech during a conversation with her son. On admission, she did not have any neurologic deficits except the prominent aphasia. DWI performed on the day of symptom onset showed a left frontal infarct (Fig. 1, TSA2). A small

parietal infarct was also observed. MRA showed occlusion of superior branch of the middle cerebral artery, and there was no significant stenosis in the carotid artery. Cardiogenic embolism was considered a presumed mechanism of stroke.

As controls, a patient with TMA and a healthy normal (HN) adult were recruited (Table 1). TMA was a 74-year-old, hyper-

tensive woman who developed speech disturbances and right hemiparesis. On neurological examination, he had prominent aphasia and right hemiparesis. DWI performed on the day of symptom onset showed a left frontal infarct (Fig. 1, TMA). MRA showed severe stenosis of the left carotid artery, and artery-to-artery embolism was considered a presumed cause of stroke.

In all these 3 patients, there was no mismatch between DWI and perfusion-weighted MRI. Fluid attenuated inversion recovery images showed no significant white matter ischemic lesions except for TSA2 who showed moderate periventricular and white matter ischemic changes (Fig. 1). HN was a 67-year-old man without any neurological disturbances who was recruited from subjects who visited Asan Medical Center Health Promotion Center for the purpose of a routine health check-up.

This study was approved by the Institutional Review Board of Asan Medical Center, and all the patients and control subjects provided written informed consent.

### Language Tests

Korean version of the Western Aphasia Battery (K-WAB) was performed 2–5 days after the stroke onset, and also at 3 months post stroke.

### Functional MRI Studies

We performed functional MRI (fMRI) using verb generation and sentence completion tasks to assess the activation pattern during language processing for HN and the patients with aphasia within 1–4 days after the initial K-WAB test. Resting-state fMRI (rs-fMRI) was also obtained for network-level analysis. For TSA patients, rs-fMRI was repeated on the day of follow-up aphasia testing at 3 months post stroke.

MRI data were acquired on a 3T system (Achieva; Philips Medical Systems, The Netherlands). A high-resolution 3D-T1 image was obtained with the following parameters: TR/TE, 9.9/4.6 ms; flip angle, 8°; field of view, 224 mm; matrix, 448 × 448; and slice thickness, 1 mm with no gap. The stimulus-induced fMRI and rs-fMRI were measured by blood oxygen level-dependent contrast image with following parameters: TR/TE, 3,000/35 ms; flip angle, 90°; field of view, 224 mm; matrix, 112 × 112; slice thickness, 3 mm with no gap; number of dynamics, 100 (task-based), 150 (resting-state). Parameters used for DWI were the following: TR/TE, 9,600/70 ms; flip angle, 90°; field of view, 224 mm, matrix 224 × 224; 32 diffusion directions with  $b = 1,000$  and one with  $b = 0$ ; slice thickness, 2 mm with no gap.

For fMRI tests, words were presented visually (using E-Prime software) by back-projection to a screen mounted inside the bore and shown through a mirror mounted on the head coil. A stimulation paradigm consisting of 5 periods of 30 s “stimulation on” separated by 30 s “stimulation off” was repeated twice for sentence reading comprehension and for the verb generation task. The fMRI data were processed using FSL 5.0.6 (fMRI Expert Analysis Tool, [www.fmrib.ox.ac.uk/fsl](http://www.fmrib.ox.ac.uk/fsl)) and registered to a standard space (MNI-152 space). For the rs-fMRI data, several pre-processing steps were taken to remove the time course’s noise in each voxel: (1) motion correction, (2) de-spiking, (3) removal of linear trends (up to 2nd order), and (4) bandpass frequency filtering (0.01–0.1 Hz). We also applied spatial smoothing with a 5 mm FWHM Gaussian kernel before connectivity measurements in a standard space (MNI-152 space).

For each subject, the seed-driven rs-fMRI analysis was performed using AFNI (<http://afni.nimh.nih.gov/afni/>). We defined the seed-ROI based on the activation region when applying stimulus-induced fMRI, which was Broca’s (BA 44) area in the left hemisphere. The average time series of seed-ROI were computed and used to produce Pearson’s correlation coefficients maps.

### Diffusion Tensor Imaging Tractography

The Diffusion Toolkit (<http://www.trackvis.org/>) was used for constructing fractional anisotropy and deterministic diffusion tensor imaging (DTI) tractography by a continuous tracking algorithm (50° angular threshold) after applying a DWI mask. Trackvis (<http://www.trackvis.org/>) was used for isolation of the arcuate fasciculus (AF) and fiber-track analysis. The ROIs for the AF track were drawn manually over the color fractional anisotropy maps.

## Results

### Language Tests and MRI Findings

The K-WAB tests demonstrated mild-to-moderate (TSA1; aphasia quotient [AQ], 74.1/100) and moderate-to-severe (TSA2; AQ, 42.2/100) aphasia (Table 1). Their spontaneous speech was fluent and grammatically correct with no dysarthria or apraxia of speech. TSA2 often showed perseveration/paraphasic errors, which made the speech content irrelevant. Their repetition ability was generally preserved. Auditory comprehension ability of TSA1 was impaired not only for grammatically complex sentences but also for simple words. TSA2 showed severe deficits even at the word level. The TMA patient showed mild-to-moderate (AQ 69.2/100) aphasia, and the AQ score of HN was within normal range (95.6).

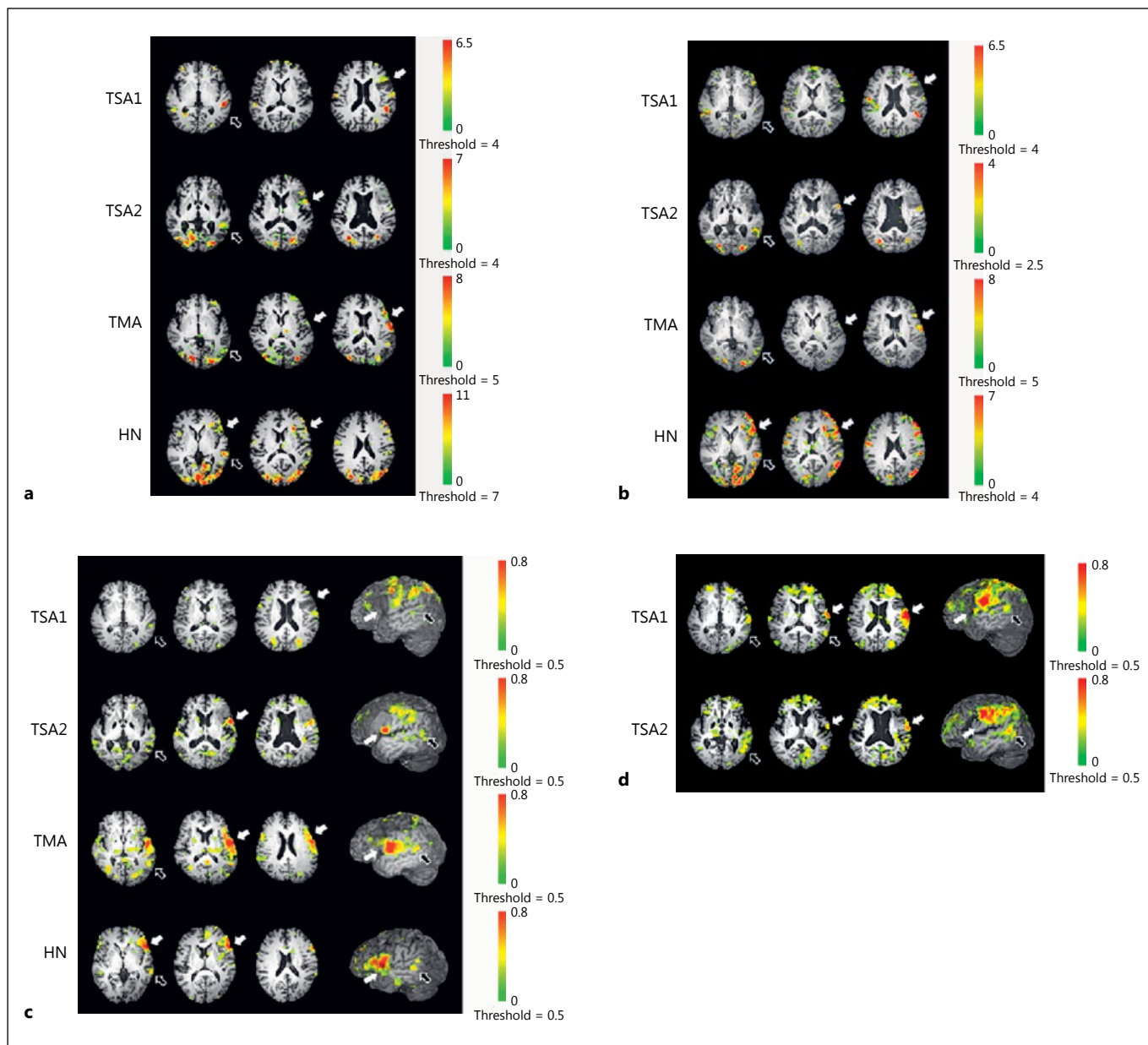
### Follow-Up Language Tests

Follow up K-WAB tests at 3 months post stroke showed that the AQ score of TSA1 increased to the normal range (AQ 94.0/100). However, he sometimes used vocal rehearsal in auditory comprehension tests, a strategy to compensate for incomplete recovery. The AQ score of TSA2 also increased, but she still had mild-to-moderate TSA (AQ 67.3/100).

### fMRI Results

The results of single-subject analysis using non-normalized data in the acute stage of stroke showed brain activation in TSA1 and TSA2 in perilesional areas of the frontal lobe and temporal regions during the sentence completion task (Fig. 2a). During the verb generation task (Fig. 2b), the activated areas were similar to those for the sentence completion tasks except that tem-





**Fig. 2.** The results of the initial fMRI induced by sentence completion (a), and verb generation task (b) of the subjects. The white and black arrows indicate respectively Broca's and Wernicke's areas activated in each subject. In the initial (c) and follow-up rs-fMRI study (d), the white and black arrows indicate respectively the anterior and posterior language areas connected from the seed ROI (Broca's regions activated on stimulus-induced fMRI area). The

right column of (c) and (d) shows functional connectivity locations in sagittal view (with left 40–50 mm cutout option) over 3D volume rendered T1 images. TSA1, patient 1 with transcortical sensory aphasia; TSA2, patient 2 with transcortical sensory aphasia; TMA, patient with transcortical motor aphasia; HN, healthy normal adult.

poral activation was decreased in TSA1. The overall signal was low in the verb generation task.

TMA had stronger frontal activation and HN showed broad activation in the frontal and temporo-occipital areas compared with TSA patients during both tasks.

### DTI Tractography

The results of tractography showing the AF in the left hemisphere of the patients with TSA in the acute stage demonstrated that the structural connectivity of language areas through the AF were preserved in these patients (Fig. 3).

### rs-fMRI Results

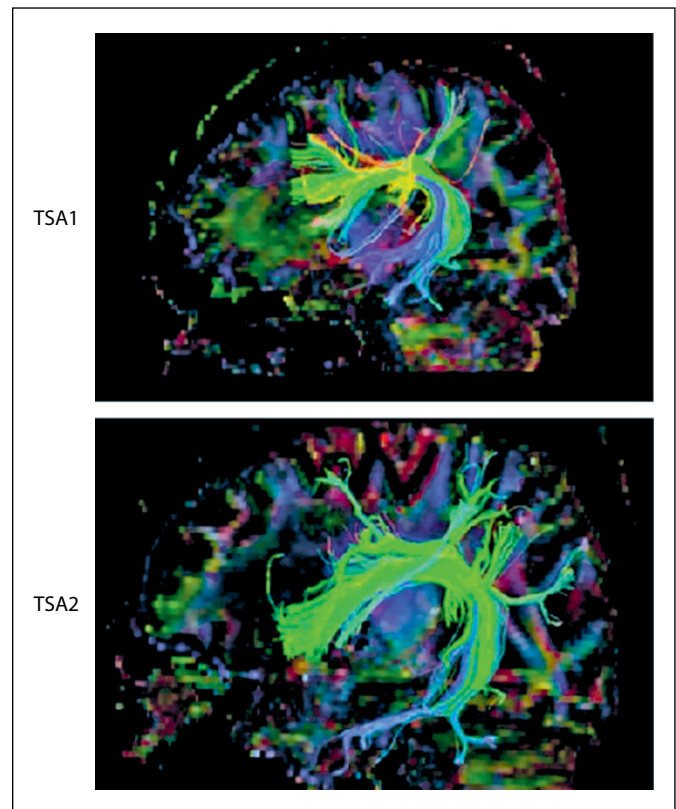
The results of seed-based analysis of the rs-fMRI performed in the acute stage showed significantly decreased resting-state functional connectivity in the language network compared with the control subjects (Fig. 2c). There were weak correlations in the left perilesional and temporo-parietal areas in TSA patients. By contrast, TMA had strong correlations between the frontal and temporal language areas with some scattered regions in the frontal and temporal lobe of both hemispheres. A similar pattern was observed in HN.

On the follow-up study, there were significant changes of the connectivity patterns in both TSA patients (Fig. 2d); there were stronger connections between the seed area and fronto-temporal language area and some additional connections in the frontal and parietal lobes.

### Discussion

In patients with TSA with frontal lobe lesions, one of putative mechanisms of impaired auditory comprehension is the concomitant presence of hypoperfusion in the posterior language area [5, 7]. However, our patients did not show diffusion-perfusion mismatches (Fig. 1), and did not support this hypothesis. Although TSA2 patient had an additional parietal infarct (Fig. 1), the lesion was small and located far from language centers. Thus, it is highly unlikely that the lesion was causally associated with patient's severe aphasia. It is also unlikely that the moderate white matter ischemic changes in this patient produced the patient's aphasia, although these lesions may be attributed to the relatively slow recovery of language function as compared to TSA1 patient.

Another hypothesis is an involvement of a part of the frontal lobe that plays a role in auditory comprehension of grammatically complex sentences [8, 9]. However, our patients demonstrated impaired auditory comprehension even at the single word level, illustrating that this hypothesis is also unlikely. Finally, anomalous inter- or intrahemispheric representation of language centers has been suggested as the mechanism, that is, Broca's area representing receptive language and Wernicke's area expressive language [6, 10]. However, although our fMRI study results showed individual differences, there was no reversed intrahemispheric activation pattern or dissociative activation in the right



**Fig. 3.** The diffusion tensor tractographies of arcuate fasciculus in patients with TSA. TSA1, patient 1 with transcortical sensory aphasia; TSA2, patient 2 with transcortical sensory aphasia.

hemisphere exceeding that of normal subjects during the language tasks (Fig. 2a, b), suggesting that this is an unlikely hypothesis.

In our patients, the result of seed-based analysis of rs-fMRI performed in the acute stage showed significantly decreased resting-state functional connectivity in the language network even though there was relatively preserved structural connectivity. Weaker correlations were observed between the seed area (Broca's) and temporal regions compared with those seen in the control subjects (Fig. 2c). Follow-up tests revealed improved connectivity, with strong correlations in the superior and middle temporal gyri as well as the prefrontal and parietal lobes (Fig. 2d). These results together with relatively preserved structural connectivity shown in DTI tractography (Fig. 3) suggest that functional rather than structural disconnections between the language centers explain patients' symptoms [11]. The preserved speech fluency in our TSA1 and TSA2 patients may be explained by the relatively preserved precentral gyrus and superior frontal lobe as compared to TSM patients (Fig. 1), that were reported

to be responsible for spontaneous speech production [2, 3, 12].

One notable limitation in this study was the small number of patients, which was attributed to the rareness of this condition. Therefore, our results may not be applicable for all such patients, and do not rule out the possibility of other mechanisms. Nevertheless, our results demonstrated that functional disconnections between language centers in the acute stage of the stroke explain the occurrence of TSA in patients with frontal lobe infarction.

## References

- 1 Boatman D, Gordon B, Hart J, Selnes O, Miglioretti D, Lenz F: Transcortical sensory aphasia: revisited and revised. *Brain* 2000; 123(pt 8):1634–1642.
- 2 Otsuki M, Soma Y, Koyama A, Yoshimura N, Furukawa H, Tsuji S: Transcortical sensory aphasia following left frontal infarction. *J Neurol* 1998;245:69–76.
- 3 Maeshima S, Kuwata T, Masuo O, et al: Transcortical sensory aphasia due to a left frontal subcortical haemorrhage. *Brain Inj* 1999;13:927–933.
- 4 Maeshima S, Osawa A, Nakayama Y, Miki J: Transcortical sensory aphasia following infarction in the left frontal lobe. *Eur Neurol* 2004;52:125–128.
- 5 Sethi NK, Burke L, Torgovnick J, Arsura E: Transcortical sensory aphasia as a result of left frontal cortical-subcortical infarction. A case report. *Eur Neurol* 2007;57:52–53.
- 6 Kim EJ, Suh MK, Lee BH, et al: Transcortical sensory aphasia following a left frontal lobe infarction probably due to anomalously represented language areas. *J Clin Neurosci* 2009; 16:1482–1485.
- 7 Turken AU, Dronkers NF: The neural architecture of the language comprehension network: converging evidence from lesion and connectivity analyses. *Front Syst Neurosci* 2011;5:1.
- 8 Caplan D, Hildebrandt N, Makris N: Location of lesions in stroke patients with deficits in syntactic processing in sentence comprehension. *Brain* 1996;119(pt 3):933–949.
- 9 Stromswold K, Caplan D, Alpert N, Rauch S: Localization of syntactic comprehension by positron emission tomography. *Brain Lang* 1996;52:452–473.
- 10 Berthier ML: Unexpected brain-language relationships in aphasia: evidence from transcortical sensory aphasia associated with frontal lobe lesions. *Aphasiology* 2001;15:99–130.
- 11 Lim JS, Kang DW: Stroke connectome and its implications for cognitive and behavioral sequela of stroke. *J Stroke* 2015;17:256–267.
- 12 Enokido H, Torii H, Ainoda N, Hanyu T, Omori S: [Spontaneous speech disturbances in so called transcortical motor aphasia – comparison of 3 cases with the different lesion sites]. *No To Shinkei* 1984;36:895–902.

## Acknowledgments

This work was supported by Basic Science Research Program through the Ministry of Education of the Republic of Korea and National Research Foundation (NRF-2015R1D1A1A09060547) and by a grant from the Ministry for Health, Welfare and Family Affairs, Republic of Korea (HI14C1985).

## Disclosure Statement

The authors report no conflicts of interest.