


Accepted Manuscript

Status epilepticus secondary to pseudonodular hemorrhagic occipital lesion with edema: “Non semper ea sunt, quae videntur, decipit frons prima multos” (things are not always what they seem; the first appearance deceives many)

Davide Nasi, M.D., Franco Servadei, M.D., Antonio Romano, M.D



PII: S1878-8750(17)30813-6

DOI: [10.1016/j.wneu.2017.05.114](https://doi.org/10.1016/j.wneu.2017.05.114)

Reference: WNEU 5808

To appear in: *World Neurosurgery*

Received Date: 26 March 2017

Revised Date: 15 May 2017

Accepted Date: 18 May 2017

Please cite this article as: Nasi D, Servadei F, Romano A, Status epilepticus secondary to pseudonodular hemorrhagic occipital lesion with edema: “Non semper ea sunt, quae videntur, decipit frons prima multos” (things are not always what they seem; the first appearance deceives many), *World Neurosurgery* (2017), doi: 10.1016/j.wneu.2017.05.114.

This is a PDF file of an unedited manuscript that has been accepted for publication. As a service to our customers we are providing this early version of the manuscript. The manuscript will undergo copyediting, typesetting, and review of the resulting proof before it is published in its final form. Please note that during the production process errors may be discovered which could affect the content, and all legal disclaimers that apply to the journal pertain.

Status epilepticus secondary to pseudonodular hemorrhagic

occipital lesion with edema:

“Non semper ea sunt, quae videntur, decipit frons prima multos”

(things are not always what they seem; the first appearance deceives many)

Davide Nasi M.D. 1, Franco Servadei M.D. 2, Antonio Romano M.D 2

1 Department of Neurosurgery of Institute for Scientific and Care Research "ASMN" of Reggio Emilia, Reggio Emilia, Italy

2 Neurosurgery-Neurotraumatology Unit of University Hospital of Parma, Parma and Department of Neurosurgery of Institute for Scientific and Care Research "ASMN" of Reggio Emilia, Reggio Emilia, Italy

Corresponding author:

Davide Nasi, M.D.

Department of Neurosurgery of Institute for Scientific and Care Research "ASMN" of Reggio Emilia,
Reggio Emilia, Italy

Viale Risorgimento 80, 42121, Reggio Emilia, Italy

Telephone: +39 0522296070; Mobile: +39 3483887309; Fax: +39 522296070

Email: davidenasi83@gmail.com

Clinical Image

Conflict of interest: None.

Abstract

We report a common radiological images that hide an infrequent case of a supratentorial hemangioblastoma (HBL). Others peculiarities of this case are the clinical presentation with a status epilepticus and the occurrence of a supratentorial HBL unrelated with Von Hippel Lindedeau Syndrome (VHL). Based on clinical and radiological findings including massive cerebral edema and hemorrhagic presentation, our preoperative diagnosis was a cerebral metastasis.

In this scenario, physicians must be taken into account the words of Phaedrus, a Roman fabulis: “Non semper ea sunt, quae videntur, decipit frons prima multos” (things are not always what they seem; the first appearance deceives many).

Clinical Image

A 61-year-old man was admitted to our clinic for continuous tonic-clonic seizures. A computed tomography (CT) scan showed a hyperdense hemorrhagic lesion located in the left occipital lobe with large cerebral edema and homogeneous contrast enhancement (Fig. 1ab). The MRI FLAIR-weighted images showed intra-axial pseudo nodular lesion in left occipital lobe surrounded by a hypointense rim of hemosiderin and with edema (Fig 1c). T1-weighted post-gadolinium coronal image confirmed homogeneous contrast enhancement (Fig 1d). MRI sagittal susceptibility weighted imaging (SWI) sequence revealed a draining hypertrophied vein (Fig. 1e). Spinal MRI showed no others lesions and ophthalmologic evaluation revealed homonymous hemianopsia vision loss.

Based on clinical and radiological findings, the most likely diagnosis was cerebral metastasis, despite total-body CT scan was unsuccessful in detecting primary tumors. Other possible diagnosis

was cavernous angioma. A left occipital craniotomy was performed to resect the mass with the aid of neuronavigation system. During surgery, a well-circumscribed lesion with abnormal vascular structures both inside and around was found (Fig. 2a). An arterialized draining vein was localized on the superior pole of the lesion (Fig. 2a). After disconnection of vascular feeders (Fig. 2b), a gross total resection was achieved (Fig. 2c). Interestingly, after resection of hemangioblastoma, the cortical draining vein was no longer arterialized (Fig. 2d).

The main surgical aspects were illustrated in Video 1. Post-operative course was uneventful and CT scan confirmed the total resection of the mass (Fig 2e). Histopathological examination of the surgical specimen demonstrated characteristic features of hemangioblastoma (WHO grade I) [HBL].

Further radiological investigations and genetic test excluded Von Hippel Lindau Syndrome (VHL). Patient's follow-up revealed marked improvement in his visual field 3 months after surgery.

Hemangioblastomas (HBL) of the CNS are rare vascularized neoplasms often associated with VHL syndrome [1-3]. Supratentorial location is particularly uncommon [3].

To our best knowledge, status epilepticus secondary to a HBL has not been previously reported in the literature. Other peculiarities were supratentorial location, the presence of massive peritumoral edema and hemorrhagic presentation which were not characteristic of HBL [1-3].

In conclusion, this report portrays also our pitfall in the initial diagnosis of a supratentorial HBL which we misinterpreted as a cerebral metastasis or cavernous angioma [4].

In this scenario, physicians must be taken into account the words of Phaedrus, a Roman fabulist: "Non semper ea sunt, quae videntur, decipit frons prima multos" (things are not always what they seem; the first appearance deceives many).

Compliance with ethical standards

Funding: No funding was received for this research.

Conflict of interest: None.

Informed consent: Informed consent was obtained from all individual participants included in the study.

References

1. Mills SA, Oh MC, Rutkowski MJ, Sughrue ME, Barani IJ, Parsa AT. Supratentorial hemangioblastoma: clinical features, prognosis, and predictive value of location for von Hippel-Lindau disease. *Neuro Oncol.* 2012 Aug;14(8):1097-104.
2. Pandey S, Sharma V, Pandey D, Kumar V, Kumar M. Supratentorial haemangioblastoma without von Hippel-Lindau syndrome in an adult: A rare tumor with review of literature. *Asian J Neurosurg.* 2016 Jan-Mar;11(1):8-14.
3. Lonser RR, Butman JA, Huntoon K, Asthagiri AR, Wu T, Bakhtian KD, Chew EY, Zhuang Z, Linehan WM, Oldfield EH. Prospective natural history study of central nervous system hemangioblastomas in von Hippel-Lindau disease. *J Neurosurg.* 2014 May;120(5):1055-62
4. Nasi D, Somma Ld, Iacoangeli M, Liverotti V, Zizzi A, Dobran M, Gladi M, Scerrati M. Calvarial bone cavernous hemangioma with intradural invasion: An unusual aggressive course-Case report and literature review. *Int J Surg Case Rep.* 2016;22:79-82.

Figure Legend**Fig. 1** Preoperative neuroimaging studies.

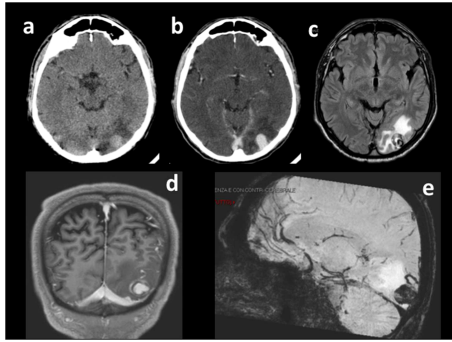
- a,b.** A precontrast computed tomography (CT) scan showed a hyperdense hemorrhagic lesion located in the left occipital lobe with large cerebral edema; after administration of contrast medium, the lesion showed a homogeneous contrast enhancement
- c.** The MRI FLAIR-weighted images showed intra-axial pseudo nodular lesion in left occipital lobe with edema surrounded by a hypointense rim of hemosiderin
- d.** T1-weighted post-gadolinium coronal image demonstrated homogeneous contrast enhancement
- e.** The signal void of hypertrophied vessel was shown in the superior aspect of tumor. MRI sagittal susceptibility weighted imaging (SWI) sequence confirmed a drainage hypertrophied vein

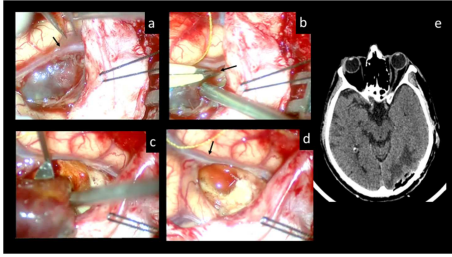
Fig. 2 Intraoperative images and post-operative CT scan

- a.** After a left occipital craniotomy and dura opening, a well-circumscribed lesion with abnormal vascular structures both inside and around was found; an arterialized draining vein was localized on the superior pole of the lesion (black arrow)
- b.** Disconnection of vascular feeders of hemangioblastoma (black arrow)
- c.** A gross total resection was achieved at the end of surgery

- d. After disconnection of fistulous feeder of hemangioblastoma, the cortical draining vein was no longer arterialized (black arrow)
- e. A post-operative CT scan confirmed the total resection of the mass

ACCEPTED MANUSCRIPT





ACCEPTED MANUSCRIPT

Highlights

1. Hemangioblastomas (HBL) are very rare lesions
2. Supratentorial location is uncommon and almost always associated with Von Hippel Lindau Syndrome (VHL)
3. In supratentorial HBL, status epilepticus and hemorrhagic presentation were not yet reported.
4. We report a common hemorrhagic lesion with edema that hide an infrequent case of a supratentorial HBL

Abbreviations list:

HBL. Hemangioblastoma

VHL. Von Hippel Lindedeau Syndrome

CT. Computed tomographic scan

MRI. Magnetic resonance imaging

DMARD_s. New disease modifying antirheumatic drugs