



Case report

Recurrent dysphasia due to nivolumab-induced encephalopathy with presence of Hu autoantibody



Jo Raskin^{a,*}, Pegah Masrori^b, Antonin Cant^b, Annemie Snoeckx^c, Birgitta Hiddinga^a, Sisca Kohl^a, Annelies Janssens^a, Patrick Cras^{b,d}, Jan P. Van Meerbeek^{a,e}

^a Department of Thoracic Oncology, Antwerp University Hospital, Edegem, Belgium

^b Department of Neurology, Antwerp University Hospital, Edegem, Belgium

^c Department of Radiology, Antwerp University Hospital, Edegem, Belgium

^d Born Bunge Institute, Faculty of Medicine and Health Sciences, University of Antwerp, Antwerp, Belgium

^e Center for Oncological Research, University of Antwerp, Antwerp, Belgium

ARTICLE INFO

Keywords:

Nivolumab
Non-small-cell lung cancer
Immune-related adverse event
Hu paraneoplastic antibody
Neurological toxicity
Dysphasia

ABSTRACT

A 58-year-old man was being treated for squamous non-small-cell lung cancer with nivolumab. At the 17th of biweekly administrations he presented with global dysphasia, dysarthria and myoclonus in the right upper extremity. MRI showed multiple T2/FLAIR hyperintense lesions in the left hemisphere; lumbar puncture showed lymphocytic pleiocytosis in the CSF without identifiable pathogens. Hu antibodies were present in serum and CSF. Nivolumab was discontinued and corticosteroids were administered. The neurological symptoms gradually improved; MRI showed complete remission of cerebral lesions. After rechallenge with nivolumab his symptoms and cerebral lesions recurred, proving the causal relationship with nivolumab. After tapering of corticosteroids, a second relapse occurred.

1. Introduction

Nivolumab (Opdivo®, Bristol-Myers Squibb, New York, NY) is a genetically engineered, fully human immunoglobulin G4 monoclonal antibody which binds PD-1 (short for programmed death-1) with high affinity, thus blocking interaction with its ligands PDL-1 and PDL-2 [1]. PD-1 is an immune regulatory protein (checkpoint inhibitor) expressed by a variety of immune cells (CD4+ and CD8+ T-lymphocytes, regulatory T-lymphocytes, B-lymphocytes and natural killer cells). Its ligands PDL-1 (CD274/B7-H1) and PDL-2 (CD273/B7-DC) are expressed by macrophages and dendritic cells; additionally, PDL-1 is expressed by lymphocytes [2]. PDL-1 is upregulated on solid tumour cells by activation of interferon by cytotoxic T-lymphocytes and via oncogenic signalling through MAPK, PIK3 and EGFR pathways, thus downregulating effector T-cells, leading to immune tolerance of cancer cells and even escape from the immune system. Under normal circumstances, the PD1-ligand interaction forms an immune checkpoint, preventing auto-immunity and excess inflammation by suppression of effector T-cells [3,4]. Nivolumab is currently approved for treatment of metastatic malignant melanoma and non-small-cell lung cancer, but has demonstrated antitumoural activity in several other cancers. Inhibition of immune checkpoints raises concern for auto-

immune mediated adverse effects of treatment with nivolumab. Neurotoxicity is reported to be rare [5].

2. Case presentation

A 58-year-old man had received the 17th of biweekly administrations of nivolumab for stage IV squamous non-small-cell lung cancer (NSCLC), pre-treated with 2 lines of chemotherapy. Evaluation after 16 cycles showed confirmed partial response, with continuation of treatment.

He suddenly presented with new-onset speech impairment and mild myoclonus in the right arm since one week. No cerebral or leptomeningeal metastases had ever been found, and no existing neurological disease was known. His medication (denosumab, omeprazole and bisoprolol) had not been changed for the last 2 years.

He predominantly suffered from global dysphasia, limited speech (single words, stuttered three-word sentences) to almost complete muteness. His symptoms seemed to be worsened by stress, and by forcibly trying to explain himself. Neurological exam further revealed mild dysarthria, difficulties in performing complex tasks, reduced right forearm rolling and discrete flattening of the right nasolabial fold. His comprehension was not affected.

* Corresponding author at: Antwerp University Hospital, Wilrijkstraat 10, 2650 Edegem, Belgium.
E-mail address: jo.raskin@uza.be (J. Raskin).

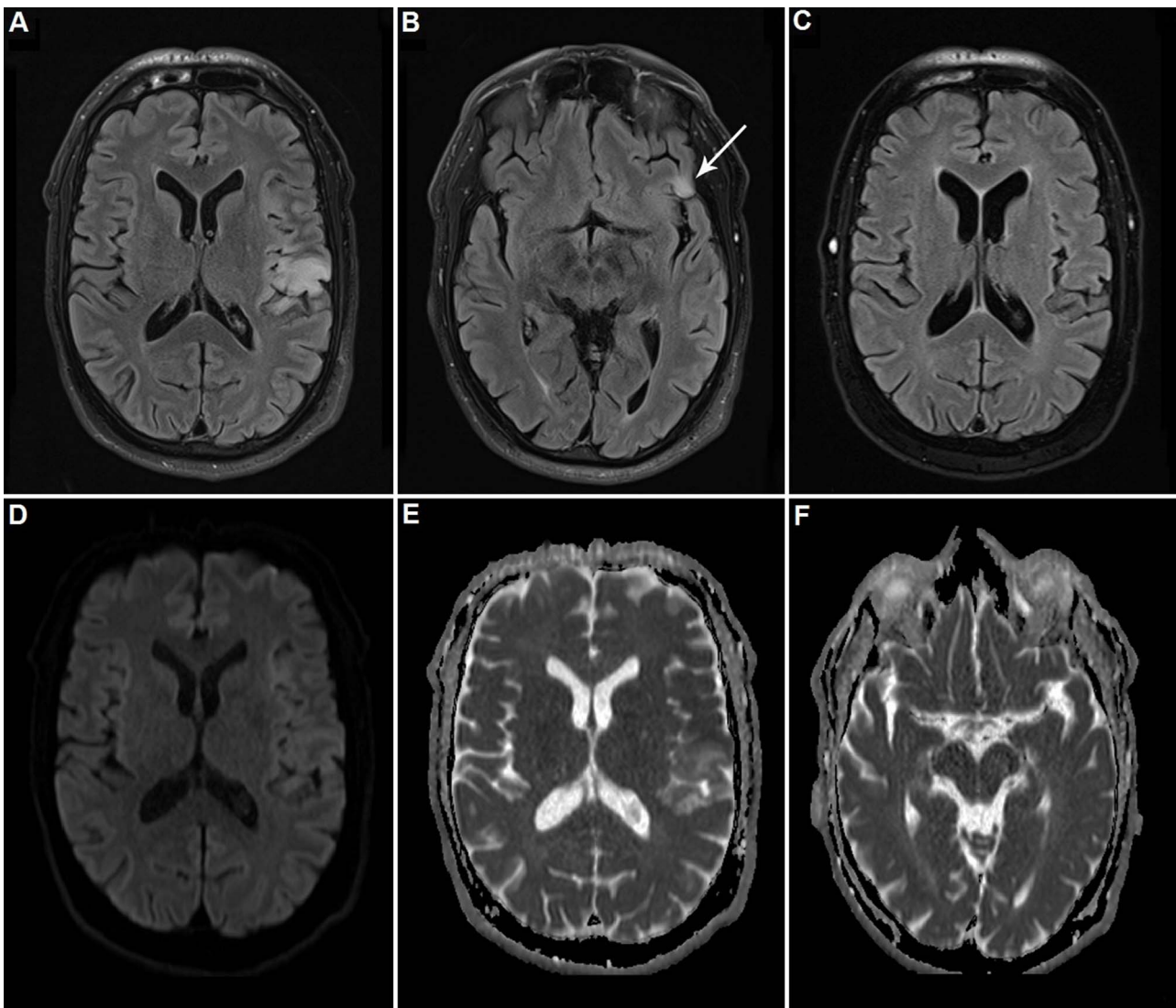


Fig. 1. MRI of the brain at first presentation. Axial FLAIR images show a large area of hyperintensity in the left insular cortex (A) and a small area of hyperintensity (B) in the left frontal operculum (white arrow). Axial FLAIR image (C) after discontinuation of Nivolumab shows normal findings with complete resolution of all T2 hyperintensities. At axial diffusion-weighted MR image ($b = 1.000 \text{ s/mm}^2$) only very slight increase in signal intensity in the area of the left insular cortex and slight decrease of signal intensity on the apparent diffusion coefficient (ADC) map, corresponding to only very mild diffusion restriction (D-E). No diffusion restriction is seen in the lesion in the left operculum (F).

A work-up with EEG, magnetic resonance imaging (MRI), blood analysis and lumbar puncture was performed. Full blood count showed no abnormalities. EEG showed moderate diffuse slowing with focal epileptic activity in the temporal cortex, corresponding at MRI to areas of increased T2/FLAIR relaxation time in the left hemisphere: in the frontal operculum, in the posterior part of the sylvian fissure and insula and in the parafalcine superior parietal cortex and subcortical white matter (Fig. 1A–C). The large lesion in the insula showed very slight diffusion restriction (Fig. 1D–E), too limited to be compatible with ischemic stroke. No diffusion restriction was seen in the smaller lesions (Fig. 1F). Cerebral ischaemia or vasculitis was considered very unlikely and not further investigated. No cerebral or leptomeningeal metastases were found. A repeat MRI one week later showed a fourth lesion in the parietal subcortical white matter and a more pronounced diffusion restriction.

A lumbar puncture showed an inflammatory cerebrospinal fluid (Table 1); this finding was confirmed on a second sample one week later. Extensive cultures with viral and microbial PCRs remained negative. No malignant cells were found. Anti-Hu antibodies in serum and CSF (immunofluorescence and confirmation with immunoblot), would later return positive. Other antineuronal antibodies (anti-am-

physin, anti-PNMA2, anti-Ri, anti-Yo, anti-recoverin, anti-SOX1, anti-titin, anti-zic4, anti-GAD65, anti-Tr, anti-CASPR2, anti-LGI1 and anti-NMDA-receptor, anti-AMPA1-receptor, anti-AMPA2-receptor, anti-GABAb-receptor) were not present.

Empirical treatment with ceftriaxone (2 g/12 h) and ampicillin (2 g/4 h) was initiated, with association of levetiracetam (1000 mg/12 h); nivolumab was discontinued and dexamethasone (8 mg/24 h) administered. Over the next few weeks, his speech progressively improved, with disappearance of the brain lesions five weeks later on MRI (Fig. 1C), and normal speech eight weeks after diagnosis. Corticosteroids were gradually tapered and discontinued after twelve weeks of treatment. At this moment a new chest computed tomography (CT) unfortunately showed significant tumour progression.

As no valid other treatment was available, rechallenge with nivolumab was proposed, in accordance with successful rechallenges reported in other patients [6]. An identical aphasia syndrome occurred after three cycles of nivolumab. Relapse of lesions was present at MRI (Fig. 2A), although less pronounced, on EEG, in spite of ongoing treatment with levetiracetam, and with similar lymphocytic pleiocytosis and anti-Hu antibodies in the CSF. Dexamethasone was restarted. With this, his EEG normalized and his speech slowly returned to

Table 1
Results of cerebral fluid analysis on day 1 and day 10 of first presentation, at first (FR) and second (SR) recurrence.

Lumbar puncture	1	10	FR	SR	Units
WBCs	63 (96.8% mononuclear)	24 (100% mononuclear)	61 (70.5% mononuclear)	3	/mm ³
RBCs (/mm ³)	< 1000	< 1000	< 1000	< 1000	/mm ³
Cultures	negative	negative	negative	negative	
Glucose [40–70]	90	108	75	78	mg/dl
Protein [15–40]	74	67	77	49	mg/dl
IgG [< 5.5]	6.0	ND	5.4	7.73	mg/dl
Lactic acid [0.6–2.2]	ND	2.7	2.6	ND	mmol/l
Oligoclonal bands	YES	ND	YES	YES	
Flow cytometry	ND	ND	normal	ND	

Abbreviations: RBC = red blood cell, WBC = white blood cell, ND = not determined.

normal.

Corticosteroids were gradually tapered over the next twelve weeks. Once corticosteroid-free, a second relapse of aphasia took place, more than fifteen weeks after the last administration of nivolumab. Again, EEG findings were similar. Hu autoantibodies were confirmed. The initial lesion in the left thalamus had increased in size (Fig. 2B). Dexamethasone was restarted, with dose increase of levetiracetam and association of valproic acid. Currently his speech remains normal with a maintenance dose of 6 mg dexamethasone.

3. Discussion

Inhibitors of the PD-1/PD-L1 pathway, also called checkpoint inhibitors, have been shown to cause a wide array of immune-related adverse events [5,7]. The exact mechanism is unknown: a central role for unchecked T-cell activity is being assumed, possibly with a contribution of antibody production by B-cells or cytokine release by granulocytes [8]. As anti-Hu neuronal antibodies were present in our patient’s CSF and serum, nivolumab-triggered antibody production or direct cytotoxic T-cell response to tumour antigen cross-reacting with brain epitopes, may have been responsible. Hu antigen is almost exclusively present in neuronal tissue, but may ectopically be expressed by cancer cells, especially in small-cell lung cancer. Expression in non-small-cell lung cancer is uncommon [9]. Hu antibody (also known as type 1 anti-neuronal nuclear antibody [ANNA-1]) is a well-known

paraneoplastic antibody and has been associated with several neurological syndromes, including sensory neuropathy, cerebellar ataxia and (limbic) encephalitis [10].

PD-(L)1-inhibitor treatment-related grade 3/4 adverse events are not uncommon, being reported in 7–10% in phase III studies in non-small-cell lung cancer [1,11]. Neurological adverse events are very rare, phase III studies only reporting 5 cases in 564 patients (0.89%) treated with nivolumab, of which 2 minor (dizziness) and 3 grade ≥3 (lethal encephalitis, initially not attributed to nivolumab; cerebrovascular accident; and myasthenic syndrome) [1,11].

Case reports describing several neurological syndromes, such as dysgeusia, in- and hypersomnia, restless legs syndrome, tremor, lethargy, impaired memory, vertigo, dysarthria, cerebral oedema, peripheral neuropathy, optic neuritis, myasthenia gravis, multifocal CNS demyelination, ... are summarized by Zimmer, with additionally describing 16 cases of neurological adverse events in melanoma, of which 5 grade ≥3 [4]. This gives an incidence of 5/496 (1.0%). Median time to onset of symptoms was 9.5 weeks after first administration (range 1–68 weeks).

Mandel reported a case of ataxia, vertigo and numbness in the left arm in a melanoma patient receiving pembrolizumab, another PD-1 inhibitor, who had previously also been treated with ipilimumab. He developed FLAIR hyperintensities in the claustrum, right frontal and left occipital lobes. EEG showed partial motoric status epilepticus, but no lymphocytic pleiocytosis was found at lumbar puncture [12]. These

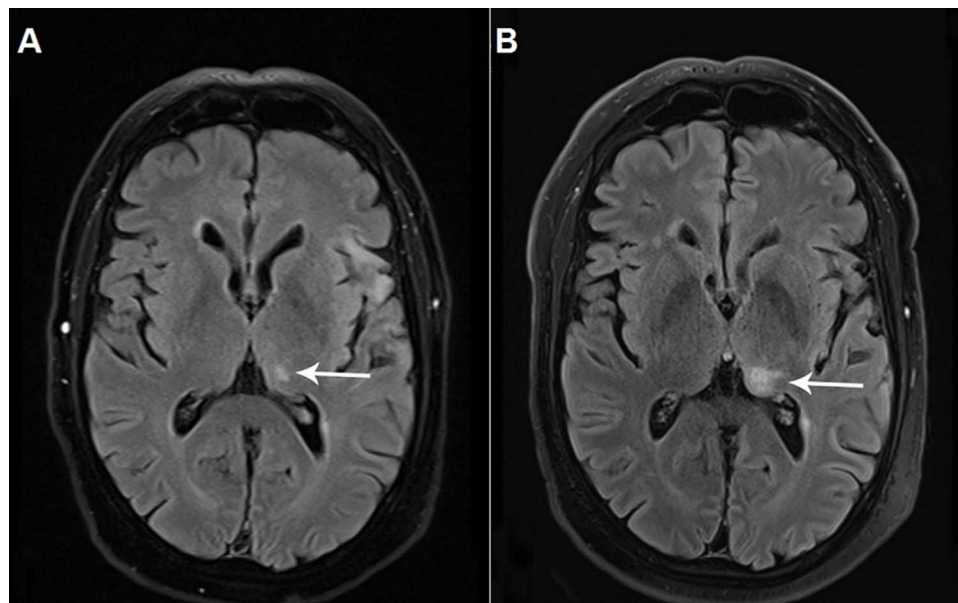


Fig. 2. Axial FLAIR image (A) after rechallenge shows a new small T2 hyperintensity lesion in the left thalamus (white arrow) and recurrence of T2-hyperintensities in the left insular cortex. Axial FLAIR image (B) at the second recurrence of clinical relapse clearly shows an increase in size of the thalamic T2-hyperintensity lesion (white arrow).

findings and further evolution after discontinuation of pembrolizumab strongly resembles our case, but to our knowledge, this case is the first in which presence of a paraneoplastic (Hu) antibody is documented.

4. Conclusion

Severe neurological immune-related adverse events of nivolumab are rare, with an incidence of < 1%, and might present with a wide array of neurological syndromes, mimicking infectious, inflammatory, vascular or malignant aetiologies. Onset might be early after first administration, weeks or months later, or even after discontinuation of nivolumab, as the immune activation might persist. Discontinuation of nivolumab and slowly tapering of corticosteroids are essential in management of this kind of neurotoxicity. A high sense of clinical awareness coupled with appropriate neurological imaging is needed in order to raise the diagnosis. There is presently no diagnostic test; an empiric approach of drug discontinuation and treatment with corticosteroids is the current management of choice.

Conflicts of interest

None.

Acknowledgement

This research did not receive any specific grant from funding agencies in the public, commercial, or not-for-profit sectors.

References

- [1] J. Brahmer, K.L. Reckamp, P. Baas, L. Crinò, W.E.E. Eberhardt, E. Poddubskaya, S. Antonia, A. Pluzanski, E.E. Vokes, E. Holgado, D. Waterhouse, N. Ready, J. Gainor, O. Arén Frontera, L. Havel, M. Steins, M.C. Garassino, J.G. Aerts, M. Domine, L. Paz-Ares, M. Reck, C. Baudelet, C.T. Harbison, B. Lestini, D.R. Spigel, Nivolumab versus docetaxel in advanced squamous-cell non-small-cell lung cancer, *New Engl. J. Med.* 373 (2015) 123–135.
- [2] M.E. Keir, L.M. Francisco, A.H. Sharpe, PD-1 and its ligands in T-cell immunity, *Curr. Opin. Immunol.* 19 (3) (2007) 309–314.
- [3] H. Dong, G. Zhu, Tamada K. B7-H1, a third member of the B7 family, co-stimulates T-cell proliferation and interleukin 10 secretion, *Nat. Med.* 5 (1999) 1365–1369.
- [4] T. Okazaki, T. Honjo, The PD-1-PD-L pathway in immunological tolerance, *Trends Immunol.* 27 (4) (2006) 195–201.
- [5] J. Naidoo, D.B. Page, B.T. Li, L.C. Connell, K. Schindler, M.E. Lacouture, M.A. Postow, J.D. Wolchok, Toxicities of the PD-1 and PD-L1 immune checkpoint antibodies, *Ann. Oncol.* 26 (2015) 2375–2391.
- [6] L. Spain, G. Walls, C. Messiou, S. Turajlic, M. Gore, J. Larkin, Efficacy and toxicity of rechallenge with combination immune checkpoint blockade in metastatic melanoma: a case series, *Cancer Immunol. Immunother.* 66 (2017) 113, <http://dx.doi.org/10.1007/s00262-016-1926-2>.
- [7] L. Zimmer, S.M. Goldinger, L. Hofmann, C. Loquai, S. Ugurel, I. Thomas, M.I. Schmidgen, R. Gutzmer, J.S. Utikal, D. Göppner, J.C. Hassel, F. Meier, J.K. Tietze, A. Forschner, C. Weishaupt, M. Leverkus, R. Wahl, U. Dietrich, C. Garbe, M.C. Kirchberger, T. Eigentler, C. Berking, A. Gesierich, A.M. Krackhardt, D. Schadendorf, G. Schuler, R. Dummer, L.M. Heinzerling, Neurological, respiratory, musculoskeletal, cardiac and ocular side-effects of anti-PD1 therapy, *Eur. J. Cancer* 60 (2016) 210–225.
- [8] J.S. Weber, S.J. Antonia, S.L. Topalian, D. Schadendorf, J.M.G. Larkin, M. Sznol, H.Y. Liu, I. Waxman, C. Robert, Safety profile of nivolumab in patients with advanced melanoma: a pooled analysis, *J. Clin. Oncol.* 33 (15s) (2015) (9018–9018).
- [9] J. Dalmau, H.M. Furneaux, C. Cordon-Cardo, J.B. Posner, The expression of the Hu (paraneoplastic encephalomyelitis/sensory neuronopathy) antigen in human normal and tumor tissues, *Am. J. Pathol.* 141 (1992) 881–886.
- [10] F. Graus, F. Keime-Guibert, R. Reñe, B. Benyahia, T. Ribalta, C. Ascaso, G. Escaramis, J.Y. Delattre, Anti-Hu-associated paraneoplastic encephalomyelitis: analysis of 200 patients, *Brain* 124 (2001) 1138–1148.
- [11] H. Borghaei, L. Paz-Ares, L. Horn, D.R. Spigel, M. Steins, N.E. Ready, L.Q. Chow, E.E. Vokes, E. Felip, E. Holgado, F. Barlesi, M. Kohlhäufel, O. Arrieta, M.A. Burgio, J. Fayette, H. Lena, E. Poddubskaya, D.E. Gerber, S.N. Gettinger, C.M. Rudin, N. Rizvi, L. Crinò, G.R. Blumenschein, S.J. Antonia, C. Dorange, C.T. Harbison, F. Graf Finckenstein, J.R. Brahmer, Nivolumab versus docetaxel in advanced nonsquamous-cell non-small-cell lung cancer, *New Engl. J. Med.* 373 (2015) 1627–1639.
- [12] J.J. Mandel, A. Olar, K.D. Aldape, I.W. Tremont-Lukats, Lambrolizumab induced central nervous system toxicity, *J. Neurol. Sci.* 344 (2014) 229–231.