

# Accepted Manuscript

Vertebrobasilar Insufficiency Due to Distal Posterior Inferior Cerebellar Artery Compression in Chiari 1.5

M. Burhan Janjua, MD., Iryna Ivasyk, Jeffrey P. Greenfield, MD., PhD



PII: S1878-8750(17)30788-X

DOI: [10.1016/j.wneu.2017.05.089](https://doi.org/10.1016/j.wneu.2017.05.089)

Reference: WNEU 5783

To appear in: *World Neurosurgery*

Received Date: 13 March 2017

Revised Date: 14 May 2017

Accepted Date: 16 May 2017

Please cite this article as: Janjua MB, Ivasyk I, Greenfield JP, Vertebrobasilar Insufficiency Due to Distal Posterior Inferior Cerebellar Artery Compression in Chiari 1.5, *World Neurosurgery* (2017), doi: 10.1016/j.wneu.2017.05.089.

This is a PDF file of an unedited manuscript that has been accepted for publication. As a service to our customers we are providing this early version of the manuscript. The manuscript will undergo copyediting, typesetting, and review of the resulting proof before it is published in its final form. Please note that during the production process errors may be discovered which could affect the content, and all legal disclaimers that apply to the journal pertain.

Vertebrobasilar Insufficiency Due to Distal Posterior Inferior Cerebellar Artery  
Compression in Chiari 1.5.

M. Burhan Janjua, MD., Iryna Ivasyk, Jeffrey P. Greenfield, MD., PhD

Department of Neurological surgery,  
Weill Cornell Medical College And New York Presbyterian Hospital,  
525 East, 68<sup>th</sup> Street, New York, NY 10065

Corresponding Author:

M. Burhan Janjua, MD.

Pediatric Neurosurgery Fellow

Weill Cornell Medical College And New York Presbyterian Hospital

[mburhanj@gmail.com](mailto:mburhanj@gmail.com)

314-477-0985 (Cell)

ACCEPTED MANUSCRIPT

**ABSTRACT**

Chiari malformation is characterized by radiographic evidence of herniation of cerebellar tonsils below the foramen magnum, and symptoms complex of headaches, breathing, swallowing or sleep difficulties, ataxia, restless, motor and/or sensory deficits. We report a case of a 34-year old female whose imaging indicated a Chiari 1.5 with brainstem (caudal medulla) herniation, and an expansive cervical syrinx. Her symptom complex showed signs both of cervical syringomyelia, as well as ones localizable to the medulla. An intradural exploration revealed the occlusion and caudal displacement of the loop of the right PICA which was later confirmed via magnetic resonance angiogram. In the setting of severe Chiari malformations, particularly the Chiari 1.5 variant, assessment of the posterior fossa vasculature may be useful in defining a subset of patients with pre-operative compromise in posterior fossa blood flow and post-operative expectations. Preoperative planning and exploration of midline dorsal brain stem along with the tonsilomedullary fissure could be helpful for contribution of vascular pathology among Chiari symptoms complex in these patients.

## INTRODUCTION

Chiari malformations are typically defined as herniation of part of rhombencephalon derivatives below the foramen magnum. The most commonly occurring subtype, Chiari malformation (CM) type I is typically defined as descent of the cerebellar tonsils 5mm below the foramen magnum. However, Chiari 1.5 specifically refers to the tonsillar herniation seen in Chiari I, but with the addition of caudal displacement of part of the brainstem (medulla). While a significant percentage of radiographically diagnosed Chiari malformations occur in relatively asymptomatic patients, symptoms in affected individuals are extremely variable and can be disabling.<sup>1</sup> Symptoms include, but are not limited to, tussive occipital headaches or neck pain (27-70%), irritability (12%), sensory and motor symptoms (6-17%), scoliosis with or without spinal syrinx (18-50%), swallowing difficulty (4-15%), central sleep apnea or bradycardia (4-13%), ataxia or poor coordination of movements (4-9%), facial numbness (7%), and auditory symptoms (2%).<sup>2-4</sup> Many Chiari-related symptoms are believed to be secondary to brainstem compression of cranial nuclei of the cervicomedullary region.<sup>3,5,6</sup> It is difficult to define symptoms as arising from tension on the exiting nerve roots versus from brainstem herniation as both have been suggested to directly account for lower cranial nerve dysfunction in Chiari 1.5 patients.

A contribution of vascular compromise to brainstem symptomatology has not been directly proposed within the Chiari malformations. Vertebrobasilar insufficiency (VBI) refers to a set of symptoms resulting from decreased blood flow in the posterior circulation of the brain. VBI, often provoked by sudden and temporary drops in blood pressure, can cause transient ischemic attacks. Postural changes often provoke these attacks. Heat and dehydration may also be contributing causes. Vertigo, blurry vision and ataxia are common symptoms of decreased blood flow within this distribution, and the symptoms may be very brief, lasting a few seconds to half an hour. Magnetic resonance imaging (MRI) will detect ischemic changes in the vertebrobasilar distribution and may be used to identify vertebrobasilar stenoses or occlusions but magnetic resonance angiography (MRA) is more appropriate for definitive evaluation of the posterior fossa vasculature arteries.

Vascular imaging in the form of computerized tomographic angiography (CTA) or MRA is rarely performed in the Chiari population unless the initial presenting constellations are severe enough (facial weakness or hemiparesis) to warrant an evaluation for acute stroke. Data is tenuous regarding the compression of vessels near the brainstem and only few reports have

been reported in CM I, but the radiographic data supporting this phenomenon is lacking.<sup>7-8</sup> Here, we report an interesting case of a patient with Chiari 1.5 in which we suggest that the neurologic symptom constellation was partially due to a focal compression and stenosis of a unilateral posterior inferior cerebellar artery (PICA). Previously published case reports have documented symptoms and signs of compression of caudal medulla by vertebral arteries or by the inferior cerebellar arteries associated with essential hypertension in patients with CM type I.<sup>9-10</sup>

Our case report is unique and we have proposed the association of VBI in Chiari 1.5 secondary to the long standing distal PICA compression by the caudal half of the herniated tonsil which has not been discussed before. Furthermore, we documented our findings with the intraoperative images, and postoperative imaging.

## METHODS

### Case presentation

A 34 year old female presented with complaints of bilateral leg heaviness, arm and leg numbness, neck pain, word finding difficulty, intermittent blurry vision, ataxia, and vertigo that has progressed rapidly over the last year. She described her neck pain as 5/10 on visual analogue scale (VAS), aggravated by valsalva maneuver, and associated with intermittent ataxia. She was referred to a neurologist who ordered an MRI and discovered the Chiari malformation associated with severe syringomyelia in the cervical segment of the spinal cord.

Her MRI showed a classic Chiari malformation type 1.5. Her cerebellar tonsils appeared pointed and grossly herniated, with the right tonsil extending 20mm below McRae's line (a radiographic line between basion and opisthion) to the level of the C1-C2 interspace. A continuous spinal syrinx 7mm in maximal diameter, extended from C2 to C7 (Figure 1). On coronal sequences, it was clear that her right cerebellar tonsil was larger than the left and wrapped around the dorsolateral portion of the brainstem causing focal compression. The patient was given extensive counseling regarding symptoms attributable to the aforementioned pathology, the risks and benefits associated with the proposed treatment of a decompression surgery, as well as possible alternatives. In retrospect, the symptoms were divisible into two categories: cervical cord-related and medulla-related. The neck pain, extremity heaviness and numbness in extremities were classically referable to her cervical syrinx. The exertional blurry vision, word finding difficulty, vertigo and ataxia, however, more localizable to the brainstem and were much more consistent with vertebrobasilar insufficiency (VBI).

### Procedural Details and Postoperative Course

The patient was taken to the operating room on an elective basis for a planned procedure. Prone positioning, opening and preparation of the field for the intradural portion of the case under the operating microscope was all performed as part of the suboccipital decompression surgery. A Y-shaped durotomy was initiated with the short arms over cerebellar hemispheres and the long arm was extended downwards below the atrophic tonsils. After tenting the dural leaflets, we proceeded with the exploration and subarachnoid dissection by mobilizing the large and grossly dysmorphic right tonsil. It was herniating across to the left with a flattened white tip

indicating ischemia. There was a visible depression and kink in the tonsil coincident with the level where the lip of the foramen magnum had been invaginating and resected. We dissected laterally until cranial nerve XI and the ipsilateral vertebral artery could be visualized. We gently lifted the tonsils to expose the obex, which was extremely low lying, confirming the diagnosis of Chiari Malformation Type 1.5. The obex was covered with adhesions and the posterior inferior cerebellar artery (PICA) was draped over it. PICA was grossly abnormal. It appeared white, stenotic, and atretic at the level of the external tonsillar compression, suggesting a chronic *external* compressive pathology. The vessel did not appear patent even after dissection and mobilization but we did not confirm this with doppler ultrasound due to the nonavailability of on hand equipment. (Figure 2). The obex was dissected free of adhesions to restore CSF communication which involved dissection of the arachnoid from around both PICAs. We then performed a tonsilopexy during which we were able to reduce the tonsil with gentle diathermy. As a result, CSF flow improved at the lateral aspects from lateral apertures (Lushka) around the brainstem. There remained less than optimal spontaneous CSF flow from the midline but it was improved from prior to PICA mobilization and arachnoid dissection. After irrigating the subarachnoid space, we sutured the autologous pericranial autograft in place. The procedure was performed by the senior surgeon (JPG).

The patient stayed in the ICU for 24 hours for pain control and neurologic assessments. On postoperative day 2, an MRA of the brain with and without contrast was obtained to better define the unexpected intraoperative findings of PICA compression. The images supported the absence of flow within the right-sided PICA in all sequences obtained. (Figure 3) On postoperative day 5 she was discharged home in a stable condition. During the three-month follow up evaluation, a repeat MRI cervical spine and an MRA were obtained. MRI revealed expected retro-cerebellar decompression with CSF flow voids confirming improved CSF flow around the foramen magnum and the brainstem. Clinically she demonstrated significant improvement in her heaviness, numbness and pain symptoms likely secondary to the resolution of her cervical syringomyelia. MRA findings were consistent with the immediate postoperative scan confirming the absence of flow within the PICA. (Figure. 4). Symptoms more referable to the brainstem such as blurriness, dizziness and ataxia as well as some minor speech difficulties, were moderately improved but not as dramatically as the syrinx-related symptoms.



## DISCUSSION

The contribution of vascular insufficiency to the complex of symptoms in Chiari malformation has been poorly explored and described. In our patient, we suggest that a chronic compressive etiology secondary to the malformation and tonsillar herniation led to two distinct symptom complexes. The constriction of the cervico-medullary junction produced a dissociation of the cranial and cervical subarachnoid spaces and subsequent development of syringomyelia. The pre-operative spinal-related symptoms, radiographic findings and symptom resolution all support this. The second complex, involving symptoms of brainstem nuclei dysfunction, much more consistent with a vertebrobasilar insufficiency, was less well-defined pre-operatively and has responded less robustly thus far to surgical decompression. We posit that progressive compression of the PICA due to long standing herniation led to derangements in blood flow to the brainstem. The chronicity permitted adequate collateral flow to develop and thus a frank brainstem infarct or classic Wallenberg syndrome did not occur, but symptoms, exacerbated by valsalva were clearly manifest.

This case challenged us to consider that in addition to frank compression of the cerebellum or brainstem, part of the extensive symptom complex in Chiari malformation may have a component mediated through vascular compromise. We began by investigating the literature to identify any previous reports of related findings or proposals for a contribution of vertebrobasilar insufficiency (VBI) in Chiari patients. There are a few case reports eluding the phenomenon by compression of medulla by adjoining vascular structures. VBI encompasses posterior circulation transient ischemic attack (TIA) like symptoms ranging from rotational hemodynamic insufficiency that might result from degenerative cervical spine changes and cervical manipulation or secondary to poor flow through the terminal branches of the posterior circulation, which supply blood to the areas of brain, such as the thalamus, hippocampus, occipital lobe, and cerebellum, involved with intellectual functions of memory, and visual-spatial functioning. Merely attenuating flow through the stenotic segments of arteries supplying these important areas without accompanying structural infarcts could produce a VBI symptoms complex. Visual spatial derangements have been reported in children with Chiari undergoing neuropsych evaluations and memory impairments, though poorly studied, remain one of the most poorly explained, but very commonly reported symptom in adults with Chiari symptomatology.

Severe and acute neurological manifestation from VBI may seldom appear because of contralateral vertebral artery (VA) or other collateral flow. The symptoms are fairly broad and could range from transient attacks, syncope, dizziness, ataxia, (brainstem symptoms) to the symptoms of cognitive decline, i.e., confusion, amnesia, word finding difficulty or slurred speech, visual agnosia (occipital cortex symptoms). The treatment ranges from minimizing head movements to surgical procedures designed to limit head rotation or to decompress and free the vertebral artery or distal branches at the point of maximal compression.<sup>11-12</sup>

Some studies have discussed that the disturbance of the brainstem reticular activating system due to intermittent compression of baroreceptors in medulla by cerebellar tonsils through backflow of CSF after each valsalva maneuver might contribute to syncope or VBI in CM I or 1.5.<sup>13,14</sup> In 1991, Weig et al., documented recurrent syncope as the only presenting complaint in case series of 2 young patients with CM I. The exam findings were completely non-focal, based on the radiographic evidence, and a suboccipital decompression surgery was performed which led to the complete resolution of their symptoms. The direct brainstem compression and vascular compression was thought to be a likely etiology to their symptoms which responded well to the surgical intervention.<sup>15</sup>

In another study of 8 patients with Chiari I or 1.5 presented with symptoms ranging from common complaints of occipital pain, unsteadiness, gait disturbances, loss of bowel and bladder control, and motor and sensory symptoms. Besides basilar impression or cervical fusion or occipitalization, the descended PICA was visualized in all cases using angiograms as a diagnostic imaging. Surgical treatment was offered to the patients based on the existence of the CM anatomy coupled with the symptom of syncope or VBI as a possible cause through unusual clinical manifestation.<sup>16</sup>

Another recent case report discussed a 48-year-old woman who presented with symptoms of acute pain in her neck and repeated episodes of syncope preceded by sudden onset of dizziness. Imaging revealed caudal displacement of her right cerebellar tonsil through the foramen magnum, a C6-C7 syrinx and dilatation of the left vertebral artery. No abnormal vascular related MRI findings were observed in the brain stem. Surgery was offered to address the symptom complex. Intraoperatively, an aberrant and ectatic left PICA was held by a cuff of dural tissue to the inner aspect of dura, resulting in an acute angulation and strangulation of the vessel with impaired blood flow. Upon dissection of this dural cuff abnormality, the PICA was

released, the strangulation disappeared dramatically and the C1 nerve rootlet appeared to relax. The authors of this study reported a complete resolution of her symptoms of VBI after the surgery and a symptom-free chronology with 5 years of a documented follow up.

Among reported vascular related pathology around brain stem in Chiari I or 1.5 patients, caudal displacement of PICA, strangulation of PICA by dural cuff and our addition of a frank stenosis of the distal PICA appear to be the only findings documented.

For our patient, residual symptoms may be attributed to the chronic hypoxic environment in the field of the PICA distal to the recognized compression and may never be fully recovered. Our intraoperative findings along with scattered previous literature, suggest an uncommon benefit of an intradural exploration in assessing the vasculature in the compressed region. Awareness of additional abnormal pathology in Chiari patients might be a useful adjunct in explaining residual postoperative symptoms as well as evaluating additional treatment options. Given the excellent response that many patients have to standard decompression it is unlikely that vascular compromise is a widespread source of symptoms, however, the contribution of intermittent valsalva induced decrease in blood flow through the vertebrobasilar tree should not be discounted. Within the context of comorbid condition such as POTS disease subtle derangements in medullary blood flow could result in significant symptoms. In addition, complex and poorly explained symptoms within the context of Chiari such as perceived memory loss, mental “fog”, blurry vision and fatigue may be partially attributable to a contribution of decreased blood flow to the posterior fossa, medulla and vertebrobasilar complex. There may be a possible adjuvant role of vascular imaging in the form of MRA or CTA, in addition to a thorough inspection of the vascular anatomy in the posterior fossa during the intradural exploration. These additions to the Chiari workup and surgery might reveal relevant anatomy to explain the pathophysiology in a subset of challenging Chiari patients.

## CONCLUSIONS

Dizziness, ataxia, blurry vision and memory disturbance are not unusual symptoms encountered as part of the presenting symptom complex within Chiari I or 1.5 in adults. A meticulous dissection of the tonsilomedullary fissure not routinely considered in every case but, might provide useful information regarding vascular pathology in the absence of a definitive preoperative imaging. Evaluation of the posterior fossa vasculature using MR or CT angiography can be considered in this subset of Chiari patients. This additional imaging may reveal other congenitally aberrant and/or acquired vascular abnormalities, which could be considered as possible contributive pathology within the Chiari symptom complex.

## REFERENCES

1. Arnautovic A, Splavski B, Boop FA, Arnautovic KI. Pediatric and adult Chiari malformation Type I surgical series 1965-2013: a review of demographics, operative treatment, and outcomes. **J Neurosurg Pediatr** **15(2)**: 161-77,2015.
2. Anderson RC, Emerson RG, Dowling KC, Feldstein NA: Improvement in brainstem auditory evoked potentials after suboccipital decompression in patients with Chiari I malformations. **J Neurosurg** **98**: 459–464, 2003.
3. Milhorat TH, Chou MW, Trinidad EM, Kula RW, Mandell M, Wolpert C, et al: Chiari I malformation redefined: clinical and radiographic findings for 364 symptomatic patients. **Neurosurgery** **44**: 1005–1017,1999.
4. Pollack IF, Pang D, Kocoshis S, Putnam P: Neurogenic dysphagia resulting from Chiari malformations. **Neurosurgery** **30**: 709–719, 1992.
5. Nishikawa M, Sakamoto H, Hakuba A, Nakanishi N, Inoue Y: Pathogenesis of Chiari malformation: a morphometric study of the posterior cranial fossa. **J Neurosurg** **86**: 40-47, 1997.
6. Stevens JM, Serva WA, Kendall BE, Valentine AR, Ponsford JR: Chiari malformation in adults: relation of morphological aspects to clinical features and operative outcome. **J Neurol Neurosurg Psychiatry** **56**: 1072–1077, 1993.

7. Dobkin BH. Syncope in the adult Chiari anomaly. **Neurology** **28(7)**: 718-720, 1978.
8. Melamed I, Nash M, Merkin V, Cohen A, Azriel A, Brotfain E. Repeated Syncope in an Adult Chiari I Anomaly with an Aberrant PICA. A Case Report and Review of the Literature. **The Open Neurosurgery Journal** **7**: 1-3, 2015.
9. Kobayashi T, Ogawa A, Kameyama M, Uenohara H, Yoshimoto T. Chiari malformation with compression of the medulla oblongata by the vertebral arteries. Case report. **J Neurosurg** **77(2)**: 307-309, 1992.
10. Prilipko O, Dehdashti AR, Zaim S, Seeck M. Orthostatic intolerance and syncope associated with Chiari type I malformation. **J Neurol Neurosurg Psychiatry** **76(7)**:1034-1036, 2005.
11. Doss A, Phatouros CC. Vertebrobasilar insufficiency. **Curr Treat Options Cardiovasc Med** **8(2)**: 111-119, 2006.
12. Koçer A. Cognitive problems related to vertebrobasilar circulation. **Turk J Med Sci** **45(5)**: 993-977, 2015.
13. Dyste GN, Menezes AH, VanGilder JC. Symptomatic Chiari malformations: an analysis of presentation, management, and long term outcome. **J Neurosurg** **71**: 159-168, 1989.
14. Paul KS, Lye RH, Strang FA, Dutton J. Arnold-Chiari malformation: review of 71 cases. **J Neurosurg** **58**: 183-187, 1983.
15. Weig SG, Buckthal PE, Choi SK, Zellem RT. Recurrent syncope as the presenting symptom of Arnold-Chiari malformation. **Neurology** **41(10)**: 1673-1674, 1991.
16. Asari S, Yamanaka A, Namba S, Nishimoto A. Clinical study of late onset Chiari type I malformation. **No To Shinkei** **39(6)**: 497-503, 1987.

**ACKNOWLEDGEMENTS**

I. I. was supported by a Medical Scientist Training Program grant from the National Institute of General Medical Sciences of the National Institutes of Health under award number T32GM007739 to the Weill Cornell/Rockefeller/Sloan-Kettering Tri-Institutional MD- PhD Program. This study is solely the responsibility of the authors and does not necessarily represent the official views of the National Institutes of Health.

**Legends:****(Figure 1)**

Preoperative T2 sagittal MRI sequence demonstrating a Chiari 1.5 malformation with peg shaped, thinned cerebellar tonsils (bold black arrow cephalad), and expansile syringomyelia (bold black arrow caudad) in the cervical segment of the spinal cord.

**(Figure 2) A-D. Intraoperative pathologic findings**

A-B. An atretic tonsilomedullary segment of the right posterior inferior cerebellar artery (PICA) (bold black arrow) can be appreciated by mobilizing the right cerebellar tonsil (small black arrow).

C. Right sided tonsil (small black arrow) is lifted up to reveal normal ipsilateral vertebral artery (bold black arrow).

D. Right sided thinned cerebellar tonsil (small black arrow), and atrophic tonsillar tip (bold black arrow), consistent with chronic compressive etiology.

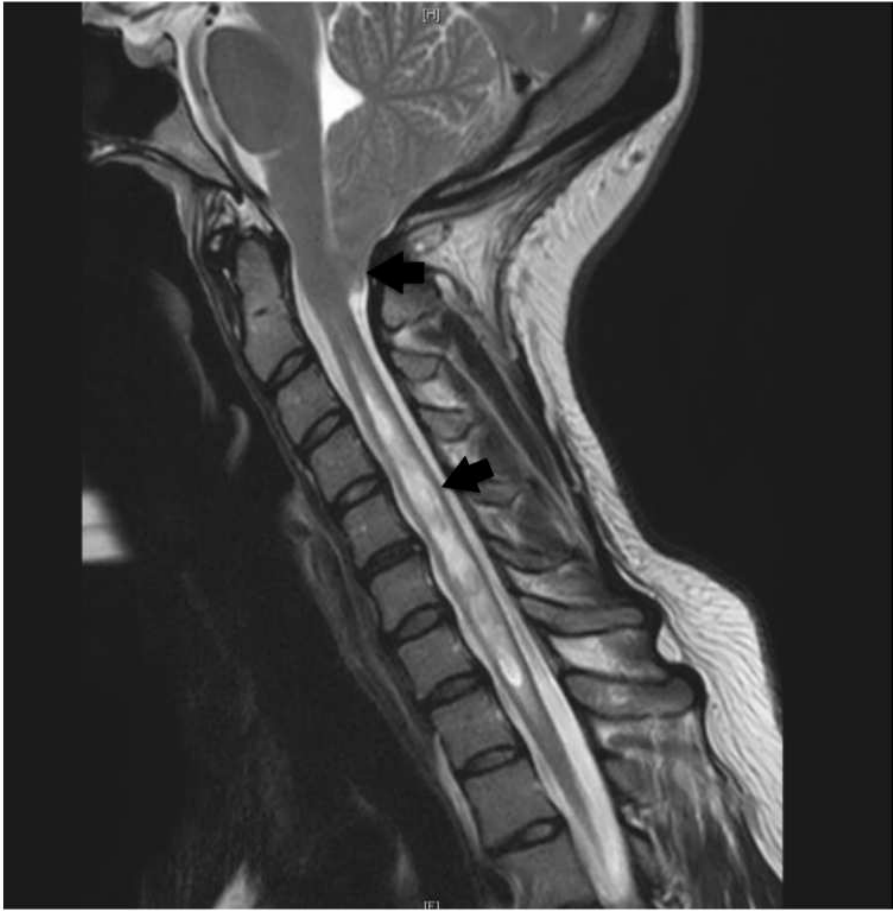**(Figure 3)**

Frontal TOF-MRA image of the posterior circulation reveals an absent right sided posterior inferior cerebellar artery (white arrow). MRA scan was obtained postoperatively.

**(Figure 4)**

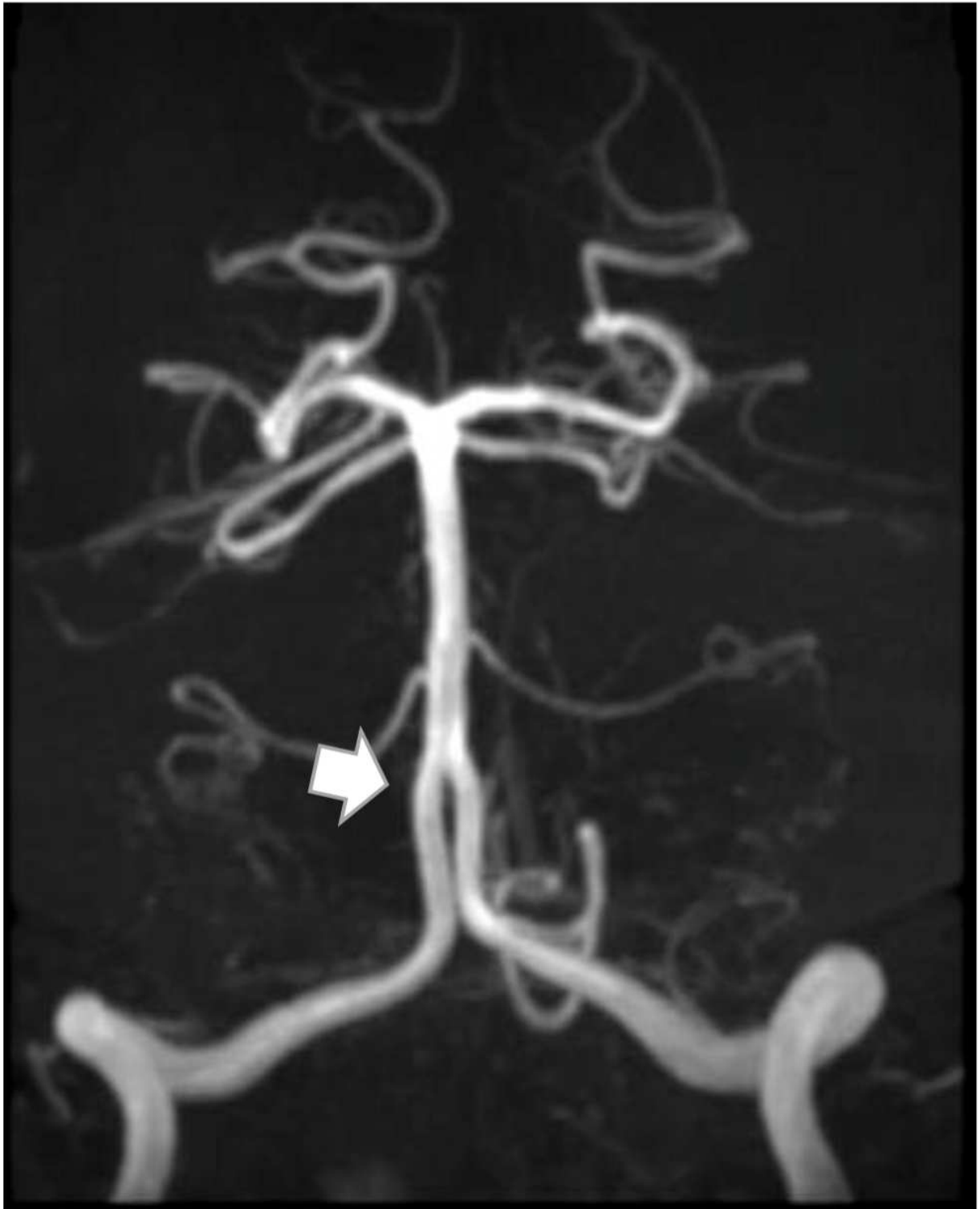A. 3 month postoperative T2 sagittal MRI sequence demonstrating flow voids around the foramen magnum with an ample retro-cerebellar subarachnoid space and interval collapse of the previously expansile syringomyelia.

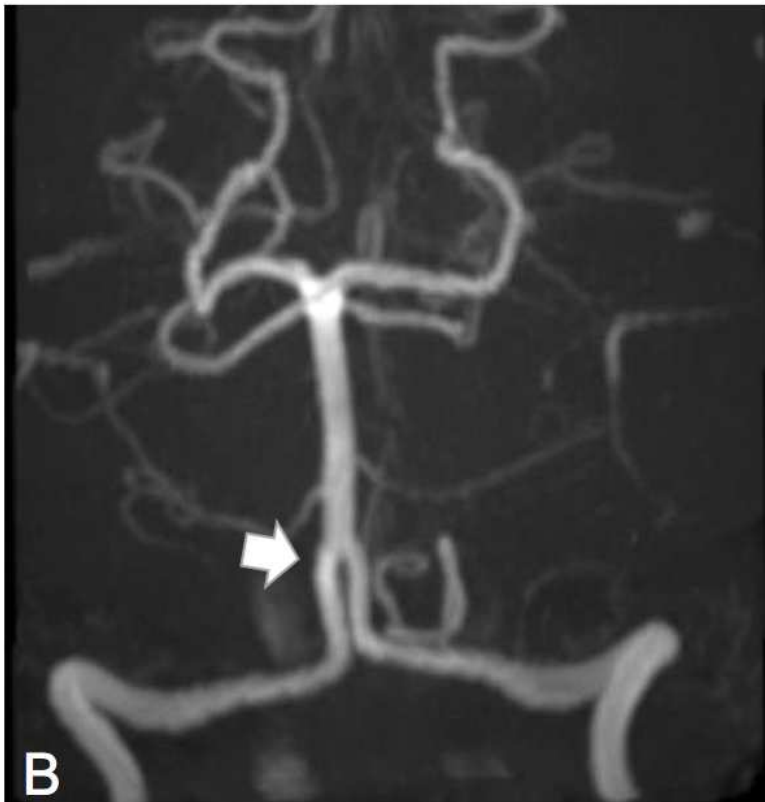
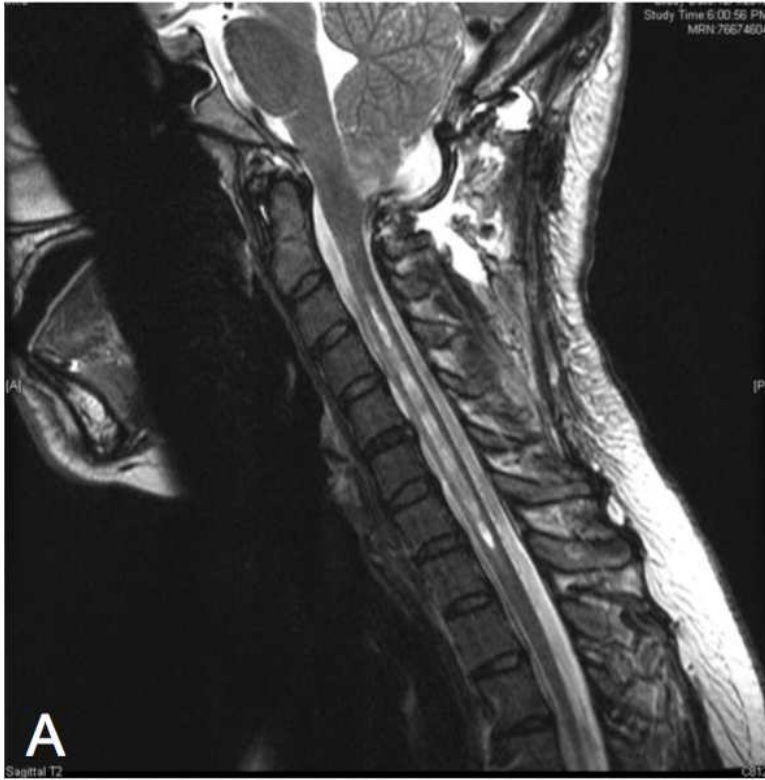
B. 3 months postoperative frontal TOF-MRA image revealing persistently occluded right sided PICA (white arrow) despite alleviation of external compression from the foramen magnum.

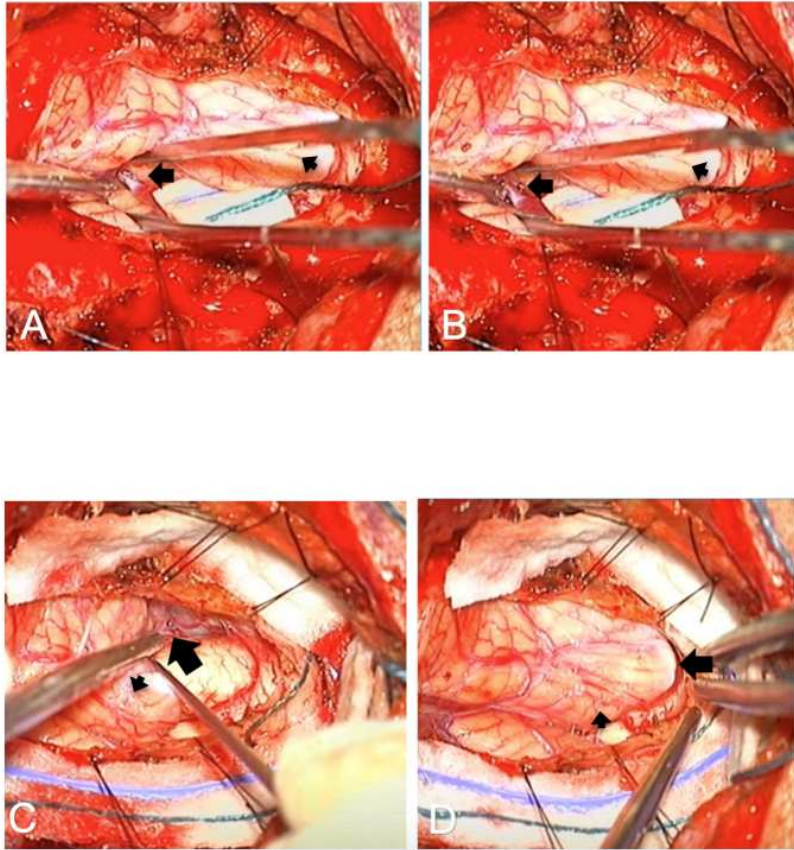


ACCEPTED









ACCEPTED TEL

Chiari malformation is thought to cause symptoms through compression of neural elements

During our subdural exploration, we found occlusion and displacement of the loop of the right PICA

Assessment of the posterior fossa vasculature may be useful in defining this subset of patients

Preoperative planning and exploration can reveal additional source of pathology for these patients

CM- Chiari Malformation  
CSF- Cerebrospinal Fluid  
CTA- Computerized Tomographic Angiography  
ICU- Intensive Care Unit  
MRA- Magnetic Resonance Angiography  
MRI- Magnetic Resonance Imaging  
PICA- Posterior Inferior Cerebellar Artery  
TIA- Transient Ischemic Attack  
VA- Vertebral Artery  
VBI- Vertebrobasilar Insufficiency

ACCEPTED MANUSCRIPT