

## Reversible Cerebral Vasoconstriction Syndrome Presenting with Transient Global Amnesia

Kenji Isahaya, Kensuke Shinohara, Masashi Akamatu, Takahiro Shimizu, Kenzo Sakurai,  
Makoto Shiraishi, Hisanao Akiyama and Yasuhiro Hasegawa

---

### Abstract

---

A 65-year-old man who had been diagnosed with transient global amnesia (TGA) 15 years previously was admitted to hospital with complaints of amnesia and headache. His symptoms improved on day-2. The initial brain MRI and electroencephalography findings were normal. He was diagnosed with a recurrence of TGA and discharged. However, he returned with right leg weakness and complained of a thunderclap headache. MRI demonstrated subarachnoid hemorrhage and multifocal segmental narrowing of the left posterior cerebral artery (PCA) and large intracranial arteries, and he was diagnosed with reversible cerebral vasoconstriction syndrome (RCVS). He was discharged on day-30 without any neurological deficits. This case suggested that TGA should be interpreted as one of the symptoms of RCVS or a prodromal symptom of RCVS.

**Key words:** reversible cerebral vasoconstriction syndrome, transient global amnesia, subarachnoid hemorrhage, thunderclap headache

(Intern Med 56: 1569-1573, 2017)

(DOI: 10.2169/internalmedicine.56.7460)

---

### Introduction

---

Reversible cerebral vasoconstriction syndrome (RCVS) is characterized by severe headache and reversible vasoconstriction of the cerebral arteries with or without cortical subarachnoid hemorrhage, infarction or intracerebral hemorrhage. Thunderclap headache, seizures and focal neurological deficits are commonly observed, but amnesia is rare. We herein report the case of a 65-year-old patient with a history of transient global amnesia (TGA) 15 years prior to his presentation, who was admitted with typical symptoms of TGA and who was subsequently diagnosed with RCVS - implying a causal relationship between RCVS and TGA.

---

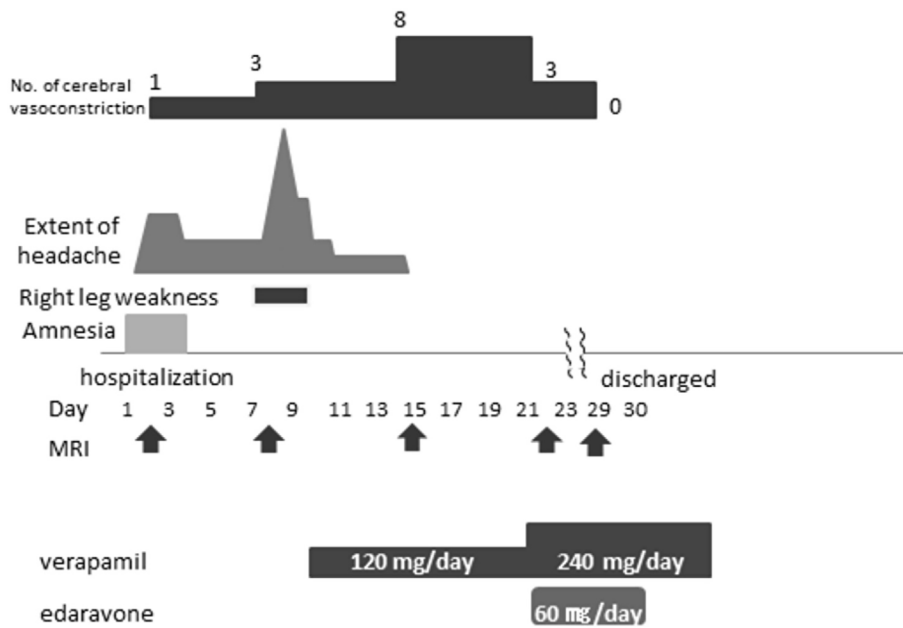
### Case Report

---

A 65-year-old man was admitted to our hospital with a complaint of amnesia. After returning home on the day of admission, he could not remember what he had done all day. He remained confused and kept asking repetitive questions. He had no seizure activity or palsy. Fifteen years prior

to his presentation he had experienced TGA. When he was 50 years of age, his wife noticed that his memory was severely disturbed: when she talked with him at home, he repeatedly asked the same questions. He was admitted to hospital by ambulance. His memory disturbance continued for approximately 12 hours and then completely normalized. He had not experienced any headache during the course of TGA and his MRI findings were normal. He was diagnosed with TGA. He was not a smoker, but had a history of hypertension and spinal stenosis. He had no history of surgery and no family history of neurological disease. Two weeks before the onset of symptoms, hydrochlorothiazide (4 mg), reserpine (0.1 mg), and carbazochrome (5 mg) were added to his medications.

A general physical examination revealed that his blood pressure was 161/84 mmHg, his heart rate was 68 beats per minute, and his temperature was 36.7°C. He was alert and oriented to person and place but not to time. He had anterograde amnesia; his cognitive impairment was limited to amnesia. He had no other neurological symptoms or signs. Laboratory investigations revealed a normal complete blood count and chemistry panel. Lumbar puncture was not per-



**Figure 1.** Clinical course. The patient complained of amnesia and headache on admission and subsequently a thunderclap headache on day 9. His headache disappeared on day 13, but a brain MRI on day 14 showed segmental vasoconstriction of the cerebral arteries. A brain MRI on day 21 showed new areas of infarction, and he was started on oral verapamil 240 mg/day and edaravone 60 mg/day. A brain MRI on day 29 showed resolution of the segmental vasoconstriction. He was discharged directly home on oral verapamil on day 30.

formed. An electrocardiogram demonstrated normal sinus rhythm. Magnetic resonance imaging (MRI) of the brain showed no acute findings, while magnetic resonance angiography (MRA) of the brain showed mild stenosis in the left posterior cerebral artery.

His clinical course is shown in Fig. 1. His Mini Mental State Examination (MMSE) score on day-1 was 27, the subtest scores were as follows: temporal orientation (5 points), spatial orientation (5 points), immediate memory (3 points), attention/concentration (5 points), delayed recall (no points), naming (2 points), verbal repetition (1 points), verbal comprehension (3 points), writing (1 points), reading a sentence (1 points), and constructional praxis (1 points). His amnesia began to improve on day-2 (MMSE total score; 30) and disappeared by day-4.

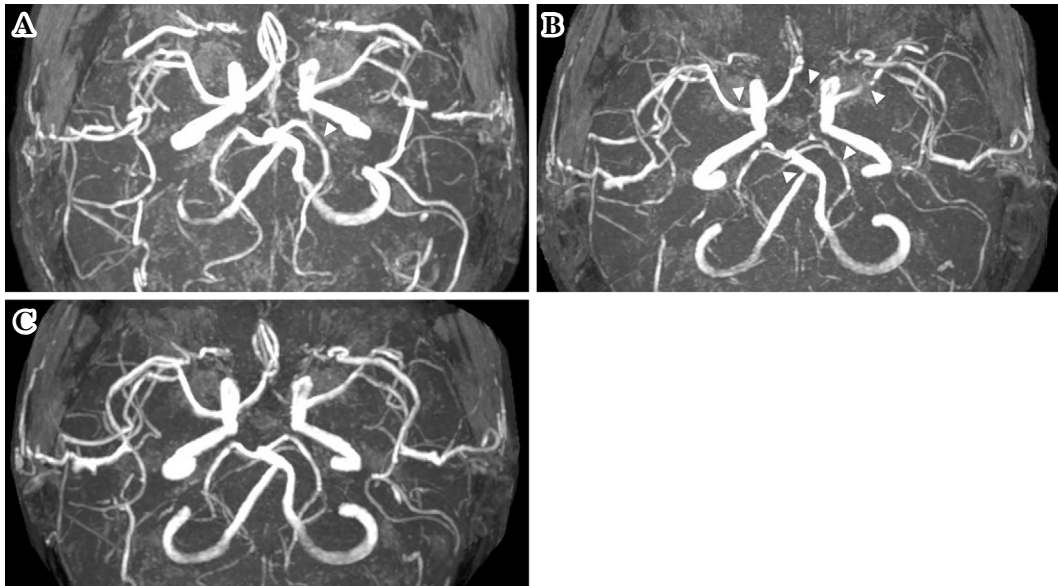
Because of his history of TGA, his amnesic episode was diagnosed as a recurrence of TGA according to the diagnostic criteria of Hodges and Warlow (1), and he was discharged from the hospital on day-7. However, he developed right leg weakness and returned to the hospital on the evening of the same day. In the emergency room, his NIH stroke scale score was 2. MRI and MRA were performed; however, he complained of a thunderclap headache in the gantry. We could complete almost entire protocol, and the MRI findings were normal. However MRA revealed multifocal segmental narrowing of the right vertebral artery (VA), bilateral posterior cerebral artery (PCA), bilateral middle cerebral artery (MCA) and left anterior cerebral artery (ACA) (Fig. 2A). Brain computed tomography (CT) scanning on day-9 demonstrated a subarachnoid hemorrhage

over the left frontal convexity (Fig. 3A) and CT angiography demonstrated no improvement of the segmental stenosis. He was diagnosed with RCVS and was started on oral verapamil (120 mg/day).

His right leg weakness improved and eventually disappeared. On day-15, his headache had disappeared; however, follow-up brain MRI showed new areas of ischemia in the left upper occipital region (Fig. 3B-D). MRA showed persistent multifocal irregular stenosis of the right VA, bilateral PCA, bilateral MCA and left ACA, which was consistent with vasoconstriction (Fig. 2B). He was started on oral verapamil (240 mg/day) and edaravone (60 mg/day). He did not experience any other neurological symptoms and made a full neurological recovery. On day-22, brain MRA showed the resolution of the segmental vasoconstriction (Fig. 2C). Brain MRI on day-29 showed no new areas of infarction and the resolution of the segmental vasoconstriction. On day-30, he was discharged directly to his home (NIH Stroke scale score, 0; modified Rankin scale score, 0) on oral verapamil.

## Discussion

The proposed diagnostic criteria for RCVS (2-4) are as follows: (a) acute and severe headache (often thunderclap) with or without focal deficits or seizures, (b) a uniphasic course without new symptoms for more than 1 month after the clinical onset, (c) segmental vasoconstriction of the cerebral arteries on indirect (e.g., MRI or CT) or direct catheter angiography, (d) no evidence of aneurysmal subarachnoid hemorrhage, (e) normal or near-normal CSF levels (protein



**Figure 2.** Brain magnetic resonance angiography. (A) Magnetic resonance angiography (MRA) of a 65-year-old man with reversible cerebral vasoconstriction syndrome on day 2 showing segmental constriction of the right posterior cerebral artery (PCA) (arrow head). (B) MRA showing segmental constriction of the right vertebral artery (VA), bilateral PCA, bilateral middle cerebral artery (MCA) and left anterior cerebral artery (ACA) (arrow heads) on day 15. (C) MRA showing resolution of the segmental vasoconstriction on day 22.

concentration <100 mg/dL, <15 white blood cells per  $\mu$ L), and (f) the complete or substantial normalization of arteries shown by follow-up indirect or direct angiography within 12 weeks of the clinical onset. This case was diagnosed according to the above-mentioned criteria. The patient in the present case satisfied criteria (a), (b), (c) and (f), and was therefore diagnosed with RCVS.

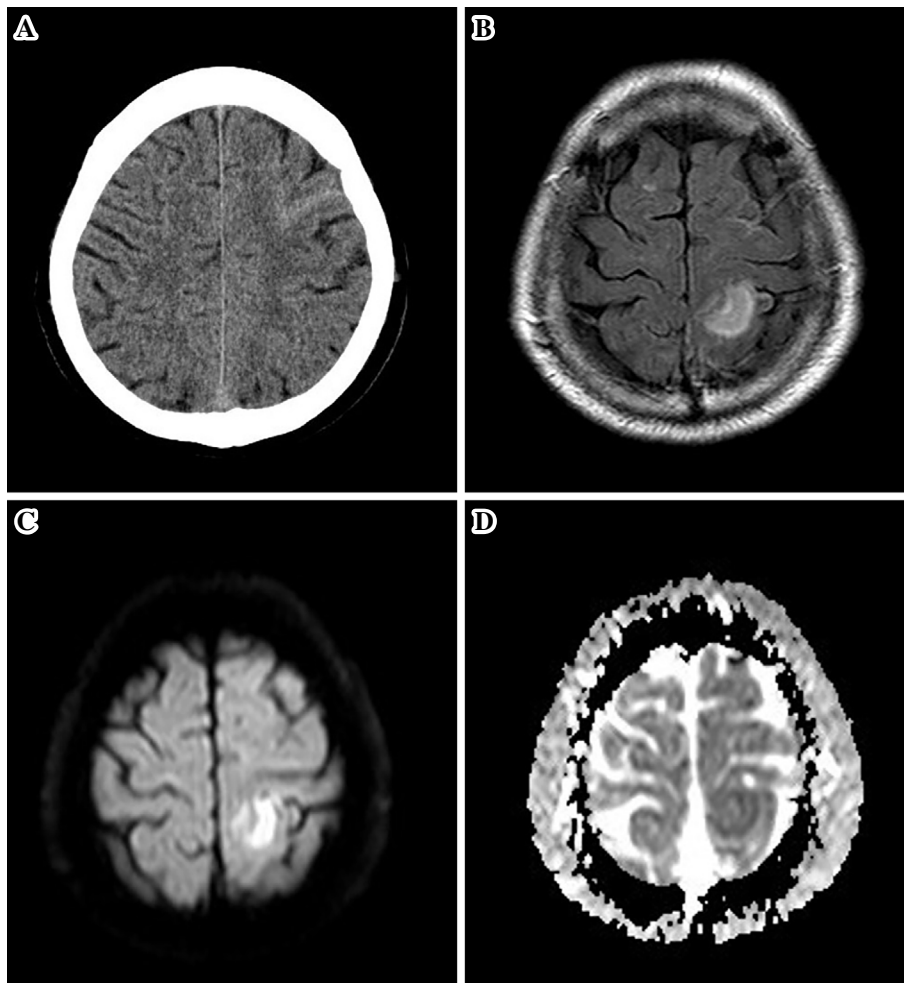
Headache is the main symptom of RCVS. Thunderclap headache is reported in 85% of RCVS cases. Recurrent thunderclap headache is reported in 82% of cases of RCVS and occurs at 3-12 days after the onset of the initial thunderclap headache (5). In this case, the patient presented with headache on admission, while thunderclap headache developed on day-8.

Subarachnoid hemorrhage (SAH), cerebral hemorrhage, seizures and posterior reversible encephalopathy syndrome (PRES) are reported in 22%, 6%, 3% and 9% of patients, respectively, during the acute phase of RCVS ( $\leq$ 1 week after onset). Transient ischemic attack (TIA) and cerebral infarction are reported in 16% and 4% of patients, respectively, during the late phase (>1 week after onset) (6). In the present case, SAH occurred on day-7 and cerebral infarction occurred on day-15. The entire clinical course of the present case is consistent with RCVS.

Several mechanisms of TGA have been proposed. These include vascular (venous congestion or arterial ischemia), epileptic, or migraine related mechanisms. The venous congestion theory may be supported by the DWI abnormalities in the hippocampus that are observed in TGA patients with internal jugular vein valve incompetence (7-10). Arterial vasoconstriction, which might cause TGA, is usually pre-

cipitated by emotional stress or the Valsalva maneuver (11, 12). A case of Takotsubo cardiomyopathy with TGA, in which both coronary and cerebral arterial vasoconstriction were suggested, has also been reported (13). However, no signs of intracranial arterial vasoconstriction were demonstrated in a case-control study using transcranial arterial echo-color Doppler sonography (14). Although RCVS is one of the forms of arterial vasoconstriction, the relationship between TGA and vasoconstriction has been a matter of speculation. This case is clinically important because the patient had a history of TGA and because typical symptoms of TGA were observed during his initial presentation during the development of RCVS. Although persistent neurological deficits such as hemiplegia, aphasia, hemianopia and cortical blindness have been reported in patients with RCVS (4), there have been no reports of amnesia. This case suggested that TGA should be interpreted as one of the symptoms of RCVS or a prodromal symptom of RCVS.

Several causes of RCVS have been reported, including postpartum, hypercalcemia, porphyria, cerebral venous thrombosis, vasoactive drugs (serotonergic and adrenergic drugs, cannabis, cocaine, ergot alkaloid derivatives and triptans) (4), and herbal medicines containing ginseng and ephedra (15). A combination tablet (hydrochlorothiazide, reserpine, and carbazochrome) had been prescribed to the present patient two weeks before his admission. Although these substances have not been reported as precipitants of RCVS, reserpine has been known to cause amnesia (16). Thus, we stopped the administration of the combination tablet after admission. Although severe headache-induced delirium and/or drug-induced consciousness disturbance (e.g., hydrochlo-



**Figure 3.** Computed tomography (CT) on day 9 and magnetic resonance imaging (MRI) on day 21. (A) On day 9, CT showing left frontal subarachnoid hemorrhage. (B) On day 21, Fluid Attenuated Inversion Recovery (FLAIR), (C) diffusion-weighted MRI, and (D) apparent diffusion coefficient maps revealed lesions in the left parietal lobe consistent with infarction.

rothiazide, reserpine) can cause amnesia-like symptoms, his consciousness - as evaluated by awareness and responsiveness - was normal throughout the period of amnesia, implying that it was quite unlikely that the patient's amnesia-like symptoms were associated with consciousness disturbance.

The hippocampal body is perfused by the anterior hippocampal artery and the middle hippocampal artery and the posterior hippocampal artery branches from the proximal portion of the PCA. The hippocampal head is perfused by the anterior choroidal artery (AChA), which is supplied by the internal carotid artery (ICA). Amnesia may be associated with infarctions of the PCA and AChA (17). It has been suggested that the vasoconstriction of the cerebral arteries in RCVS progresses from the distal portion of the arteries to the more proximal arteries, such as the branches of the circle of Willis (6). When our patient's amnesic symptoms occurred, the proximal portion of his left PCA showed stenosis on MRA, suggesting that transient ischemia in the hippocampal artery territory might have resulted in the symptoms of transient amnesia. Unfortunately, we did not have the chance to perform brain SPECT imaging to demonstrate

cerebral blood flow abnormalities in the PCA area, because his amnesia resolved within a few days. Furthermore, we did not perform serial CT angiography to demonstrate the time-course of the resolution of vasoconstriction, because the use of contrast material for conventional cerebral angiography or CT angiography is known to be a risk factor for RCVS (18). Although calcium antagonists do not affect the period of cerebral vasospasm, they have been used to relieve arterial narrowing (6, 15, 18). In the present case, oral verapamil (120 mg/day) was found to be effective in relieving the patient's vasoconstriction.

To the best of our knowledge, this is the first case suggesting a causal relationship between TGA and RCVS. TGA could be a prodromal symptom of RCVS. Although RCVS is relatively uncommon, it should be considered in the differential diagnosis of patients presenting with TGA.

**The authors state that they have no Conflict of Interest (COI).**

## References

1. Hodges JR, Warlow CP. Syndromes of transient amnesia: towards a classification. A study of 153 cases. *J Neurol Neurosurg Psychiatry* **53**: 834-843, 1990.
2. Headache Classification Subcommittee of the International Headache Society. The international classification of headache disorders. *Cephalalgia* **24** Suppl 1: 1-160, 2004.
3. Calabrese LH, Dodick DW, Schwedt TJ, Singhal AB. Narrative review: reversible cerebral vasoconstriction syndromes. *Ann Intern Med* **146**: 34-44, 2007.
4. Ducros A. Reversible cerebral vasoconstriction syndrome. *Lancet Neurol* **11**: 906-917, 2012.
5. Chen SP, Fuh JL, Lirng JF, Chang FC, Wang SJ. Recurrent primary thunderclap headache and benign CNS angiopathy: spectra of the same disorder? *Neurology* **67**: 2164-2169, 2006.
6. Ducros A, Boukobza M, Porcher R, Sarov M, Valade D, Bousser MG. The clinical and radiological spectrum of reversible cerebral vasoconstriction syndrome. A prospective series of 67 patients. *Brain* **130**: 3091-3101, 2007.
7. Cejas C, Cisneros LF, Lagos R, Zuk C, Ameriso SF. Internal jugular vein valve incompetence is highly prevalent in transient global amnesia. *Stroke* **41**: 67-71, 2010.
8. Yang Y, Kim S, Kim JH. Ischemic evidence of transient global amnesia: location of the lesion in the hippocampus. *J Clin Neurol* **4**: 59-66, 2008.
9. Schreiber SJ, Doepp F, Klingebiel R, Valdueza JM. Internal jugular vein valve incompetence and intracranial venous anatomy in transient global amnesia. *J Neurol Neurosurg Psychiatry* **76**: 509-513, 2005.
10. Nedelmann M, Eicke BM, Dieterich M. Increased incidence of jugular valve insufficiency in patients with transient global amnesia. *J Neurol* **252**: 1482-1486, 2005.
11. Kaida T, Nakano H, Watanabe I, et al. A unique case of Takotsubo cardiomyopathy with transient global amnesia which might be caused by simultaneous and multiple vasospasms. *J Cardiac Failure* **15** Suppl: S159, 2009.
12. Caplan LR. Transient global amnesia and jugular vein incompetence. *Stroke* **41**: e568, 2010.
13. Pantoni L, Lamassa M, Inzitari D. Transient global amnesia: a review emphasizing pathogenic aspects. *Acta Neurol Scand* **102**: 275-283, 2000.
14. Baracchini C, Farina F, Ballotta E, Meneghetti G, Manara R. No signs of intracranial arterial vasoconstriction in transient global amnesia. *J Neuroimaging* **25**: 92-96, 2014.
15. Ichiki M, Watanabe O, Okamoto Y, Ikeda K, Takashima H, Arimura K. A case of reversible cerebral vasoconstriction syndrome (RCVS) triggered by a Chinese herbal medicine. *Rinsho Shinkeigaku (Clin Neurol)* **48**: 267-270, 2008 (in Japanese).
16. Alves CS, Andreatini R, da Cunha C, Tufik S, Vital MA. Phosphatidylserine reverses reserpine-induced amnesia. *Eur J Pharmacol* **404**: 161-167, 2000.
17. Ott BR, Saver JL. Unilateral amnesic stroke. Six new cases and a review of the literature. *Stroke* **24**: 1033-1042, 1993.
18. Chen SP, Fuh JL, Wang SJ, et al. Magnetic resonance angiography in reversible cerebral vasoconstriction syndromes. *Ann Neurol* **67**: 648-656, 2010.

The Internal Medicine is an Open Access article distributed under the Creative Commons Attribution-NonCommercial-NoDerivatives 4.0 International License. To view the details of this license, please visit (<https://creativecommons.org/licenses/by-nc-nd/4.0/>).