

## CASE REPORT

## Internal carotid artery occlusion and stroke as a complication of cisplatin-based chemotherapy for metastatic testicular germ cell tumour

Roberto Christian Cerrud-Rodriguez, Maria Gabriela Quinteros, Mohammed Azam

SBH Health System, Internal Medicine, Bronx, New York, USA

**Correspondence to**

Dr Roberto Christian Cerrud-Rodriguez, robertocerrud@gmail.com

Accepted 2 June 2017

**SUMMARY**

Testicular tumours are the most common tumours in young men. Germ cell tumours (GCTs) account for 95% of all testicular cancers, and the non-seminomatous type (NSGCT) accounts for 50% of all GCTs. Cisplatin-based chemotherapy is curative in up to 90% of patients, but it is not without its inherent risks. Ischaemic stroke is a very uncommon, but severe complication of cisplatin-based chemotherapy. Strokes in young patients cause a disproportionately large economic impact by leaving victims disabled during their most productive years and strains the healthcare system with expensive hospital stays. We present a case of a young male patient with past medical history of metastatic NSGCT with the sudden onset of dysarthria, left hemiplegia and ipsilateral hemisensory loss 3 days after receiving cisplatin-based chemotherapy. Subsequent studies revealed a stroke involving the right middle cerebral artery territory secondary to an acute right internal carotid occlusion.

**BACKGROUND**

Testicular tumours are the most common solid tumours in men between ages 15 years and 35 years, and they account for 1% of all cancers in men. Germ cell tumours (GCTs) account for 95% of all testicular cancers and the non-seminomatous type (NSGCT) account for approximately 50% of all GCTs. Chemotherapy based on cisplatin, etoposide and bleomycin is curative in up to 90% of patients with NSGCT.<sup>1 2</sup>

The incidence of arterial thromboembolic events in patients undergoing therapy with cisplatin ranges between 0.3% and 1.6%. Ischaemic cerebrovascular accidents (CVAs) associated to cisplatin-based chemotherapy are thus very infrequent events, with a strong temporal association between the administration of cisplatin and the CVA—most occur within 10 days of administration, after a median number of three cycles of chemotherapy—which might suggest a causative relationship between the two.<sup>2–4</sup>

Stroke is not a common occurrence in the young, which are usually defined as the population below 45–49 years of age. Stroke in this patient population has a disproportionately large economic impact by leaving victims disabled during their most productive years. In addition, the estimated average cost of a hospital stay for a young patient with ischaemic stroke is US\$34 886.<sup>5</sup>

We believe our case is relevant because it highlights the importance of educating our patients about potentially catastrophic adverse reactions to treatment options that might be life-saving, even if the said adverse reactions are extremely uncommon—thus adhering to the basic ethical principles of medicine. Our case also highlights the financial burden that stroke in the young represents for the patient, as well as for the healthcare system in general.

**CASE PRESENTATION**

A 36-year-old man presents to the emergency department with a 30-min history of sudden onset of left hemiparesis, left facial droop, dysarthria as well as ipsilateral decreased sensation. The patient was at home when he suddenly fell to the ground while walking towards the bathroom. His wife, who accompanied him to the hospital, reported that after hearing him fall to the ground, she ran and found the patient lying on the floor, profusely diaphoretic, but responsive and alert.

On physical examination, he was alert and oriented to self, place and time. The patient was found with dysarthric speech, left hemiplegia and ipsilateral hemihypoesthesia; in addition to these symptoms, the patient also had anosognosia without asomatognosia.

Blood pressure was normal. National Institute of Health Stroke Score (NIHSS) was 11.

Given these findings, a clinical diagnosis of stroke was formulated. CT of the brain without contrast was obtained and intracranial bleeding was excluded.

Thrombolysis was then given within the time frame defined by the American Heart Association/American Stroke Association, without improvement of the patient's symptoms. Neurosurgical thrombectomy was offered to the patient, but he declined the intervention.

Our patient was a former smoker with a 20 pack/year history, and his past medical history was remarkable for a left testicular NSGCT diagnosed 2 years before presenting to our hospital with stroke. He quit smoking when he was first diagnosed with cancer and was initially treated with a left orchiectomy. He also denied any illegal drug use.

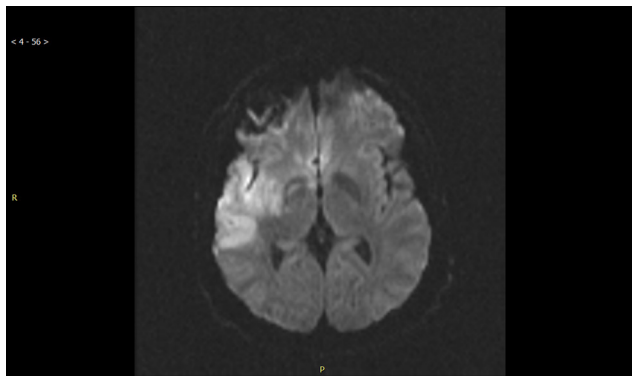
The patient was being followed up with serial CT scans of the abdomen and pelvis, and new-onset metastatic retroperitoneal lymphadenopathy was



CrossMark

**To cite:**

Cerrud-Rodriguez RC, Quinteros MG, Azam M. *BMJ Case Rep* Published Online First: [please include Day Month Year]. doi:10.1136/bcr-2017-220084



**Figure 1** A high signal on diffusion weighted imaging in the right middle cerebral artery distribution compatible with acute to subacute infarct.

found 4 months before the stroke. Chemotherapy with etoposide and cisplatin was started when the metastases were discovered.

He received a total of three cycles of chemotherapy, the last one 3 days before the development of his acute neurological findings. The review of systems were negative with the exception of the patient endorsing mild bilateral blurry vision, which had been present since his last chemotherapy session.

Family history was negative for stroke, connective tissue disorder, coagulopathy.

**INVESTIGATIONS**

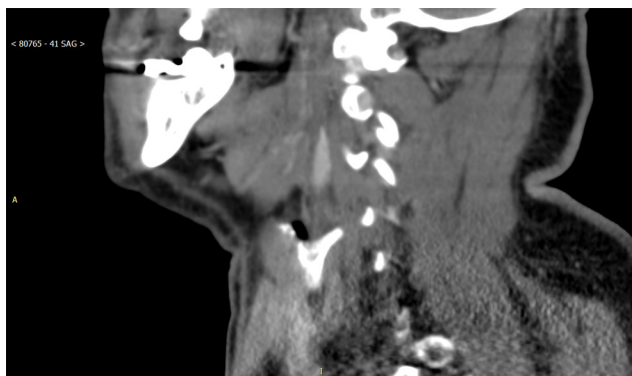
Serum studies on admission revealed hypomagnesaemia, normal coagulation and lipid profile.

MRI of the brain revealed an acute to subacute infarct in the right middle cerebral artery distribution (figure 1).

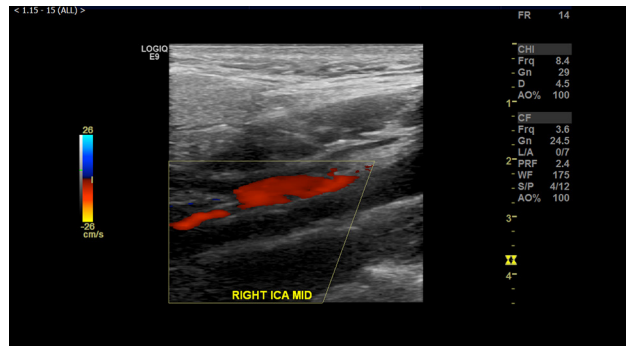
Duplex sonogram of the carotids was suggestive of right internal carotid artery occlusion (figure 2). CT angiogram of the neck was subsequently performed, showing a complete occlusion of the right internal carotid artery (figure 3). The left carotid system showed no evidence of atherosclerotic disease in either study.

Hypercoagulable workup was obtained: serum homocysteine level was normal; anticardiolipin antibodies, prothrombin gene mutation, factor V mutation, methylenetetrahydrofolate reductase mutation, lupus anticoagulant and dilute Russell's viper venom time test were all negative.

Transoesophageal echocardiogram and Holter monitoring results were unremarkable.



**Figure 2** A sagittal CT angiogram image demonstrates abrupt occlusion of the right internal carotid artery.



**Figure 3** Loss of colour Doppler flow signal at the right internal carotid artery (ICA). The colour Doppler flow signal seen in the adjacent right external carotid artery.

**DIFFERENTIAL DIAGNOSIS**

Cerebrovascular disease in the young is not a common occurrence.<sup>5</sup> Our patient had none of the classical risk factors for stroke, with no history of hypertension, diabetes or dyslipidaemia. There was also neither personal nor familial history of connective tissue disorders.

He also had no history of heart disease. Structural heart abnormalities that could have precipitated a cardioembolic stroke, including a patent foramen ovale, were ruled out with the normal transoesophageal echocardiogram. Normal Holter monitoring ruled out paroxysmal atrial fibrillation as the aetiology for stroke in our patient.

Coagulopathy, which itself is a rare cause of stroke in young adults,<sup>5</sup> was ruled out in our patient. He had neither personal nor familial history of sickle cell disease nor any other haemoglobinopathy which could explain his stroke. His complete blood count on admission was unremarkable, ruling out polycythaemia.

Thus, we conclude that the only risk factor present in our patient was having received cisplatin-based chemotherapy 3 days before his ischaemic stroke, this being his third cycle of chemotherapy, which correlates well with what has been described in the literature.

**TREATMENT**

After his admission, the patient was managed with daily aspirin. Statins were not used as their benefit in patients with stroke unrelated to atherosclerotic disease is controversial. Vascular surgery was consulted, but deemed the patient not to be a surgical candidate.

**OUTCOME AND FOLLOW-UP**

The patient was discharged to short-term rehabilitation facility after a 10-day hospitalisation. Speech had improved, with no residual dysarthria, and he had recovered some motor strength in his left lower limb.

He was re-evaluated 3 months later and had completely recovered motor strength in his left lower extremity, thus regaining the ability to ambulate. He had persistent severe residual weakness in his left upper limb. NIHSS at the time of re-evaluation was 5.

**DISCUSSION**

Few other cases of CVAs in young male patients affected by NSGCT after cisplatin-based chemotherapy have been reported.<sup>1-3</sup> To the best of our knowledge, besides our case

report, only two reports of a cisplatin-related internal carotid occlusion have been reported in the past, with one of them being caused by an internal carotid dissection.<sup>4 6</sup>

Our patient developed a right internal carotid occlusion with subsequent right middle cerebral artery stroke 3 days after receiving his third cycle of cisplatin-based chemotherapy, which fits in the usual time frame for symptom presentation established in the literature.<sup>4 7</sup>

The exact mechanism by which this cerebrovascular toxicity occurs is still up to debate—in general, chemotherapy active against NSGCTs has been associated to increased platelet aggregation, increased serum levels of von Willebrand factor, as well as direct endothelial lesion. Cisplatin, in particular, has been associated to an increased  $\alpha$ -adrenergic tone, as well as a state of hypomagnesaemia, which by itself increases the sensitivity of the vascular endothelium to contracting agents.<sup>2 3 8</sup> Of note, our patient was found to have low serum magnesium on presentation, which required aggressive intravenous correction with magnesium sulfate.

There is still no consensus on what the appropriate preventive strategy for patients receiving cisplatin-based chemotherapy should be to prevent stroke. It is thus especially important to develop a protocol to regularly monitor serum magnesium levels in these, correcting any derangement as soon as it is detected. In addition, we find ourselves in agreement with the authors who advocate the prophylactic use of low molecular weight heparin as an anticoagulating agent and aspirin for its antiplatelet action

during each cycle of cisplatin-based chemotherapy to try to reduce the risk of stroke, although this will require additional studies to prove its efficacy.<sup>3</sup>

Even though a stroke in the young can have catastrophic psychological, medical and financial consequences, it is fortunate that the long-term functional prognosis is usually good, with most patients returning to their neurological baseline or suffering minimal disability. The caveat is that long-term mortality in this population is increased even 20 years after the event when compared with the general population.<sup>1 2 5 9</sup>

**Contributors** RCC-R, as first author, was in charge of performing the chart review, obtaining consent from the patient, and doing the initial literature review on the topic. He was also responsible for writing the drafts for the case report, and making any modifications required by the Institutional Review Board or the supervising attending physician. MGQ, as second author, was in charge of additional literature review, on obtaining additional sources for past medical records of the patient that could be relevant to our case report, and of obtaining authorisation from the radiology department to use the images presented in this case report. MA, as third author and attending physician, was in charge of the overall execution of the case report, verifying that all steps required by our Institutional Review Board were fulfilled, as well as proofreading of the initial versions of the manuscript and approving the final version of the submitted manuscript.

**Competing interests** None declared.

**Patient consent** Obtained.

**Provenance and peer review** Not commissioned; externally peer reviewed.

© BMJ Publishing Group Ltd (unless otherwise stated in the text of the article) 2017. All rights reserved. No commercial use is permitted unless otherwise expressly granted.

### Learning points

- ▶ Although cisplatin-based chemotherapy can be curative in patients with non-seminomatous germ cell testicular tumours, there is a small, but real, risk of major stroke—and patients need to be properly educated about this risk.
- ▶ Other, more common causes, of cerebrovascular disease in young adults should be ruled out first, making this a diagnosis of exclusion.
- ▶ Stroke in young patients can be catastrophic given the disproportionately large economic impact by leaving victims disabled during their most productive years.
- ▶ We hope to increase awareness of this adverse effect and inspire research institutions to help devise protocols to reduce the risk of stroke in patients receiving cisplatin-based therapy.

### REFERENCES

- 1 Meattini I, Scotti V, Pescini F, *et al*. Ischemic stroke during cisplatin-based chemotherapy for testicular germ cell tumor: case report and review of the literature. *J Chemother* 2010;22:134–6.
- 2 Martinez BA, Correa EP. Unusually located Stroke after Chemotherapy in testicular germ cell tumors. *J Investig Med High Impact Case Rep* 2015;3.
- 3 Santos AJ, Malheiros SMF, Borges LRR, *et al*. Acidente vascular cerebral isquêmico após quimioterapia com cisplatina, etoposide e bleomicina: relato de caso. *Arq Neuropsiquiatr* 2003;61:129–33.
- 4 Khadjooi K, Adab N, Kenton A. Acute stroke secondary to carotid artery dissection in a patient with germ cell tumour: did cisplatin play a role? *Onkologie* 2013;36:46–8.
- 5 Smajlović D. Strokes in young adults: epidemiology and prevention. *Vasc Health Risk Manag* 2015;11:157–64.
- 6 Etgen T, Weidenhöfer G, Kubin T. Cisplatin-associated occlusion of the internal carotid artery. *Onkologie* 2009;32:754–7.
- 7 Li SH, Chen WH, Tang Y, *et al*. Incidence of ischemic stroke post-chemotherapy: a retrospective review of 10,963 patients. *Clin Neurol Neurosurg* 2006;108:150–6.
- 8 Vogelzang NJ, Torkelson JL, Kennedy BJ, Hypomagnesemia KB. Hypomagnesemia, renal dysfunction, and Raynaud's phenomenon in patients treated with cisplatin, vinblastine, and bleomycin. *Cancer* 1985;56:2765–70.
- 9 Rutten-Jacobs LC, Arntz RM, Maaijwee NA, Schoonderwaldt H, *et al*. Long-term mortality after stroke among adults aged 18 to 50 years. *JAMA* 2013;309:1136–44.

Copyright 2017 BMJ Publishing Group. All rights reserved. For permission to reuse any of this content visit <http://group.bmj.com/group/rights-licensing/permissions>.  
BMJ Case Report Fellows may re-use this article for personal use and teaching without any further permission.

Become a Fellow of BMJ Case Reports today and you can:

- ▶ Submit as many cases as you like
- ▶ Enjoy fast sympathetic peer review and rapid publication of accepted articles
- ▶ Access all the published articles
- ▶ Re-use any of the published material for personal use and teaching without further permission

For information on Institutional Fellowships contact [consortiasales@bmjgroup.com](mailto:consortiasales@bmjgroup.com)

Visit [casereports.bmj.com](http://casereports.bmj.com) for more articles like this and to become a Fellow