

# Severe Postpartum Headache and Hypertension Caused by Reversible Cerebral Vasoconstriction Syndrome: A Case Report

Ed McIlroy, MBBS, MRes, FRCA,\* Rajamani Sethuraman, MD, FRCA,\*  
Reshma Woograsingh, MBBS, BSc, FRCA,\* Catherine Nelson-Piercy, MBBS, MA, FRCP, FRCOG, †‡  
and Edward Gilbert-Kawai, PhD, MBBS, FRCA, DRCOG\*

Reversible cerebrovascular vasoconstriction syndrome is an uncommon condition that presents as severe headache and hypertension. Recent literature suggests a 1% incidence in postpartum headache cases. It can cause subarachnoid hemorrhages, cerebral ischemia, and seizures. It is often misdiagnosed as postdural puncture headache or preeclampsia. In this case, a postpartum woman, who had received epidural anesthesia for labor, presented 5 days postpartum with severe headache that did not resolve with an epidural blood patch. She then became more hypertensive and suffered a grand mal seizure. When treatment for eclampsia failed to resolve her symptoms, magnetic resonance angiography was performed. It demonstrated the pathognomonic signs of reversible cerebrovascular vasoconstriction syndrome. Her symptoms resolved with nimodipine. (A&A Case Reports. 2017;XXX:00–00.)

Reversible cerebral vasoconstriction syndrome (RCVS) presents with severe headache, that may be described as “thunderclap,” and there may be associated hypertension due to autoregulatory mechanisms to maintain cerebral perfusion. Patients may also present with seizures and focal neurological deficits. The average age of presentation is 42 years, with an 81% female propensity.<sup>1–3</sup> A recently published prospective study suggests that the postpartum incidence of RCVS could be as much as 1% of headache presentations and 3.8% of headache presentations require RCVS exclusion.<sup>4</sup> Untreated, RCVS spontaneously resolves within 1 to 3 months,<sup>2</sup> but RCVS necessitates diagnosis and treatment as 81% of sufferers develop brain lesions—infarcts (39%), convexity subarachnoid hemorrhage (34%), lobar hemorrhage (20%), and brain edema (38%).<sup>3</sup> Imaging, by means of magnetic resonance angiography (MRA), reveals the pathognomonic “string of beads” appearance of vasoconstriction.<sup>2,3</sup>

We present the case of a postpartum woman who received treatment for postdural puncture headache (PDPH) and eclampsia, despite negative preeclampsia toxemia (PET) blood studies and urinalysis, until finally having RCVS confirmed with MRA.

Written consent was obtained from the patient for publication of the case report.

## CASE DESCRIPTION

A 39-year-old primigravida was admitted at 40 weeks gestation in early labor with nausea and vomiting. She received intravenous (IV) hydration with 2 L of Hartmann’s solution over 10 hours. Labor was augmented with an oxytocin infusion. Antibiotics were administered in light of meconium-stained liquor and prolonged rupture of membranes, and epidural infusion (0.1% bupivacaine with fentanyl 2 mcg/mL) had been sited uneventfully for labor analgesia. Eighteen hours postinduction, the patient delivered vaginally with the aid of a kiwi device. Forty-eight hours later, she was discharged. Before this pregnancy, the patient’s medical history was significant only for minor migrainous headaches.

Five days postpartum, the patient awakened in the night with a severe occipito-temporal headache associated with neck stiffness and nausea. Mobilization and standing worsened the symptoms, but there was no photophobia, tinnitus, visual disturbance, or signs of sepsis. She telephoned the on-call anesthetist. The severity and postural component of the headache led to an admission for further assessment. Her neurological examination was normal; however, her blood pressure was 160/90 mm Hg and heart rate was 126 bpm. Blood results and urinary dip-stix were normal. In light of her history, and the supposition that her cardiovascular parameters were secondary to pain, an epidural blood patch was performed for presumed PDPH. There was no resolution of symptoms and her blood pressure increased to 180/101 mm Hg. Two hours later, the patient had a grand mal seizure. With a presumed diagnosis of eclampsia, magnesium sulphate (MgSO<sub>4</sub>) 4 g was administered IV, followed by IV infusions of MgSO<sub>4</sub> (1 g/h) and labetalol (10–20 mg/h). Her postseizure neurological exam was normal and blood pressure was 124/67 mm Hg. Computerized tomography (CT) of the head was reported as “normal brain parenchyma with no bleed or space occupying lesions.” For 24 hours, the patient remained asymptomatic during the MgSO<sub>4</sub> and labetalol infusions and repeat PET blood studies

From the \*Princess Alexandra Hospital NHS Trust, Harlow, United Kingdom; †Women’s Health Academic Centre, King’s Health Partners Directorate Office, London, United Kingdom; and ‡North Wing, St Thomas’ Hospital, London, United Kingdom.

Accepted for publication May 16, 2017.

Funding: None.

The authors declare no conflicts of interest.

Address correspondence to Ed McIlroy, MBBS, MRes, FRCA, 21 Hervey Park Road, London E17 6LJ, United Kingdom. Address e-mail to edward.mcilroy@doctors.org.uk.

Copyright © 2017 International Anesthesia Research Society  
DOI: 10.1213/XAA.0000000000000595

and urinalysis remained negative. Given the resolution of symptoms MgSO<sub>4</sub> and labetalol were stopped. Soon after the occipito-temporal headache returned, and her blood pressure rose to 179/96 mm Hg. Oral (200 mg total dose) and labetalol infusion provided no relief to either the headache or hypertension. The MgSO<sub>4</sub> infusion was restarted and hydralazine IV 5 to 10 mg/h was administered. A CT venogram was negative for venous sinus thrombosis, and additional PET investigations were negative.

In view of the atypical nature of her clinical picture, RCVS was suspected and a MRA was obtained. It demonstrated multifocal segmental narrowing of middle cerebral arteries and confirmed the diagnosis (Figure A). The patient was treated with 60 mg nimodipine orally 4 times per day. The headache and hypertension subsequently resolved, and repeat MRA scanning 6 weeks later demonstrated resolution.

## DISCUSSION

The pathophysiology of RCVS remains unclear.<sup>2</sup> One proposed mechanism suggests there is a transient dysregulation of cerebral vascular tone, leading to multifocal arterial constriction and dilation.<sup>1-3</sup> Prior migraine is documented in 40% of cases, 9% of cases have a history of recent pregnancy, and there appears to be a secondary cause in 60% of cases (hormonal, the puerperium, vasoactive drugs, calcineurin inhibitors, tacrolimus, and autoimmune disease).<sup>2</sup> A link between the use of vasoconstrictive drugs (including ergot alkaloid uterotonics) during labor or delivery is described in 50% to 70% of postpartum cases<sup>1,3</sup>; however, these medications were not used in this case.

Headache is common in the postpartum—37% incidence in the first week after delivery.<sup>5</sup> Differentiating benign from serious causes of headache relies on a detailed history, neurological examination, and timely neurological imaging. The most common causes of postpartum headaches are tension/migraine (47%), preeclampsia/eclampsia (24%), PDPH (16%), and RCVS (1%). Rarer causes include cortical vein thrombosis (10–20/100,000 deliveries), subarachnoid hemorrhage (20/100,000 pregnancies), space occupying lesions, cerebral infarction/ischemia, sinusitis, and meningitis.<sup>5</sup>

The most common misdiagnoses for RCVS are migraines and tension headaches. Migraine classically presents with aura, photophobia, and recurring personal history. Tension headaches are described as a band-like headache with no exacerbating features and are self-resolving. They are usually responsive to analgesia.<sup>4</sup>

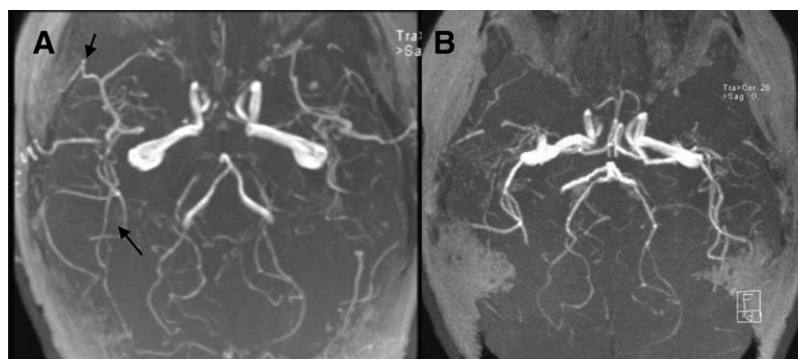
In the postpartum period, preeclampsia/eclampsia is a common cause of headache with associated hypertension, even in the absence of proteinuria.<sup>1,6</sup> Postpartum preeclampsia can be more severe than pre/peripartum disease with resistant hypertension, increased seizure incidence, and headache as prominent presenting features.<sup>7</sup> However, without prior hypertension and with negative screening throughout pregnancy, de novo postpartum preeclampsia is a diagnosis of exclusion.<sup>8</sup> Additionally, in the postpartum period, PDPHs may be described.

Posterior reversible encephalopathy syndrome (PRES) can coexist with RCVS. It presents with encephalopathy, seizures, visual disturbances, and headaches. The headache, however, is usually gradual in onset, peaking at 24 to 48 hours, and often resolves within 7 days. The other symptomatic differences with RCVS are the visual disturbances that present as cortical blindness, blurring, or hemianopia. While PRES shares a number of similar radiological findings with RCVS<sup>9</sup> (cerebral vasoconstriction and possible convexity subarachnoid hemorrhage, intracerebral hemorrhage, and infarction), PRES may demonstrate evidence of parieto-occipital vasogenic edema on magnetic resonance imaging<sup>9</sup> that is not present in RCVS.<sup>1</sup> Magnetic resonance imaging and MRA will be required to see the pathognomic vasoconstriction of RCVS.

Finally intracranial bleeds, venous sinus thrombi, or space occupying lesions must be considered. History may be of sudden onset headache, visual and/or focal neurological deficit, and symptoms of raised intracranial pressure. Plain CT and CT venograms should exclude these diagnoses. It is important to note that if CT imaging has ruled out intracranial bleeds or space occupying lesions, radiologists may be reluctant to perform an MRA unless exclusion of RCVS is specifically requested.

In this case, the initial diagnosis was of a PDPH based on the postural element of the headache. An epidural blood patch was performed. Fortunately this did not lead to any long-term sequelae. This case highlights the difficulty in using the positional nature of PDPH as a discriminator, as it is often present in several other neurological conditions. Nonresolution of a presumed PDPH with epidural blood patch should prompt further investigation.

Hypertension and seizures led to an alternate diagnosis of eclampsia despite negative PET bloods and urinalysis. The seizure's response to treatment likely represents magnesium's vasodilatory effect on cerebral vasoconstriction. While treatment of preeclampsia serendipitously



**Figure.** A, MRA: initial MRA, the arrows depicting arterial “nipping” in medium-sized vessels and the MRA repeated 6 weeks after treatment and resolution of vasoconstriction; B, resolution of the AV nipping. MRA indicates magnetic resonance angiography.

relieved the symptoms of RCVS, it encouraged acceptance of eclampsia as the diagnosis, thus causing delay in further investigation.

RCVS self-resolves in all cases; however, this may take several weeks. Nimodipine 60 mg orally every 4 hours is given prophylactically to avoid encephalopathy, intracranial bleed, and the reflex hypertension caused by cerebral vasoconstriction. Nimodipine seems to be safe in breast-feeding mothers,<sup>10</sup> with negligible exposure to neonate. Neurology referral and ongoing management of patients is recommended. Serial MRAs show vasoconstriction resolution and determine treatment cessation.

## CONCLUSIONS

RCVS may be easily misdiagnosed given its poorly characterized clinical picture. However, women in the puerperium are at increased risk<sup>6</sup> and anesthetists may come across such patients, possibly in the management of presumed PDPH or in the control of resistant hypertension. Assumption that headaches, seizures, and resistant hypertension are preeclampsia/eclampsia until proven otherwise seems prudent given the higher incidence and life threatening nature. However, other conditions should be considered if symptoms return on cessation of medications. Thorough history and neurological exam are essential to differentiating diagnoses, but acquiring an MRA to show the pathognomic cerebral vasoconstriction that CT will not elucidate is key. In reporting this case, we hope to raise awareness of RCVS among anesthetists, avoid future misdiagnosis, and aid prompt investigation and management of this serious condition. ■■

## DISCLOSURES

**Name:** Ed McIlroy, MBBS, MRes, FRCA.

**Contribution:** This author helped search and review the literature, obtain patient consent, and edit and review the manuscript.

**Name:** Rajamani Sethuraman, MD, FRCA.

**Contribution:** This author helped search and review the literature, edit and review the manuscript, and supervise anesthetic practice.

**Name:** Reshma Woograsingh, MBBS, BSc, FRCA.

**Contribution:** This author helped search and review the literature, edit and review the manuscript, and supervise anesthetic practice.

**Name:** Catherine Nelson-Piercy, MBBS, MA, FRCP, FRCOG.

**Contribution:** This author helped search and review the literature, edit and review the manuscript, and supervise anesthetic practice.

**Name:** Edward Gilbert-Kawai, PhD, MBBS, FRCA, DRCOG.

**Contribution:** This author helped search and review the literature, obtain patient consent, and edit and review the manuscript.

**This manuscript was handled by:** Raymond C. Roy, MD.

## REFERENCES

1. Wiles KS, Nortley R, Siddiqui A, Holmes P, Nelson-Piercy C. Reversible cerebral vasoconstriction syndrome: a rare cause of postpartum headache. *Pract Neurol*. 2015;15:141–144.
2. Sattar A, Manousakis G, Jensen MB. Systematic review of reversible cerebral vasoconstriction syndrome. *Expert Rev Cardiovasc Ther*. 2010;8:1417–1421.
3. Singhal AB, Hajj-Ali RA, Topcuoglu MA, et al. Reversible cerebral vasoconstriction syndromes: analysis of 139 cases. *Arch Neurol*. 2011;68:1005–1012.
4. Anzola GP, Brighenti R, Cobelli M, et al. Reversible cerebral vasoconstriction syndrome in puerperium: a prospective study. *J Neurol Sci*. 2017;375:130–136.
5. Sabharwal A. Postpartum headache: diagnosis and management. *Contin Educ Anaesth Crit Care Pain*. 2011; 5: 181–185.
6. Ducros A, Bousser MG. Reversible cerebral vasoconstriction syndrome. *Pract Neurol*. 2009;9:256–267.
7. Sibai BM. Etiology and management of postpartum hypertension-preeclampsia. *Am J Obstet Gynecol*. 2012;206:470–475.
8. Wolff V, Ducros A. Reversible cerebral vasoconstriction syndrome without typical thunderclap headache. *Headache*. 2016;56:674–687.
9. Fugate JE, Rabinstein AA. Posterior reversible encephalopathy syndrome: clinical and radiological manifestations, pathophysiology, and outstanding questions. *Lancet Neurol*. 2015;14:914–925.
10. Tonks AM. Nimodipine levels in breast milk. *Aust N Z J Surg*. 1995;65:693–694.