


Accepted Manuscript

Transdural indocyanine green videography for STA-MCA bypass – technical note

Hiroshi Yokota, Taiji Yonezawa, Tomonori Yamada, Seisuke Miyamae, Taekyun Kim, Yoshiaki Takamura, Katsuya Masui, Shuta Aketa



PII: S1878-8750(17)31103-8

DOI: [10.1016/j.wneu.2017.07.004](https://doi.org/10.1016/j.wneu.2017.07.004)

Reference: WNEU 6066

To appear in: *World Neurosurgery*

Received Date: 10 March 2017

Revised Date: 1 July 2017

Accepted Date: 5 July 2017

Please cite this article as: Yokota H, Yonezawa T, Yamada T, Miyamae S, Kim T, Takamura Y, Masui K, Aketa S, Transdural indocyanine green videography for STA-MCA bypass – technical note, *World Neurosurgery* (2017), doi: 10.1016/j.wneu.2017.07.004.

This is a PDF file of an unedited manuscript that has been accepted for publication. As a service to our customers we are providing this early version of the manuscript. The manuscript will undergo copyediting, typesetting, and review of the resulting proof before it is published in its final form. Please note that during the production process errors may be discovered which could affect the content, and all legal disclaimers that apply to the journal pertain.

Transdural indocyanine green videography for STA-MCA bypass – technical note

Hiroshi Yokota^{1,2}, Taiji Yonezawa¹, Tomonori Yamada¹, Seisuke Miyamae¹, Taekyun Kim¹, Yoshiaki Takamura¹, Katsuya Masui¹, Shuta Aketa¹

¹Department of Neurosurgery, Osaka Police Hospital, Osaka, Japan

²Department of Neurosurgery, Nara Medical University, Kashihara, Nara, Japan

Corresponding author:

Hiroshi Yokota, MD, Department of Neurosurgery, Nara Medical University, Shijo-cho 840, Kashihara, Nara 634-8522, Japan

Tel: +81 744 22 8866; Fax: +81 744 29 0818.

Email: hyokota0001@gmail.com

Department of Neurosurgery, Osaka Police Hospital, Kitayama-cho 10-31, Tennouji-ku, Osaka 543-0035, Japan

Tel: +81 6 6775 2870, Fax: +81 6 6771 6051.

Key words: indocyanine green videography, superficial temporal artery to middle cerebral artery bypass, steno-occlusive disease

ABSTRACT

BACKGROUND

Neurosurgical application of indocyanine green (ICG) videography prior to performing a dural opening has been reported as transdural ICG videography and used during surgery of meningiomas associated with venous sinuses, as well as cranial and spinal arteriovenous malformations. However, its use for a superficial temporal artery to middle cerebral artery (STA-MCA) bypass has not been reported.

METHODS

We performed a retrospective analysis of medical records of patients who underwent a transdural ICG videography technique during STA-MCA bypass procedures performed between January 2012 and March 2015. The primary outcome was visualization of recipient cortical arteries, while the secondary outcomes were surgical modifications and complications, as well as any adverse events associated with transdural ICG videography.

RESULTS

We analyzed 29 STA-MCA bypass procedures performed in 30 hemispheres with atherosclerotic steno-occlusive disease and found that the proper recipient was identified in 28 hemispheres. The subsequently modified procedures for those were a tailored dural incision and craniotomy correction. No complications associated with ICG administration were encountered, while transient aphasia was noted in 1, chronic subdural hematoma in 1, and subdural effusion in 2 cases during the postoperative course.

CONCLUSIONS

A transdural ICG technique for atherosclerotic steno-occlusive disease facilitates modifications during STA-MCA bypass procedures. Recognition of the proper recipient cortical arteries prior to a dural incision allows the neurosurgeon to perform a tailored dural incision and extension of the bone window, though the contribution to surgical outcome has yet to be determined.

INTRODUCTION

Indocyanine green (ICG) videography has become an important multimodal technique and commonly utilized to confirm bypass patency during neurosurgical procedures.¹ Furthermore, the usefulness of transdural observation of the venous sinuses in meningioma cases prior to dural opening has been reported as transdural ICG videography.² Here, we present our experience with transdural ICG videography for cases of superficial temporal artery to middle cerebral artery (STA-MCA) bypass used to observe the recipient cortical arteries prior to opening the dura. Benefits, limitations, and other potential uses are also discussed.

MATERIALS AND METHODS

Between January 2012 and March 2015, 44 STA-MCA bypass procedures were performed at the Department of Neurosurgery of Osaka Police Hospital, Osaka, Japan. After reviewing medical charts and operative records, we included 30 transdural ICG procedures performed in 29 patients for this study. Identification of the proper recipient

artery, subsequent modification of the procedure, difficulties, and complications were assessed based on findings of retrospective evaluations of the operative records and medical charts. The primary outcome was visualization of the proper recipient cortical artery, while the secondary outcomes were surgical modifications and complications, as well as any adverse events associated with transdural ICG videography.

All patients underwent cerebral angiography before the operation. Individual neurosurgeons planned and performed the STA-MCA bypass procedures in each case. Briefly, a linear incision on the parietal branch of the STA was preferred. The STA was dissected and the distal portion cut prior to the craniotomy. Following exposure of dura matter, 25 mg of ICG was dissolved in a 10-ml solution, of which 7.5 mg of ICG in a 3-ml solution was intravenously administered. Superficial vessels, including the cortical arteries, and cortical and sylvian veins, were observed through a microscope (OPMI, Pentero, Carl Zeiss Meditec, Germany), with the recipient cortical artery location marked on the dura matter with pyoktanin blue during this observation. Following dural opening, STA-MCA anastomosis was performed. Bypass patency was confirmed by a second intravenous administration of ICG (7.5 mg).

RESULTS

We retrospectively analyzed 30 procedures performed in 29 patients who underwent transdural ICG. Their mean age was 66 years (range 36-84 years) and the male to female ratio was 2.6 to 1. A total of 29 STA-MCA bypass procedures performed in 30 hemispheres were identified, including 1 bilateral STA-MCA bypass and 2 cases with

unilateral double-barrel anastomosis. An atherosclerotic steno-occlusive lesion of the intracranial internal carotid or middle cerebral artery was found in 28 cases, while 1 had unilateral moyamoya disease. Transdural observation following ICG administration assisted with identification of the proper recipient artery in 28 hemispheres. Typically, the distribution of the cortical arteries from the Sylvian fissure was well visualized by transdural observation after ICG administration (Figure 1). Various tailored dural incisions, such as linear or T-like types, were made to expose the recipient cortical artery in these patients, while the edge of the craniotomy was widened in 3 prior to dural opening. The proper cortical artery was not identified in 2 cases, which required a subsequent wide dural opening (Figure 2). Bypass patency was confirmed by ICG videography findings in all patients. Postoperative complications included transient aphasia in 1, chronic subdural hematoma in 1, and subdural effusion in 2 cases. No complications associated with ICG administration were encountered.

REPRESENTATIVE CASE

A 65-year-old man had a minor ischemic stroke and underwent STA-MCA bypass for atherosclerotic cerebrovascular insufficiency due to right intracranial internal carotid artery stenosis. Following a craniotomy (Figure 3a), the infra-Sylvian M4 portion of the middle cerebral artery was confirmed by intravenous administration of 7.5-mg of ICG prior to dural opening (Figure 3b). A T-shaped dural opening revealed the recipient cortical artery, to which the STA was anastomosed, then bypass patency was again confirmed with ICG videography. The postoperative course was good.

DISCUSSION

Use of transdural ICG videography has been reported in cases of surgery for a meningioma adjacent to the venous sinuses.²⁻⁴ This technique allows the neurosurgeon to recognize the anatomical relationship of the tumor and venous sinuses prior to dural opening, thus can assist with performance of a subsequent safe dural opening. Previous studies have demonstrated its usefulness in cases of vascular malformations, including arteriovenous malformations, dural arteriovenous fistulas, spinal perimedullary arteriovenous fistulas, intradural spinal tumors, and hemangioblastomas.⁵⁻⁸

Recognition of vital structures prior to dural opening, such as feeding arteries, highly vascularized lesions, and draining veins, allows the neurosurgeon to perform a safe dural opening and avoid injury to the underlying vital structures. In addition, in cases with arteriovenous malformations, a craniotomy can be sufficiently corrected to a wide and safe exposure for subsequent procedures.⁵ Schubert et al. also emphasized that a bony exposure can be corrected prior to dural incision in thoracic meningioma cases with an unintended inadequate laminectomy.⁸ In our series, the craniotomy edge was widened prior to dural opening for adequate exposure of the recipient cortical arteries in 3 cases.

Two administrations of ICG at 7.5 mg (total dosage 15 mg) were used in each of the present cases, which is equivalent to a dosage of 0.3 mg/kg for a patient with a body weight of 50 kg. The recommended dosage in Japan is 0.1-0.3 mg/kg,⁹ while 0.2-0.5 mg/kg with a maximum of 5 mg/kg/day has been recommended in other studies.^{7, 10}

Thus, lack of strict dosage according to body weight is one of the major limitations of this study. Since images obtained with transdural ICG videography have lower clarity as compared to direct visual observation and the accuracy of the results obtained must be prospectively verified by comparisons of two images. Dura matter thickness and hemostasis, as well as the condition of the subdural space can also have effects on transdural ICG videography quality. In addition, the retrospective nature of our study, along with the small sample size and lack of control group, limit our conclusions regarding the accuracy and efficacy of transdural ICG videography for performance of STA-MCA bypass. On the other hand, the technique is easily performed and can be useful for observing a single target cortical artery in relation to the bone window. In cases when the neurosurgeon is confident about the operative plan and procedures, the target cortical artery will appear in the expected portion of the operative field in transdural observations. Should the target cortical artery appear at the edge of the operative field, modifications, such as a tailored dural incision or additional bony removal, can be considered. The dural incision should be made so as to adequately expose the recipient cortical artery, while avoiding a deeper operative field after loss of cerebrospinal fluid. Since an ICG technique is limited and can only reveal superficial structures in the operative field, cortical arteries within the Sylvian fissure and cerebral sulci are difficult to visualize. Nevertheless, transdural ICG videography may have advantages when used for a combined direct and indirect bypass procedure for moyamoya disease to clarify the relationship of the overlying middle meningeal artery with the underlying cortical arteries.

CONCLUSIONS

Use of transdural ICG videography for STA-MCA bypass procedure allows the neurosurgeon to recognize the recipient cortical arteries prior to performing a dural incision, which allows modifications as needed, such as a tailored dural incision or extension of the bone window. The contribution of a transdural ICG technique to surgical outcome has yet to be determined, though some benefits in regard to STA-MCA bypass procedures are suggested.

References

1. Woitzik J, Horn P, Vajkoczy P, Schmiedek P. Intraoperative control of extracranial-intracranial bypass patency by near-infrared indocyanine green videoangiography. *J Neurosurg* 2005;**102**:692-8.
2. Ueba T, Abe H, Higashi T, Inoue T. Transdural imaging of meningiomas by indocyanine green videography: the eclipse sign. *J Neurol Surg A Cent Eur Neurosurg* 2013;**74**:51-3.
3. d'Avella E, Volpin F, Manara R, Scienza R, Della Puppa A. Indocyanine green videoangiography (ICGV)-guided surgery of parasagittal meningiomas occluding the superior sagittal sinus (SSS). *Acta Neurochir (Wien)* 2013;**155**:415-20.
4. Ueba T, Okawa M, Abe H, et al. Identification of venous sinus, tumor location,

- and pial supply during meningioma surgery by transdural indocyanine green videography. *J Neurosurg* 2013;**118**:632-6.
5. Della Puppa A, Rustemi O, Gioffre G, Causin F, Scienza R. Transdural indocyanine green video-angiography of vascular malformations. *Acta Neurochir (Wien)* 2014;**156**:1761-7.
 6. Kim EH, Cho JM, Chang JH, Kim SH, Lee KS. Application of intraoperative indocyanine green videoangiography to brain tumor surgery. *Acta Neurochir (Wien)* 2011;**153**:1487-95; discussion 94-5.
 7. Schubert GA, Schmieder K, Seiz-Rosenhagen M, Thome C. ICG videography facilitates interpretation of vascular supply and anatomical landmarks in intramedullary spinal lesions: two case reports. *Spine (Phila Pa 1976)* 2011;**36**:E811-3.
 8. Schubert GA, Barth M, Thome C. The use of indocyanine green videography for intraoperative localization of intradural spinal tumors. *Spine (Phila Pa 1976)* 2010;**35**:E212-7.
 9. Tanabe N, Yamamoto S, Kashiwazaki D, et al. Indocyanine green visualization of middle meningeal artery before craniotomy during surgical revascularization for moyamoya disease. *Acta Neurochir (Wien)* 2017;**159**:567-75.
 10. Killory BD, Nakaji P, Gonzales LF, Ponce FA, Wait SD, Spetzler RF. Prospective evaluation of surgical microscope-integrated intraoperative near-infrared indocyanine green angiography during cerebral arteriovenous malformation surgery. *Neurosurgery* 2009;**65**:456-62.

Figure legends

Figure 1.

Representative case of 62-year-old male with right intracranial internal carotid artery stenosis.

(a) Microscopic view of dura matter. (b) Transdural observation after administration of ICG revealed well-visualized cortical arteries emerging from the Sylvian fissure. (c)

The recipient infra-sylvian cortical artery shown after dural opening.

Figure 2.

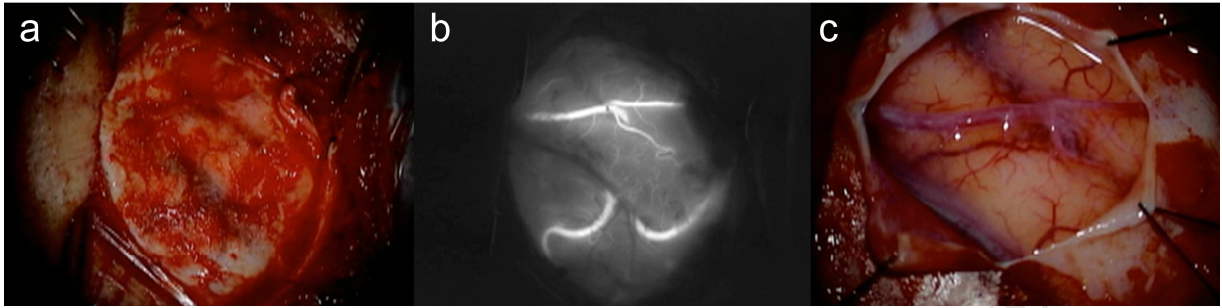
Representative case of 71-year-old female with right middle cerebral artery occlusion.

(a) Microscopic view of dura matter. (b) Transdural observation after administration of ICG did not detect the recipient cortical arteries. (c) Shown is the recipient cortical artery (indicated by forceps) determined after a widened dural opening.

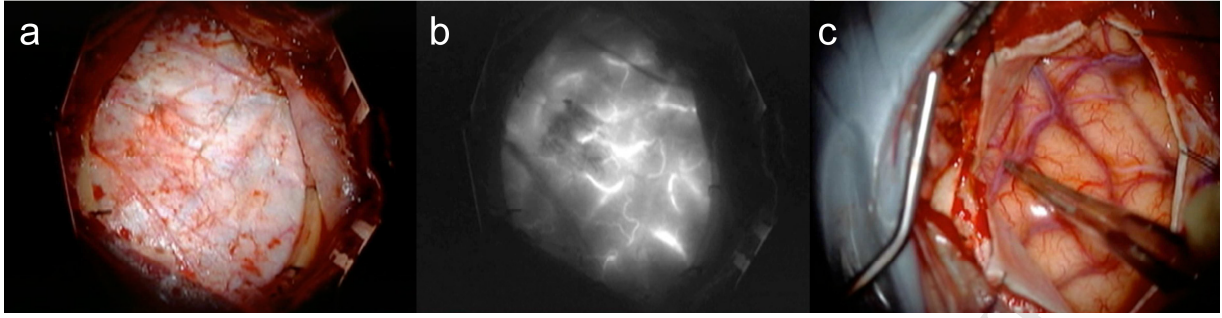
Figure 3.

Representative case of 65-year-old male with right intracranial internal carotid artery stenosis.

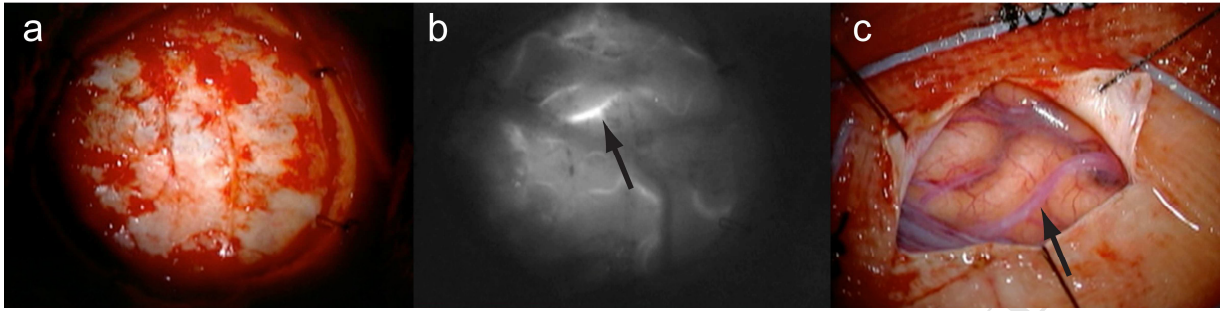
(a) Microscopic view of dura matter. Arrows show recipient cortical artery (b) during application of transdural ICG and (c) after performing a T-shaped dural opening.



ACCEPTED MANUSCRIPT



ACCEPTED MANUSCRIPT



ACCEPTED MANUSCRIPT

Highlights

1. We applied transdural indocyanine green (ICG) videography for cases of superficial temporal artery to middle cerebral artery (STA-MCA) bypass.
2. The recipient cortical arteries were well visualized by transdural observation following intravenous administration of 7.5 mg of ICG.
3. Transdural ICG videography for patients who underwent an STA-MCA bypass allowed the attending neurosurgeons make some modifications, such as a tailored dural incision and craniotomy correction.

Abbreviations and Acronyms

ICG: Indocyanine green

STA-MCA bypass: Superficial temporal artery to middle cerebral artery bypass