

## Letter to the Editor

### Unilateral right prosopometamorphopsia with positive “half-face-covering-test” after small occipitotemporal stroke



## Keywords:

Visual perception  
Neuropsychology  
Stroke  
MRI

Dear Sir,

Face recognition is a challenging, complex task which requires expertly discrimination of three-dimensional facial shape, diversified facial expression, age, gender and perception from different angle [1]. There are several characteristic disturbances of visual perception like the inability to recognize familiar faces (prosopagnosia), usually caused by lesions of the medial occipitotemporal cortex [1–3], or the Charles Bonnet syndrome with complex visual hallucinations [4]. Beyond, facial metamorphopsia after brain injury has been reported as an unusual symptom in some rare cases [5–8].

#### 1. Case report

A 58-year-old woman presented with acute and unusual face perception disturbance after coronary angiography in case of a high-grade stenosis of the left anterior descending artery. Immediately after angiography she described a deformed, back-shifted left half of faces when looked out of the patient's view, including the own mirror image and faces on photos and magazines. Further clinical neurological examinations revealed no focal or neuropsychological deficits. The reported unilateral metamorphopsia persisted when the left or right eye was covered. Interestingly, the further examination showed that when covering the non-affected left and undisturbed side of the face of the interlocutor, the affected right side of the face was immediately seen without any distortion. Cranial MRI revealed two small occipitotemporal ischemic lesions including the right posterior cingulate gyrus and parts of the major forceps, most likely due to small embolism related to the diagnostic procedure of coronary angiography (Fig. 1). Visual evoked potentials were compatible with a right-lateral retrochiasmatal lesion. Further ophthalmological investigation including perimetry was unremarkable. We termed this unusual symptom as “unilateral right prosopometamorphopsia”. Two days after the symptoms have resolved completely.

#### 2. Discussion

The unilateral right prosopometamorphopsia in this case referred exclusively contralateral to the brain lesion without concomitant

prosopagnosia. Previous reported cases with hemifacial metamorphopsia mostly dealt with micropsias relating to scotomas [5,6]. Ebata et al. described a case of right sided retrosplenial hemorrhage with attendant hemimicropsia and distortion of the right, contralateral, half of the examiner's face [7]. Miwa and Kondo reported a case of metamorphopsia restricted to the right half of the face, which is very similar to our case. Likewise, in this case perimetric examination revealed no scotoma [8].

Facial dysmorphopsia might be explained by the face-processing model by Bruce and Young and the hypothesis of Trojano et al. reporting that early face processing phases are based on parallel mechanisms in both hemispheres. During further phases specialized right hemispheric functions are critically required for visual perception and particular face recognition [1,6]. Several fMRI-studies identified three regions of face recognition and processing in the occipito-temporal cortex [9–10]: the fusiform face area (FFA), occipital face area (OFA) and posterior part of the superior temporal sulcus (STS).

In summary, we report a case with acquired “unilateral right prosopometamorphopsia” due to an ischemic lesion in the posterior cingulate gyrus, interestingly with regressive symptoms while covering the non-affected undisturbed side of the face of the interlocutor. Regarding to Miwa and Kondo literature provides 11 further reported cases of metamorphopsia, micropsia or macropsia of the face with temporal, parietal, occipital and retrosplenial locations of the lesion [8]. The underlying diagnosis were bleedings, infarctions, tumor and in one case an abscess. The pathoanatomical basis of the phenomenon of symptom regression when covering the non-affected side of the face remains unclear. However, we would propose to include this “half-face-covering-test” described above in clinical neurological examination in comparable cases.

#### Conflicts of interest

This study was not industry-sponsored.

CK reports no disclosures.

CSG reports no disclosures.

VB reports no disclosures.

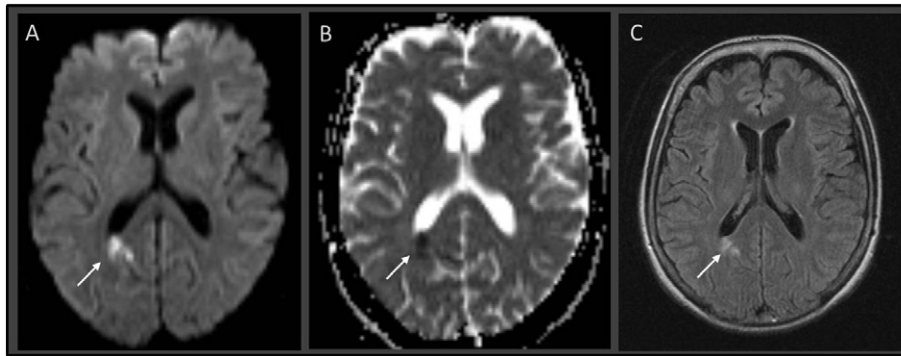
TG reports no disclosures.

CL reports no disclosures.

RG serves on scientific advisory boards for Teva Pharm. Ind. Ltd., Biogen Idec, Bayer Schering Pharma, and Novartis; has received speaker honoraria from Biogen Idec, Teva Pharmaceutical Industries Ltd., Bayer Schering Pharma, and Novartis; serves as editor for Therapeutic Advances in Neurological Diseases and on the editorial boards of Experimental Neurology and the Journal of Neuroimmunology; and receives research support from Teva Pharmaceutical Industries Ltd., Biogen Idec, Bayer Schering Pharma, Merck Serono, and Novartis.

CK received travel grants for scientific meetings from Bayer Vital and Bristol-Meyer Squidd.

Each author declares that he has no ownership interest and does not own stocks of any pharmaceutical company.



**Fig. 1.** MRI of the 58-year-old patient with unilateral right prosopometamorphopsia, performed two days after onset. Diffusion-weighted imaging (A) including ADC maps (B) revealed an area with restricted diffusion in the right occipital lobe (white arrow) partly including the right posterior cingulate gyrus and parts of the major forceps. The ischemic area is depicted bright on the corresponding FLAIR sequence (C).

### Ethical standards

The manuscript submitted for publication has been performed in accordance with the ethical standards laid down in the 1964 Declaration of Helsinki and its later amendments.

### Acknowledgements

None

### References

- [1] V. Bruce, A. Young, Understanding face recognition, *Br. J. Psychol.* 77 (1986) 305–327.
- [2] T. Landis, J.L. Cummings, L. Christen, J.E. Bogen, H.G. Imhof, Are unilateral right posterior cerebral lesions sufficient to cause prosopagnosia? Clinical and radiological findings in six additional patients, *Cortex* 22 (1986) 243–252.
- [3] A.R. Damasio, H. Damasio, G.W. Van Hoessen, Prosopagnosia: anatomic basis and behavioral mechanisms, *Neurology* 32 (1982) 331–341.
- [4] A. Chaudhuri, Charles Bonnet syndrome: an example of cortical dissociation syndrome affecting vision, *J. Neurol. Neurosurg. Psychiatry* 5 (2000) 704–705.
- [5] Y. Ida, T. Kotorii, Y. Nakazawa, A case of epilepsy with ictal metamorphopsia, *Folia Psychiatr. Neurol. Jpn* 34 (1980) 395–396.
- [6] L. Trojano, M. Conson, S. Salzano, V. Manzo, D. Grossi, Unilateral left prosopometamorphopsia: a neuropsychological case study, *Neuropsychologia* 47 (2009) 942–948.
- [7] S. Ebata, M. Ogawa, Y. Tanaka, Y. Mizuno, M. Yoshida, Apparent reduction in the size of one side of the face associated with a small retrosplenial haemorrhage, *J. Neurol. Neurosurg. Psychiatry* 54 (1991) 68–70.
- [8] H. Miwa, T. Kondo, Metamorphopsia restricted to the right side of the face associated with a right temporal lobe lesion, *J. Neurol.* 254 (2007) 1765–1767.
- [9] G. McCarthy, A. Puce, J.C. Gore, T. Allison, Face-specific processing in the human fusiform gyrus, *J. Cogn. Neurosci.* 9 (1997) 605–610.
- [10] J.V. Haxby, E.A. Hoffman, M.I. Gobbini, The distributed human neural system for face perception, *Trends Cogn. Sci.* 4 (2000) 223–233.

Christoph Schroeder  
 Christiane Schneider-Gold  
 Volker Behrendt  
 Thomas Grüter  
 Dept. of Neurology, Ruhr University, St. Josef-Hospital, Gudrunstr, 56,  
 Bochum, Germany  
 E-mail addresses: christoph.schroeder@ruhr-uni-bochum.de  
 (C. Schroeder),  
 christiane.schneider-gold@rub.de (C. Schneider-Gold),  
 Thomas.grueter@ruhr-uni-bochum.de (T. Grüter).

Carsten Lukas  
 Dept. of Radiology, Ruhr University, St. Josef-Hospital, Gudrunstr, 56,  
 Bochum, Germany  
 E-mail address: carsten.lukas@rub.de.

Ralf Gold  
 Christos Krogias\*  
 Dept. of Neurology, Ruhr University, St. Josef-Hospital, Gudrunstr, 56,  
 Bochum, Germany  
 \*Corresponding author.  
 E-mail addresses: ralf.gold@rub.de (R. Gold),  
 christos.krogias@rub.de (C. Krogias).

14 April 2017