



Video-Clinical Corners

Stereotyped episodes of aphasia and immobility: how cataplexy mimics stroke in an elderly patient

E. Antelmi ^{a, b}, F. Pizza ^{a, b}, S. Vandi ^{a, b}, G. Plazzi ^{a, b, *}^a Department of Biomedical and Neuromotor Sciences, Alma Mater Studiorum, University of Bologna, Bologna, Italy^b IRCSS, Institute of Neurological Sciences, Bologna, Italy

ARTICLE INFO

Article history:

Received 13 March 2017

Received in revised form

9 May 2017

Accepted 30 May 2017

Available online 19 June 2017

Keywords:

Narcolepsy

Cataplexy

Stroke

TIA

Misdiagnosis

1. Introduction

Narcolepsy type 1 (NT1) is a rare and lifelong disease with a peak of incidence in childhood [1]. Cataplexy, (ie, sudden loss of muscle tone triggered by emotions), is the clinical hallmark of NT1 [1]. Diagnostic delay is a major issue, and is partially related to scarce awareness of the disease as well as multifaceted features of NT1 throughout the lifespan [2–5]. The diagnosis of NT1 in the elderly is fairly common, partially due to great diagnostic delay [2]. Genuine late-onset NT1 is, however, rare [1], and few data are available about its clinical prognosis/diagnosis/outlook.

Here, we report on an elderly acute onset NT1 patient presenting with cataplexy features that challenged the diagnosis and led to incorrect treatments.

2. Case report

The patient is a 57-year-old right-handed man. He was a heavy smoker and a regular alcohol consumer. Past medical history

included a myocardial infarct when he was in his early fifties. At the age of 56, while working, he had a first episode of speech and motor arrest; the patient was standing when he suddenly stopped moving and could not answer when called by coworkers. After up to five minutes, the patient recovered, reporting that he was fully conscious during this episode. The patient was carried to the intensive care unit, where during the clinical examination he had four additional similar paroxysmal episodes, lasting up to five minutes. He was evaluated at the stroke unit and his brain computer tomography and brain magnetic resonance scans showed periventricular multiple foci of chronic ischemic lesions. The patient was judged eligible for thrombolysis and received standard recombinant tissue plasminogen activator (rt-PA) dose. Subsequent diagnostic investigations disclosed an atrial fibrillation and the patient was started on oral anticoagulants. Paroxysmal episodes of speech and motor arrest however continued with a daily frequency. At this time, he also started reporting increased tiredness and daytime sleepiness, but no clear sleep attacks or additional sleep complaints. Neurological interictal examination was reported as normal, as well as interictal and “ictal” EEG. However during the EEG monitoring the patient displayed multiple sleep attacks, lasting a few seconds each. Ambulatory cardiorespiratory monitoring during sleep disclosed a mild obstructive sleep apnea (OSA) and the patient was discharged under continuous positive airway pressure (CPAP) treatment.

Despite a good compliance with the CPAP, hypersomnolence and paroxysmal attacks of transient aphasia and immobility continued.

The patient was admitted to our sleep clinic with a complaint of chronic sleepiness; a diagnosis of NT1 was established, based on multiple sleep latency test showing pathologically reduced sleep latency (mean: 2' 30") and 4/5 REM sleep onset periods (REM latency: mean 4' 30"), undetectable CSF hypocretin-1, and HLA-DQB1*06:02 positivity. Subsequent treatment with sodium oxybate and modafinil ameliorated both sleepiness and cataplexy.

3. Video analysis

The video shows the cataplectic episode captured while performing the neurological examination. The patient was under synchronized video-polysomnographic (VPSG) recording, when he had a

* Corresponding author. Department of Biomedical and Neuromotor Sciences, Alma Mater Studiorum, University of Bologna, Via Altura 3, Bologna, Italy.

E-mail address: giuseppe.plazzi@unibo.it (G. Plazzi).

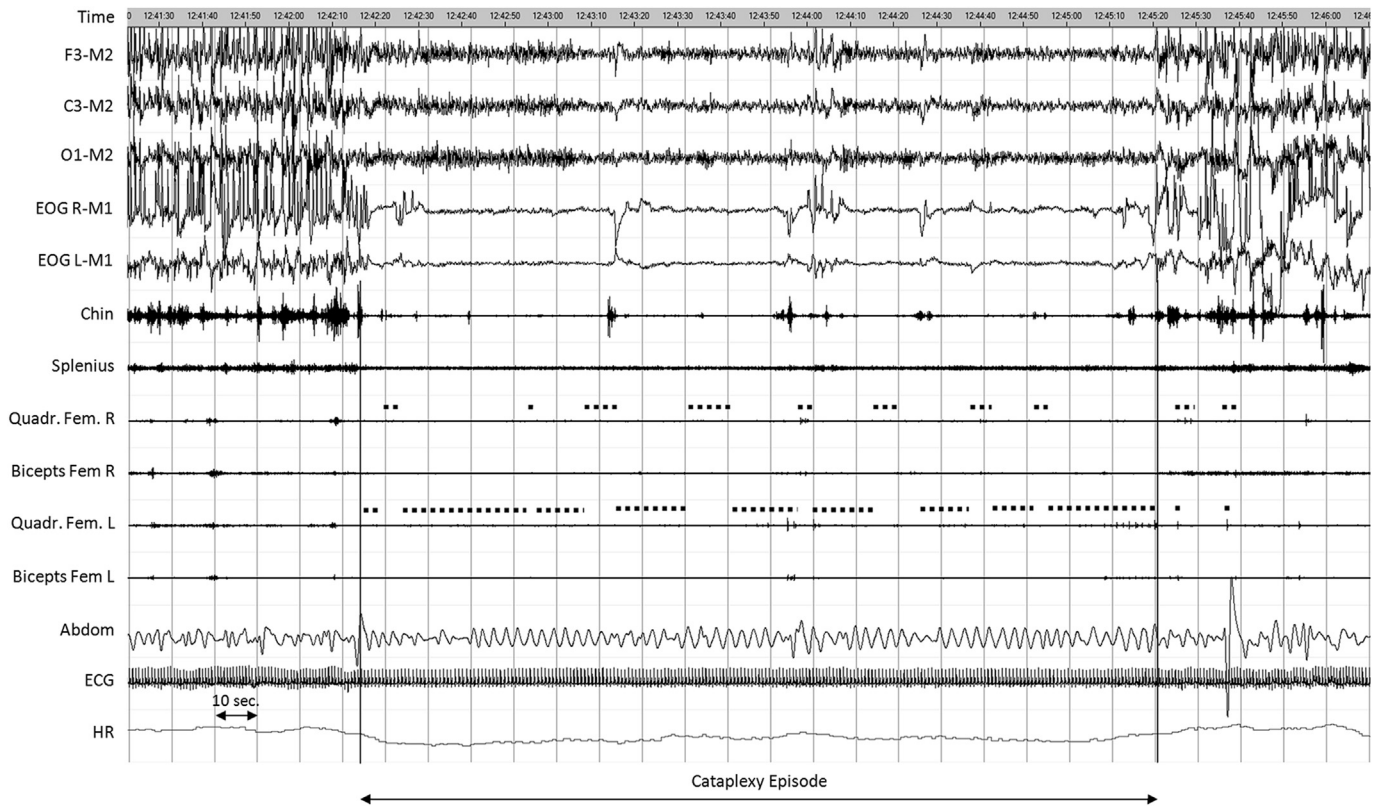


Fig. 1. Polygraphic draft showing the neurophysiological background of the cataplectic spell in our patient. EEG channels displayed a wake activity, while atonia was evident over the chin-EMG tracing with intermixed phasic activity. Abdominal respirogram showed few breathing irregularities, with HR deceleration. Dotted lines above the quadriceps femoris (right and left) indicate when the clinician evaluated the osteotendinous reflexes. The polygraphic montage includes the following parameters from the high: EEG channels (F2-M2; C3-M2, O1-M2); EOG-R-M1: electro-oculogram right; EOG-L-M1: electro-oculogram left; Quad. Fem R: quadriceps femoris right; Quad. Fem L: quadriceps femoris left; biceps Fem. R: biceps femoris right; Biceps Fem. L: biceps femoris left; Abdomen: abdominal respirogram; ECG: electrocardiogram; HR: heart rate.

spontaneous episode of speech and motor arrest while talking with the physician. Facial hypotonia was evident in the close-up image, but no other signs of muscle weakness were observable (ie, no head drop). Ankle reflexes were absent at the beginning and then became waxing and waning; reappearance of reflexes and tone was mostly combined with visible rhythmic trunk activation (ie, rotation). The attack was very long (up to three minutes) but no other motor signs (negative or positive) were visible. There was a subsequent rapid recovery, but slurred speech persisted for a few more minutes.

Supplementary video related to this article can be found at <http://dx.doi.org/10.1016/j.sleep.2017.05.016>.

The EEG disclosed a wake activity, without any epileptic abnormalities and EMG tracings disclosed persistent atonia and sparse muscle bursts, corresponding to minimal trunk rotations (Fig. 1).

4. Discussion

This case study is a prime example of misdiagnosis of NT1, leading to inappropriate treatment. In our patient, presentation of cataplexy (without the “floppy aspect” and not related to clear emotional triggers), underestimation of the associated daytime sleepiness and relatively late onset led to a lack of clinical suspicion of NT1, up to the wrong decision to perform thrombolysis. This is meaningful as, if on the one hand several studies suggest that intravenous thrombolysis is not harmful in stroke mimics (cataplexy can be one) [6], on the other hand, diagnostic delay is detrimental for the patient [7]. This case report calls for a new and detailed definition of cataplexy across the life-span, since it remains the pathognomonic symptom of NT1 [1]. Although we agree that

cataplexy usually consists of short episodes of sudden bilateral muscle weakness/paralysis triggered by strong (mainly positive) emotions with preserved consciousness [1], our case points to a wider range of motor manifestations during cataplexy, mainly close to disease onset. Cataplexy should be considered in the differential diagnosis of episodic falls/arrests and acute–subacute onset of excessive daytime sleepiness should not be neglected or overlooked (Supplementary Table).

Another important tip discovered by our VPSG documentation is the loss of osteotendinous (OT) reflexes with retention of posture. Indeed, it is known that H-reflex underlying OT reflex is not a direct measurement of motor neuron excitability, thus proving that while H-reflexes and motor evoked potentials (MEPs) decrease in tandem during REM sleep, this is not the case during cataplexy or during laughter [8].

Authors' role

E.A.: acquisition of data, interpretation of data, drafting the manuscript, revision of the manuscript, final approval to the final version to be published.

F.P.: acquisition of data, interpretation of data, revision of the manuscript, final approval to the final version to be published.

S.V.: acquisition of data, figure and video editing, final approval to the final version to be published.

G.P.: acquisition of data, interpretation of data, drafting the manuscript, revision of the manuscript, final approval to the final version to be published.

The authors have nothing to disclose.

Authors' financial disclosures

E.A.: no disclosures.

F.P.: no disclosures.

S.V.: no disclosures.

G.P.: Consultant for: UCB Pharma, Jazz Pharmaceuticals, Bioproject.

Appendix A. Supplementary data

Supplementary data related to this article can be found at <http://dx.doi.org/10.1016/j.sleep.2017.05.016>.

Conflict of interest

The authors report no conflicts of interest.

The ICMJE Uniform Disclosure Form for Potential Conflicts of Interest associated with this article can be viewed by clicking on the following link: <http://dx.doi.org/10.1016/j.sleep.2017.05.016>.

References

- [1] American Academy of Sleep Medicine. International classification of sleep disorders. Diagnostic and coding manual. 3rd ed. Westchester, IL: American Academy of Sleep Medicine; 2014.
- [2] Thorpy MJ, Krieger AC. Delayed diagnosis of narcolepsy: characterization and impact. *Sleep Med* 2014;15:502–7.
- [3] Serra L, Montagna P, Mignot E, et al. Cataplexy features in childhood narcolepsy. *Mov Disord* 2008;23:858–65.
- [4] Plazzi G, Pizza F, Palaia V, et al. Complex movement disorders at disease onset in childhood narcolepsy with cataplexy. *Brain* 2011;134:3477–89.
- [5] Pizza F, Franceschini C, Peltola H, et al. Clinical and polysomnographic course of childhood narcolepsy with cataplexy. *Brain* 2013;136:3787–95.
- [6] Winkler DT, Fluri F, Fuhr P, et al. Thrombolysis in stroke mimics: frequency, clinical characteristics and outcome. *Stroke* 2009;40:1522–5.
- [7] Maski K, Steinhart E, Williams D, et al. Listening to the patient voice in narcolepsy: diagnostic delay, disease burden, and treatment efficacy. *J Clin Sleep Med* 2017;13:419–25.
- [8] Overeem S, Reijntjes R, Huyser W, et al. Corticospinal excitability during laughter: implications for cataplexy and the comparison with REM sleep atonia. *J Sleep Res* 2004;13:257–64.