

## CASE REPORT

## Stroke of the inferiomedial temporal lobe causing word agnosia

Hardi Hassan,<sup>1</sup> Huq Ehsanula,<sup>2</sup> Mahendra Pattanshetti<sup>2</sup><sup>1</sup>University Hospitals Coventry and Warwickshire NHS Trust, Coventry, UK<sup>2</sup>Maidstone and Tunbridge Wells NHS Trust, Tunbridge Wells, UK**Correspondence to**Dr Hardi Hassan,  
hardi\_galali@hotmail.com

Accepted 20 June 2017

**SUMMARY**

A 69-year-old man presented with sudden loss of ability to recognise written words and remember the meaning of words and names. He could not name the town he lived in nor name his children. It was difficult for him to remember the meaning of concrete and abstract nouns. His speech fluency and understanding of casual talks were normal. He remembered that he had a conversation with his family that morning, but not the exact content. He was referred to the transient ischaemic attack clinic by his general practitioner as he scored low on the abbreviated mental test score. He underwent a brain MRI scan (T2 weighted, diffusion weighted and fluid-attenuated inversion recovery) which showed an acute infarction in the left medial temporal region affecting the fusiform and parahippocampal gyri. He also noticed that it was easier to retrieve numbers, for example, his mobile number. He recovered on waking up the next day.

**BACKGROUND**

This was a rare and elusive presentation for a stroke. It involved the posterior choroidal artery territory, presenting with purely cognitive issues. It was noticed, in this particular case, that retrieving memorised numbers was easier than names. This is an opportunity to study the function of the left inferiomedial aspect of the temporal lobe (involving parts of the fusiform and parahippocampus gyri) and its involvement in the processing of word meaning and cognition.

**CASE PRESENTATION**

A 69-year-old right-handed man had a 4-day history of early morning mild headaches. On the morning of his presentation, he was reading a book when suddenly noticed that he could not remember or make out the meaning of the written words. His wife noticed that he could not understand language involving names of objects and people. When his symptoms continued, he decided to see his general practitioner who recorded amnesia to names, but not numbers. For example, he was not able to recall the name of the city and the road where he lived and could not recall his children's names despite recognising them by their faces. He could not process their names even when mentioned to him. However, he noticed that he could easily remember numbers such as his mobile number. Symptoms improved by the end of the day, and he awoke the following day feeling back to normal. His speech was not affected with regard to grammar and fluency. He

had no other bodily symptoms and no disturbance of vision.

He was seen in the transient ischaemic attack (TIA) clinic the following day, and a brain MRI scan showed an acute left inferiomedial temporal lobe infarction affecting the parahippocampus and fusiform gyrus. His subsequent investigations showed no obvious embolic cause for the stroke.

He was well and performing back to his normal self both cognitively and physically on follow-up 4 weeks later. He received clopidogrel, simvastatin and blood pressure management for secondary prevention.

**INVESTIGATIONS**

The MRI brain scan showed an acute infarction in the left parahippocampal gyrus extending to the fusiform gyrus. This was apparent on the T2-weighted (T2W) images (figure 1), diffusion-weighted imaging (figure 2) and fluid-attenuated inversion recovery (figure 3). They were in the territory of the posterior choroidal artery. Scans of the cervical arteries, echocardiogram and 48-hour Holter monitor showed no obvious cause for an embolic stroke. His cholesterol was 6 mmol/L; low-density lipoprotein, 3.6 mmol/L; and high-density lipoprotein, 3.5 mmol/L, with normal thyroid-stimulating hormone, full blood count, renal function and liver function.

**DIFFERENTIAL DIAGNOSIS**

After discussing the symptoms, it was believed that they did not fulfil the criteria for a transient global amnesia or a seizure activity. A brain MRI scan was arranged as the diagnosis, and brain territory was not clear from the history. The sudden onset of symptoms raised the possibility of a vascular event, together with the impaired language skills without a change in his behaviour or level of consciousness.

**TREATMENT**

This man was duly started on secondary prevention measures for ischaemic strokes, which included perindopril, simvastatin and clopidogrel.

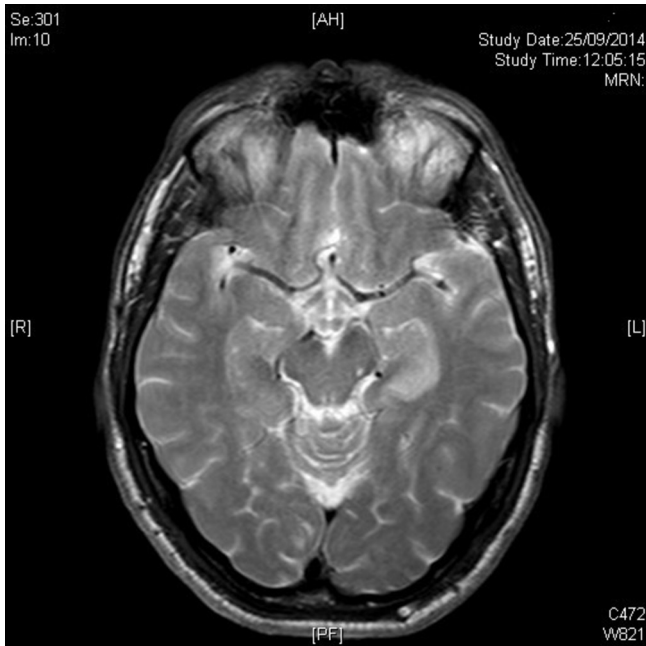
**OUTCOME AND FOLLOW-UP**

He was discharged from hospital as all his symptoms resolved by the following day when seen in the TIA clinic. He remained well with no further symptoms on follow-up 4 weeks later.



CrossMark

**To cite:** Hassan H, Ehsanula H, Pattanshetti M. *BMJ Case Rep* Published Online First: [please include Day Month Year]. doi:10.1136/bcr-2015-214184



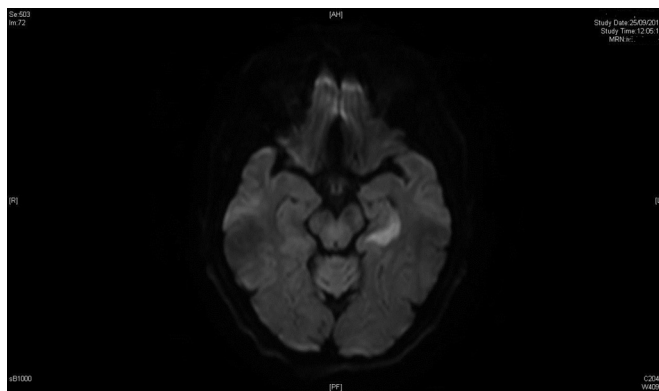
**Figure 1** T2-weighted MRI brain showing inferiomedial left temporal lobe ischaemia.

**DISCUSSION**

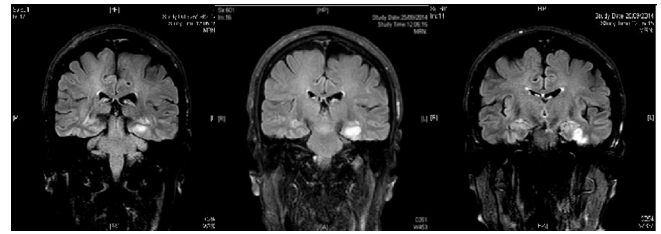
Speech and language mapping in the brain has been studied extensively in patients with dysfunction of the temporal lobes due to epilepsy or structural damage in this area due to trauma or vascular causes such as stroke. Cognition disturbance also has a significant impact on processing speech and functional MRI has recently contributed significantly to our understanding of the function of the inferiomedial temporal lobes.<sup>1-4</sup>

To date, our understanding of the fusiform gyrus confirms its contribution in visual perception and recognition. The middle and posterior parts are mostly involved in word recognition, and impairment in this area causes alexia (inability to read) and word agnosia.<sup>5,6</sup> The left fusiform gyrus is also involved in global aphasia with loss of repetition, agraphia (inability to write) and alexia.<sup>7,8</sup> However, the right fusiform gyrus, mainly mid and posterior parts, is involved in facial recognition, and their functional impairment causes prosopagnosia (loss of facial recognition).<sup>9</sup>

On the other hand, anomia (inability to name objects) localises to the inferior temporal gyrus and/or parahippocampus.<sup>2</sup>



**Figure 2** Diffusion-weighted image showing the acute infarction in the left inferiomedial temporal lobe.



**Figure 3** T2 fluid-attenuated inversion recovery showing the infarction in the left middle and anterior fusiform gyrus and the parahippocampal gyrus.

In cases with alexia and agraphia, it was noticed that when there was anomia, the lesion extended laterally to the anterior part of the middle temporal gyrus or medially toward the parahippocampus.<sup>10</sup> Therefore, anomia can be the result of any disruption affecting the interconnection between the lateral temporal surface and the inferiomedial aspect of the lobe. This disruption is commonly caused by a vascular event and less frequently by other causes such as epilepsy and neurodegeneration.<sup>11</sup>

In our case, we were intrigued to find that retrieval of numbers seemed to be intact. This led us to understand that processing numbers and the meaning of words involve different pathways or lateralisation. That of words involves the parahippocampus (causing the anomia in this patient) and the fusiform gyrus (leading to word agnosia in this patient). However, processing numbers is related to the parietal lobes.<sup>12</sup> Human cognition and language apply logic and arithmetic constantly involving complex symbolic, non-symbolic and numerical sequence retrievals and processing.<sup>4,13</sup> Recall of numerical sequence and calculation is used in cognitive assessments, and we think that incorporating it in clinical assessments may help to predict the cognitive outcome in diseases such as stroke. In our case, the numerical processing and sequence retrieval were intact, and he had full cognitive recovery.

**Learning points**

- ▶ MRI diffusion-weighted imaging is a crucial investigative tool and should be readily available to transient ischaemic attack (TIA) clinics and acute stroke services. CT brain is mostly useful in cases of haemorrhagic strokes.
- ▶ This case shows the role of the left parahippocampus and fusiform gyrus in processing language.
- ▶ Both anterior and posterior choroidal artery territory ischaemic events are often thrombotic and not embolic.
- ▶ Disturbed language skill without a global brain dysfunction is a reliable clinical sign of a structural brain lesion (included in one of the cortical signs of strokes or TIAs).
- ▶ Always think of a vascular event when faced with an acute neurological deficit.

**Acknowledgements** The authors thank Dr Anthony Kenton and Dr Don Sims who helped with editing the text and reviewing the content of this case report.

**Contributors** This case was assessed and managed by all the three contributors. We all participated in the clinical assessment, investigations and delivering the health care to the patient. We also consulted with each other when reporting this case, as we found it unique and very elusive in the way it presented. This is an original case, and after extensive literature research, we decided to report it to share our knowledge and understanding in order to improve the care given to stroke and TIA sufferers.

**Competing interests** None declared.

**Patient consent** Obtained.

**Provenance and peer review** Not commissioned; externally peer reviewed.

© BMJ Publishing Group Ltd (unless otherwise stated in the text of the article) . All rights reserved. No commercial use is permitted unless otherwise expressly granted.

## REFERENCES

- 1 Trebouchon A, Mcgonigal A, Gavaret M, *et al.* Spectrum of ictal aphasia in temporal lobe epilepsy. *Epilepsia* 2011;52:0013–9580.
- 2 Lüders H, Lesser RP, Hahn J, *et al.* Basal temporal language area demonstrated by electrical stimulation. *Neurology* 1986;36:505–10.
- 3 Gauthier I, Tarr MJ, Anderson AW, *et al.* Activation of the middle fusiform 'face area' increases with expertise in recognizing novel objects. *Nat Neurosci* 1999;2:568–73.
- 4 Holloway ID, Price GR, Ansari D. Common and segregated neural pathways for the processing of symbolic and non-symbolic numerical magnitude: an fMRI study. *Neuroimage* 2010;1:1006–17.
- 5 Ulbricht D. Pure Alexia: on two cases with unusual lesions cerebrovascular diseases. 2010;29:1015–9770.
- 6 Philipose LE, Gottesman RF, Newhart M, *et al.* Neural regions essential for reading and spelling of words and pseudowords. *Ann Neurol* 2007;5:481–492.
- 7 Sakurai Y, Sakai K, Sakuta M, *et al.* Naming difficulties in alexia with agraphia for kanji after a left posterior inferior temporal lesion. *J Neurol Neurosurg Psychiatry* 1994;57:609–13.
- 8 Usui K. Basal temporal language area. *Clin Neurophysiol* 2010;2457:1388.
- 9 Weibert K, Andrews TJ. Activity in the right fusiform face area predicts the behavioural advantage for the perception of familiar faces. *Neuropsychologia* 2015;75:588–96.
- 10 Sharp DJ, Scott SK, Wise RJS. Retrieving meaning after temporal lobe infarction: the role of the basal language area. *Ann Neurol* 2004;6:836–46.
- 11 Morais R, Duro D, Parra J, *et al.* Prosopagnosia in FDT: case report Felix. *Dement Geriatr Cogn Disord* 2012;34:1420–8008.
- 12 Keller K, Menon V. Gender differences in the functional and structural neuroanatomy of mathematical cognition. *Neuroimage* 2009;47:342–52.
- 13 Gitelman DR. Acaculia: a disorder of numerical cognition. D'Esposito M, *Neurological foundations of cognitive neuroscience*. Cambridge: MIT Press, 2003:129–63.

Copyright 2017 BMJ Publishing Group. All rights reserved. For permission to reuse any of this content visit <http://group.bmj.com/group/rights-licensing/permissions>.

BMJ Case Report Fellows may re-use this article for personal use and teaching without any further permission.

Become a Fellow of BMJ Case Reports today and you can:

- ▶ Submit as many cases as you like
- ▶ Enjoy fast sympathetic peer review and rapid publication of accepted articles
- ▶ Access all the published articles
- ▶ Re-use any of the published material for personal use and teaching without further permission

For information on Institutional Fellowships contact [consortiasales@bmjgroup.com](mailto:consortiasales@bmjgroup.com)

Visit [casereports.bmj.com](http://casereports.bmj.com) for more articles like this and to become a Fellow