

Pre-eclampsia and acute pulmonary embolism—the importance of making a differential diagnosis: a case report

R. Suthar¹ · S. Abdelfattah¹ · H. Goldman¹ · G. Garcia¹ · D. Romero-Fischmann¹ · M. Escobar² · V. Behrens¹

Received: 9 March 2017 / Accepted: 26 July 2017
© Japanese Society of Anesthesiologists 2017

Abstract We describe the case of a 41-year-old pregnant patient who presented at 38 weeks of gestation for an urgent cesarean section, with new onset of pre-eclampsia as the initial diagnosis. The intraoperative course was complicated by seizures and hemodynamic collapse. Initially, the presentation of seizure pointed to pre-eclampsia/eclampsia; however, with careful consideration of each event as it occurred, the correct diagnosis was later determined to be pulmonary embolism and stroke. This case illustrates the importance of considering multiple possible etiologies, even when a particular diagnosis seems obvious.

Keywords Pre-eclampsia · Pulmonary embolism · Stroke

✉ R. Suthar
rekhasuthar.md@gmail.com

S. Abdelfattah
Sarah.r.abdelfattah@gmail.com

H. Goldman
howardg264@aol.com

G. Garcia
bgarcia28@aol.com

D. Romero-Fischmann
Darofi72@gmail.com

M. Escobar
Mauricioe@sanjuanbautista.edu

V. Behrens
vbehrens@fiu.edu

¹ Department of Anesthesiology, Mount Sinai Medical Center, Miami Beach Anesthesiology Associates, Inc., 4300 Alton Road, Miami Beach, FL 33140, USA

² San Juan Bautista School of Medicine, San Juan, Puerto Rico

Introduction

Pre-eclampsia is the third leading cause of peripartum maternal morbidity and mortality in the USA [1]. It is a multi-organ disease process that occurs in up to 5–8% of pregnancies after 20 weeks gestation [2], and it has a broad spectrum of associated signs and symptoms. The clinical dilemma is that there are a plethora of conditions with similar presentations. Patients presenting with seizure and a known history of pre-eclampsia still require a differential diagnosis, especially if other complications occur, such as hemodynamic collapse. As perioperative physicians, anesthesiologists need to take a leading role and develop preoperative, intraoperative, and postoperative treatment plans, keeping an open mind to all applicable differential diagnoses. Our case presentation will outline the sequence of events, laboratory work, and imaging that led to the correct diagnosis and treatment.

Consent for publication

Written consent for publication was obtained from the patient.

Case description

A 41-year-old female, 38 weeks of gestation (gravida 2, para 1), with a past medical history of migraines and anemia, presented to her obstetrician's office complaining of a headache. She was found to be hypertensive [blood pressure (BP): 167/83 mmHg] and subsequently was booked for an urgent cesarean section with the diagnosis of pre-eclampsia. As there were no contraindications to neuraxial anesthesia, we decided to perform a spinal anesthetic. Standard ASA monitors were used throughout the procedure. Vitals signs

before the spinal anesthesia were: BP 140/79 mmHg, heart rate 78 bpm, oxygen saturation 99% on room air. The L4–L5 interspace was identified and, using a midline approach with the patient in sitting position, a 25-gauge 10-cm Whitacre needle was advanced until clear free flow of cerebrospinal fluid was seen. Hyperbaric bupivacaine 0.75% (10.5 mg), 15 µg of fentanyl and 0.3 mg of morphine were injected into the subarachnoid space. After obtaining and confirming an adequate anesthetic level up to T4, the patient underwent a cesarean section.

Immediately after successful delivery of the baby, the patient suddenly developed a tonic–clonic seizure, requiring immediate intubation for airway protection and ventilation. Concomitantly, the patient developed unstable ventricular tachycardia (up to 160 bpm) demanding initiation of Advanced Cardiovascular Life Support (ACLS) protocol, including shock, chest compressions and epinephrine. A left radial arterial line and a right femoral central line were placed. An infusion of magnesium sulfate ($MgSO_4$) was also started. She subsequently went into pulseless electrical activity for 1 min, which was treated with chest compressions and epinephrine before sinus rhythm and normal blood pressure were re-established. The patient was transferred to the intensive care unit (ICU).

In the ICU, the patient responded well to resuscitation efforts, which included crystalloids, colloids, and vasopressors. Empiric antibiotics were started for possible sepsis.

Cardiac workup showed elevated serum troponin I level (6.6 ng/ml). The electrocardiogram (EKG) showed a right bundle branch block (RBBB) and right ventricular strain pattern, without ST elevations (Fig. 1). Two-dimensional transthoracic echocardiogram (TTE) revealed a mild increase in right ventricle size, normal ejection fraction 65–70%, and a small thin thrombus attached to the ventricular side of the tricuspid valve. Lower extremity ultrasound was negative for any deep venous thrombosis. This could be due to complete dislodgement of thrombus because of the sequential compression device for mechanical deep vein thrombosis prophylaxis which was used intraoperatively, or false-negative venous duplex. The patient was started on intravenous heparin, and a computed tomography angiogram (CTA) of the chest was obtained. The CTA report described a saddle pulmonary embolus, with extensive bilateral emboli extending throughout the left and right main pulmonary arteries into lobar and proximal segmental branches (Fig. 2a–d). There were also signs of right heart strain and bulging of the fossa ovalis into the left atrium.

Interventional radiology administered an intrapulmonary artery thrombolytic (Alteplase) infusion. Because of the patient's extreme agitation and difficulty in appropriately comprehending verbal commands, we began to suspect cerebrovascular pathology. CT scan of the brain confirmed our suspicions, which revealed a 1.7-cm left middle cerebral artery territory infarct. No thrombus was found in

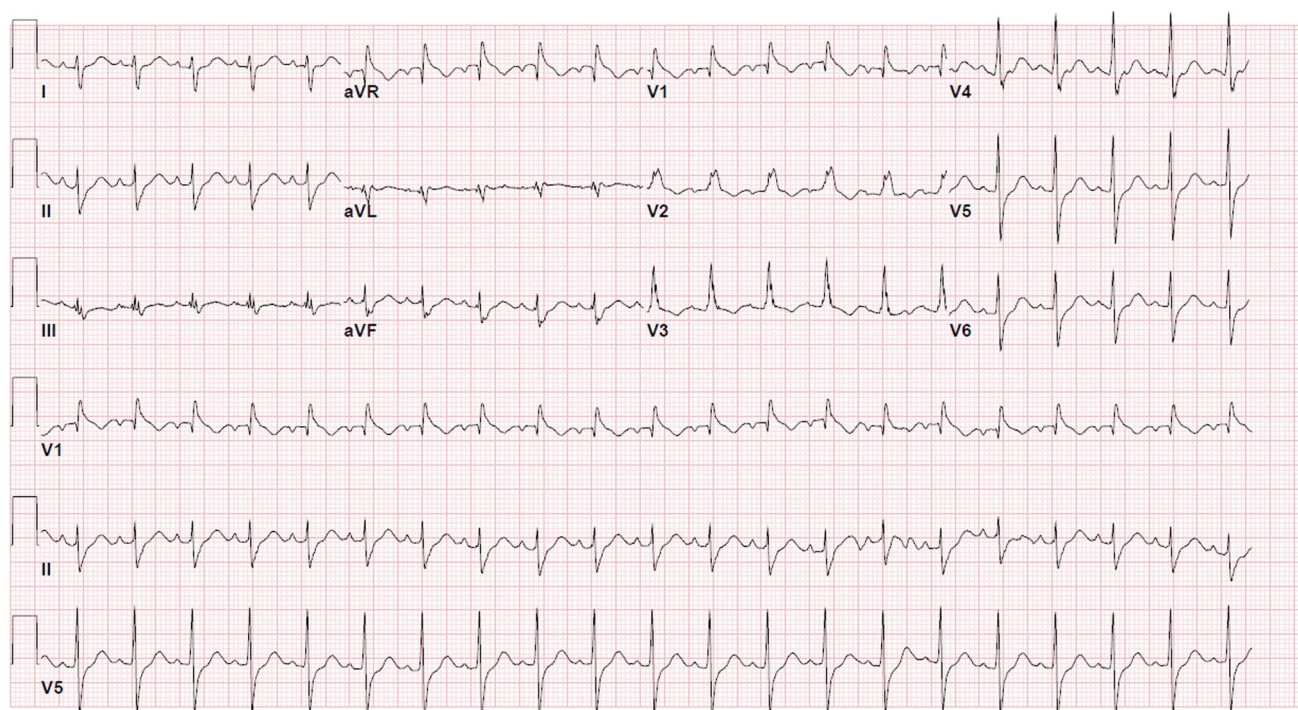


Fig. 1 EKG showing sinus tachycardia and RBBB-prolonged QRS in right-sided and septal leads

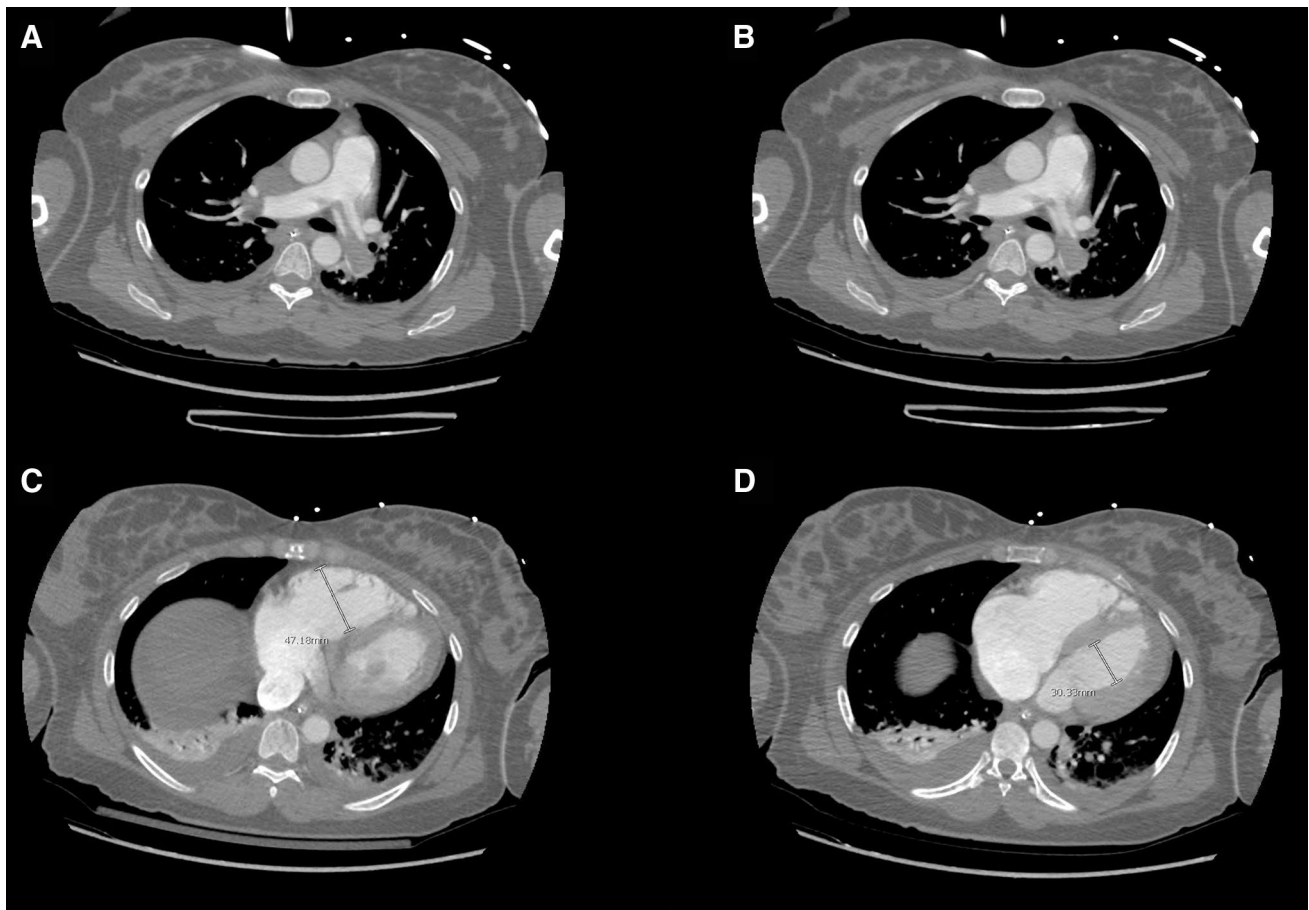


Fig. 2 Computed tomographic angiogram of the chest: **a** saddle embolism, **b** emboli extending to lobar arteries, **c** right ventricle strain, right ventricle measuring 47.18 mm, **d** left ventricle measuring 30.33 mm

the inferior vena cava (IVC) and an IVC filter was inserted. Finally, transesophageal echocardiography (TEE) showed a small patent foramen ovale (PFO), which may have been the risk factor which caused the cerebrovascular accident (CVA). Hypercoagulability (Factor V Leiden mutation, lupus anticoagulant, protein C and S activity, prothrombin-II mutation) workup was negative. Over the next 2 weeks, the patient's status improved with aggressive critical and rehabilitation care. She was discharged home without any residual defects on postoperative day 32.

Discussion

In clinical practice, the classic textbook presentations of pre-eclampsia (hypertension, with concomitant proteinuria or headache/visual disturbance/right upper quadrant pain, etc.) are not always the case. Multiple clinical conditions share similar symptoms, often making it hard to form a single conclusion, which demands a multidisciplinary approach to the care of critically ill patients.

Pre-eclampsia is a leading cause of peripartum morbidity and mortality due to intracranial hemorrhage, cerebral infarction, acute pulmonary edema, respiratory failure, hepatic failure and rupture, etc. [2, 3]. The underlying lesion is uteroplacental insufficiency and systemic disruption of the endothelium [2]. Early recognition and intervention are essential to prevent the development of eclampsia. In our patient, the diagnosis of pre-eclampsia was made using The American College of Obstetricians and Gynecologists (ACOG) criteria 2013 with systolic blood pressure ≥ 160 mmHg associated with headaches, a form of cerebral disturbance [3]. However, it was the subsequent clinical course that led to the discovery of entities other than eclampsia.

All complications, no matter how straightforward, deserve some thought to the differential diagnosis. For example, the presentation of seizures in our patient "labeled" her as eclamptic and led us to focus on the management of that entity. Although eclampsia is one of the most frequent causes of seizures during pregnancy, other causes of seizures must be excluded. In non-epileptic

pregnant patients, causes of seizures include structural and metabolic changes. Structural causes include CVA (intracranial hemorrhage or infarction) and eclampsia. Metabolic causes include but are not limited to hyperemesis gravidarum, acute hepatitis, metabolic diseases or infection [4]. There was a cascade of different events suggesting the possibilities of other diagnoses beyond pre-eclampsia/eclampsia. Seizure was followed by hemodynamic collapse which was managed by ACLS protocol. The patient's intra-operative arterial blood gas showed respiratory acidosis (pH 7.21 and PCO₂ 83 mmHg, PO₂ 337 mmHg), which was attributed to her seizure.

In retrospect, because the patient was adequately mechanically ventilated, her hypercarbia deserved other explanations. Her respiratory acidosis was most likely due to the increased dead space associated with pulmonary embolism. Similarly, her seizure was probably due to the acute left frontal lobe infarction which was diagnosed on post-operative day one. Indeed, the TEE finding of a PFO was more than an incidental discovery: the small right-to-left shunt could have allowed microthrombi to cause the CVA. Studies have shown an association between PFO and cerebral embolism [5, 6]. An anatomically patent, non-functioning foramen ovale occurs in 5–10% of the general population, and in patients with cerebral infarction, fifty percent have a PFO [7]. Pregnancy itself is associated with hypercoagulability, a fivefold increased risk of venous thromboembolism, and a 13-fold higher risk of stroke as compared to non-pregnant women [8]. The hypercoagulable state is ascribed to several physiological alterations of pregnancy, including changes in the hemostatic system, mechanical obstruction by an enlarged uterus, hormonally induced venous stasis, and vascular injury to pelvic vessels during delivery [9].

Other cases have been reported in which seizures associated with pregnancy were initially misdiagnosed and treated as eclamptic seizures. Farzi et al. [10] presented a case of a 21-year-old primigravida with tonic-clonic seizures several hours after undergoing an emergency cesarean section. Brain magnetic resonance imaging (MRI) later showed obstruction of the cerebral venous plexus, confirming the diagnosis of cerebral venous sinus thrombosis, probably due to the hypercoagulable state in pregnancy. Aoki et al. [11] reported a 34-year-old patient in her 35th week of gestation who presented to the hospital with tonic-clonic seizures. Although hematological exams, a urine protein exam, and an elevated blood pressure of 170/90 mmHg all suggested eclamptic seizures, MRI scans revealed cerebral infarction and cerebral edema, later found to be complicated by central nervous system lupus.

Conclusion

Physicians can become fixated on one diagnostic entity and attribute all subsequent events to it. This case emphasizes the importance of careful preoperative assessment and risk stratification for each and every possible complication of a particular clinical condition. Most importantly, a broad differential diagnosis is needed when faced with symptoms or signs that do not fit the etiology that seems obvious. Modern anesthesiologists should assume the role of a perioperative physician, which includes the preoperative as well as the postoperative period. The goal is to improve patient safety and overall outcome and reduce perioperative morbidity and mortality.

Author contribution statement Case review: RS, Vicente Behrens. Literature review: RS. Manuscript preparation: RS, SA, VB, HG, ME, GG, DR-F

Compliance with ethical standards

Source of funding None.

Conflict of interest All authors declared that they have no potential conflict of interest.

References

1. Donnelly JC, D'Alton ME. Pulmonary embolus in pregnancy. *Semin Perinatol.* 2013;37(4):225–33.
2. Turner JA. Diagnosis and management of pre-eclampsia: an update. *Int J Womens Health.* 2010;30(2):327–37.
3. James MR, Phyllis AA, George B, John RB, Ira MB, Maurice D, Robert RG, Joey PG, Arun J, Donna DJ, Ananth KS, Marshall DL, Michelle YO, George RS, Baha MS, Catherine YS, Eleni T, James NM. American College of Obstetricians and Gynecologists Staff. In: Hypertension in Pregnancy. Washington, DC: The American College of Obstetricians and Gynecologists; 2013.
4. Beach Robert L, Kaplany Peter W. Seizures in pregnancy: diagnosis and management. *Int Rev Neurobiol.* 2008;83:259–71.
5. Donaldson JO, Lee NS. Arterial and venous stroke associated with pregnancy. *Neurol Clin.* 1994;12(3):583–99.
6. Webster MW, Chancellor AM, Smith HJ, Swift DL, Sharpe DN, Bass NM, Glasgow GL. Patent foramen ovale in young stroke patients. *Lancet.* 1988;2(8601):11–2.
7. Hart LA, Sibai BM. Seizures in pregnancy: epilepsy, eclampsia, and stroke. *Semin Perinatol.* 2013;37(4):207–24.
8. James AH. Pregnancy-associated thrombosis. *Hematol Am Soc Hematol Educ Progr.* 2009;2009:277–85.
9. Stone SE, Morris TA. Pulmonary embolism during and after pregnancy. *Crit Care Med.* 2005;33(10 suppl):S294–300.
10. Farzi F, Abdollahzadeh M, Faraji R, Chavoushi T. Seizure in pregnancy following cerebral venous sinus thrombosis. *Anesthesiol Pain Med.* 2015;5(3):e26866.
11. Aoki S, Kobayashi N, Mochimaru A, Takahashi T, Hirahara F. Seizures associated with lupus during pregnancy. *Clin Case Rep.* 2016;4(4):366–8.