

## CASE REPORT

# Delirium as presentation of late-onset and relapsing Susac syndrome

Romain Betend,<sup>1</sup> Andrea M Humm,<sup>1,2</sup> Friedrich Medlin<sup>1,3</sup>

<sup>1</sup>Department of Internal Medicine, Unit of Neurology, HFR Fribourg Hopital Cantonal, Fribourg, Switzerland

<sup>2</sup>Department of Neurology, Inselspital Universitätsspital Bern, Bern, Switzerland

<sup>3</sup>Department of Clinical Neurosciences, Centre Hospitalier Universitaire Vaudois, Lausanne, Switzerland

## Correspondence to

Dr Romain Betend,  
romain\_betend@hotmail.com

Accepted 23 July 2017

## SUMMARY

A 67-year-old patient, only known for bilateral presbycusis, presented with subacute onset of delirium. Clinical examination showed multifocal neurological deficits, all together suggesting subcortical frontal dysfunction together with cerebellar and corpus callosum involvement.

Cerebral MRI demonstrated supratentorial and infratentorial subcortical and periventricular T2-hyperintense lesions with cerebellar gadolinium enhancement and multiple central lesions of the corpus callosum (snowball lesions). The diagnosis of Susac syndrome was made and the patient treated with intravenous methylprednisolone, followed by a prednisone maintenance dose over 8 weeks. After a clinical improvement, a relapse was noticed during corticosteroid tapering. The patient was again treated with intravenous methylprednisolone followed by a prednisone maintenance therapy with simultaneous introduction of mycophenolate mofetil acid and one cycle of intravenous rituximab. The patient recovered rapidly. At 11-month follow-up, only mild executive dysfunction and persistent right postural tremor was noted, MRI showed partial regression of subcortical and juxtacortical lesions.

seeking evaluation in the emergency department of our institution. He had a history of relevant for bilateral presbycusis, a recent episode of vertigo and transient blurred vision of the right eye.

On admission, vital signs were normal and there was no fever. A lumbar puncture was done in the emergency department and, given the results, intravenous acyclovir was empirically introduced waiting for herpes simplex virus (HSV) analysis. Neurological assessment at 48 hours after admission revealed psychomotor slowing, emotional lability, attentional deficits with temporal and spatial disorientation, marked executive and anterograde amnesic disturbances (Montreal Cognitive Assessment (MoCA) score at 14/30) as well as left ear suppression on dichotic listening test. Furthermore, right central facial palsy, left upper limb and gait ataxia, right-sided predominant postural tremor and left-sided predominant rigidity and bradykinesia of the upper limbs were noted. The clinical picture with multifocal neurological deficits suggested subcortical frontal dysfunction together with cerebellar and corpus callosum involvement.

## INVESTIGATIONS

Contrast enhanced brain CT was normal. Cerebrospinal fluid (CSF) analysis revealed a lymphocytic pleocytosis (12 leucocytes/mm<sup>3</sup>) and elevated protein (2.64 g/L). Oligoclonal bands were absent. PCR for HSV type 1 and type 2 returned negative and acyclovir was stopped. PCR for EBV was also negative. Electroencephalography showed diffuse slowing. Cerebral MRI demonstrated multiple supratentorial and infratentorial subcortical and periventricular T2-hyperintense lesions (figures 1A, B and E), with modest cerebellar gadolinium enhancement (not shown) and multiple central lesions of the corpus callosum (snowball lesions). Spinal MRI and thoracoabdominal CT scan were normal. Laboratory analysis revealed a slightly elevated erythrocyte sedimentation rate (13 mm/hour), elevated rheumatoid factor (357 U/mL), mixed non-infectious cryoglobulinaemia and modest vitamin D deficit (43 nmol/L). Routine laboratory analysis, thyroid-stimulating hormone, angiotensin converting enzyme, antinuclear antibody, lupus anticoagulant, protein electrophoresis, anti-NMO antibodies titre and testing for Lyme, HIV, hepatitis C and tuberculosis were negative.

Retinal fluorescein angiography (RFA) showed BRAO (figure 1G and figure 1H) and tone audiometry revealed bilateral, left predominant pantonal SNHL (figure 1I).

## BACKGROUND

We report a well-documented case of Susac syndrome, which is a rare, and probably under recognised disease. The diagnosis was suggested given the full clinical triad of subacute encephalopathy, multiple branch retinal arterial occlusions (BRAOs) and bilateral sensorineural hearing deficits (SNHL), together with the presence of characteristic snowball lesions of the corpus callosum on MRI. The full clinical triad is uncommon at disease onset and therefore missing components should be screened for when diagnosis is suspected.

Treatment for Susac syndrome is empiric with corticosteroids and immunosuppressive therapy. We noticed a relapse during prednisone tapering, highlighting the importance of early-sustained aggressive and multimodal immunosuppressive therapy.

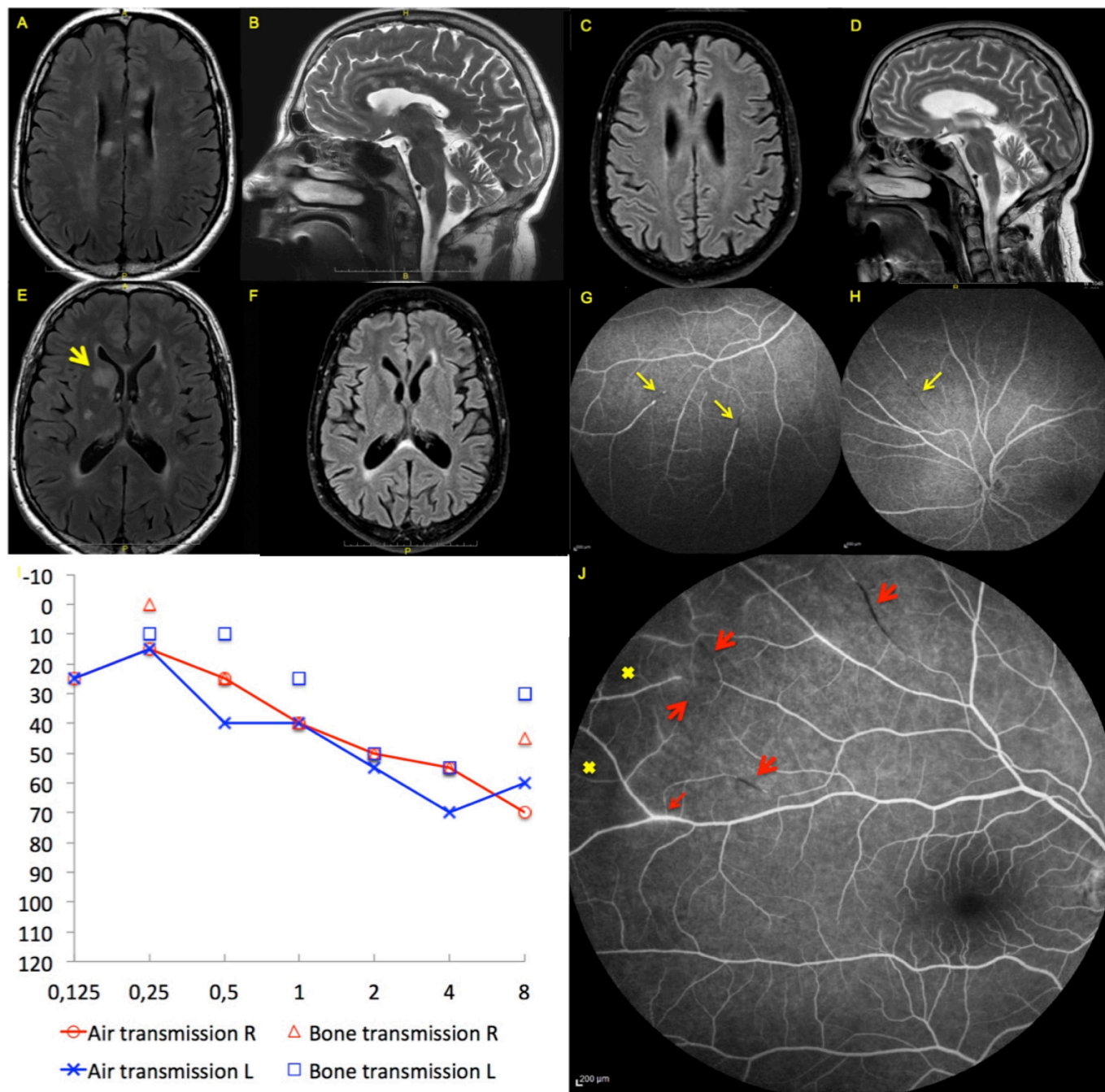
## CASE PRESENTATION

A 67-year-old retired teacher was hospitalised in our institution for subacute onset of delirium with initial suspicion of meningoencephalitis. His wife noticed a progressive deterioration over 2 months characterised by cognitive decline with behaviour disturbance followed by a delirium with visual hallucinations



CrossMark

**To cite:** Betend R, Humm AM, Medlin F. *BMJ Case Rep* Published Online First: [please include Day Month Year]. doi:10.1136/bcr-2017-220494



**Figure 1** Composite figure showing fluid-attenuated inversion recovery T2 axial (A, C, E and F) and sagittal T2 (B and D) cranial MRI at presentation (A, B and E) and at 11 months (C, D and F). (A), (B) and (E) show diffuse subcortical white and grey matter lesions and characteristic lesions of the corpus callosum (snowball lesions) and one right caudate nucleus lesion (large yellow arrow). (G) and (H) are retinal fluorescein angiography at presentation. Thin yellow arrows show multiples branch retinal arterial occlusions (BRAOs) on the right (G) and left (H) eyes. (I) is the tone audiometry at presentation. Left ear is depicted in blue, right ear in red. Horizontal axis shows the frequency in kilohertz, vertical axis show the decibel level at which the frequency is perceived. (J) is RFA at 3 months (right eye) demonstrating zones of focal ischaemia (cross), new BRAOs (large arrows) and leakages (thin arrow).

## DIFFERENTIAL DIAGNOSIS

The clinical presentation fulfilling the diagnostic criteria for Susac syndrome with all components of the clinical triad together with the pathognomonic snowball lesions on MRI narrows the differential diagnosis and leded straightforward to the diagnosis.<sup>1</sup> Still, important differential diagnosis include multiple sclerosis, acute disseminated encephalomyelitis (ADEM), neurosarcoidosis, primary cerebral nervous

system lymphoma (PCNSL) and primary angiitis of the central nervous system (PACNS).

In the presented case, clinical history lacking prior vaccination or infection before clinical onset, the older age and the relapsing course argue against ADEM.

Likewise, age at onset, the lesion pattern on MRI with characteristic snowball lesions and multifocal lesions involving both white and grey matter, the absence of oligoclonal bands and the

high protein level in CSF make the diagnosis of multiple sclerosis unlikely.

Absence of systemic symptoms, meningeal or orbital involvement without signs of uveitis or chorioretinitis, the normal thoracoabdominal CT scan, normal ACE assay argue against neurosarcoidosis. Furthermore, BRAOs are usually not seen in neurosarcoidosis neither in multiple sclerosis.

Again, absence of systemic symptoms and leptomeningeal involvement, the results of CSF analysis including negative PCR for EBV and finally the above-mentioned lesion pattern on MRI lowers the likelihood for PCNSL. Hence, a stereotaxic biopsy was not performed.

Finally, PACNS or systemic vasculitis with CNS involvement as challenging differential diagnoses have been initially considered but were ruled out mainly because of the absence of distal vasculopathy on CT/MRI angiography, and once more the characteristic snowball lesions of the corpus callosum.

## TREATMENT

Consequently, the patient was treated with intravenous methylprednisolone 1g/day for 3 days, followed by a prednisone maintenance dose (1mg/kg) over 8 weeks. Aspirin was also added.

## OUTCOME AND FOLLOW-UP

His cognitive functions improved rapidly and at 6-week follow-up, he remained stable with moderate executive dysfunction as assessed by comprehensive neuropsychological testing (MoCA score at 20/30), without new lesions and no contrast enhancement on brain MRI. Neurological status was unchanged. Given the favourable clinical and radiological course as well as important steroid side effects (insomnia, impulsivity, glucose intolerance due to weight gain), corticosteroids were further tapered and stopped 3 months after onset. Two-weeks later, he was rehospitalised for delirium with psychotic decompensation and visual hallucinations requiring transient administration of atypical neuroleptics (haloperidol and olanzapine). Clinical examination at this time did not reveal new focal neurological signs. However, brain MRI showed new subcortical and callosal T2-hyperintense lesions without contrast enhancement. Audiometry was repeated, showing a pronounced pantonal bilateral hearing deficit. RFA demonstrated new BRAOs with zones of focal ischaemia and vascular leakages (figure 1J), whereas repeated CSF analysis showed mild neutrophilic pleocytosis (19 leucocytes/mm<sup>3</sup>) and still elevated protein (1.64 g/L).

Intravenous methylprednisolone 500mg/day was repeated for 3 days, followed by a prednisone maintenance therapy (1mg/kg) with simultaneous introduction of mycophenolate mofetil acid and administration of one cycle of intravenous rituximab (2×1g at the 14-days interval). The patient recovered rapidly from delirium. At 11-months follow-up, only mild executive dysfunction (MoCA score at 26/30) and persistent right postural tremor was noted, MRI showed partial regression of subcortical and juxtacortical lesions (figure 1F).

## DISCUSSION

Susac syndrome is a rare disease characterised by the clinical triad of encephalopathy, BRAO and SNHL. Until today, as few as 304 cases with Susac syndrome were reported in the literature.<sup>2</sup> It affects preferentially young women in their 20s or 30s at disease onset with disease onset between 8 and 65 years having been reported, but to our knowledge, this is the

## Learning points

- ▶ Susac syndrome is a rare and probably under recognised disease. Given the fact that the full clinical triad is uncommon at disease onset, missing components should be actively screened for.
- ▶ The presence of snowball lesions on MRI in a patient with encephalopathy is highly suggestive of Susac syndrome.
- ▶ Until today, there is no diagnostic blood analysis to confirm Susac syndrome. The exact pathophysiological role of anti-endothelial cell antibodies is still unknown.
- ▶ Empirical treatment for Susac syndrome is mainly based on long-term corticosteroid and immunosuppressive therapy and requires close clinical follow-up when tapering because of the risk of relapse.

first report with a disease onset beyond 65 years.<sup>2</sup> The most common manifestation at disease onset is encephalopathy but importantly, the presence of the full clinical triad at disease onset is uncommon and present in only about a quarter of patients, underlining the need to screen for all components by MRI, RFA and audiometry, as illustrated in this case.<sup>2,3</sup> The presence of snowball lesions in an patient with encephalopathy is highly suggestive of Susac syndrome and should hasten a search for BRAO and SNHL.<sup>4</sup> These are small corpus callosum lesions (3–7 mm) involving more frequently the central fibres, that look like snowballs on sagittal T2 and fluid-attenuated inversion recovery sequences.<sup>5,6</sup>

The exact pathophysiological mechanisms of the disease are still unclear, but an immune-mediated inflammatory endotheliopathy seems to be a key element, causing micro infarcts of brain, retina and inner ear and sharing histologically similarities with juvenile dermatomyositis. In Susac syndrome, complement activating antiendothelial cell antibodies (AECA) are inconsistently found, although its exact pathophysiological role needs to be further addressed.<sup>3,7</sup> Unfortunately, testing for AECA was not available in our institution. Interestingly, our patient had non-infectious mixed cryoglobulinaemia that might argue for a cryoglobulinaemia vasculitis. However, the lack of association with malignant haemopathy or systemic connective tissue disorder makes this assumption in our opinion less likely.

Treatment recommendations for Susac syndrome are empiric, but there is agreement for early, high dose corticosteroid therapy and sustained multimodal immunosuppressive therapy as well as intravenous immunoglobulin as first-line treatment. Plasmapheresis and alternative drugs such as rituximab are mostly proposed in refractory cases.<sup>8</sup> Aspirin is frequently added to reduce procoagulopathic state and is recommended by some authors.<sup>9</sup>

In conclusion, we report a well-documented and relapsing case of late-onset Susac syndrome successfully treated with multimodal immunosuppressive therapy. We noticed an acute relapse due to rapid tapering of corticoids emphasising the importance for a close clinical follow-up and if necessary an aggressive and sustained immunosuppression.

**Acknowledgements** Beknazar E., Chouiter L., Colombo-Thuillard F., Hennion D.

**Contributors** RB: Study concept and design, analysis and interpretation of data, drafting of the manuscript. AMH: Critical revision of the manuscript. FM: Study concept and design, data collection and interpretation, drafting and critical revision of the manuscript, supervised the study.

**Competing interests** None declared.

**Patient consent** Obtained.

**Provenance and peer review** Not commissioned; externally peer reviewed.

© BMJ Publishing Group Ltd (unless otherwise stated in the text of the article) 2017. All rights reserved. No commercial use is permitted unless otherwise expressly granted.

## REFERENCES

- 1 Kleffner I, Dörr J, Ringelstein M, *et al*. European Susac Consortium (EuSaC). Diagnostic criteria for Susac syndrome. *J Neurol Neurosurg Psychiatry* 2016;87:jnnp-2016-314295.
- 2 Dörr J, Krautwald S, Wildemann B, *et al*. Characteristics of Susac syndrome: a review of all reported cases. *Nat Rev Neurol* 2013;9:307–16.
- 3 Greco A, De Virgilio A, Gallo A, *et al*. Susac's syndrome--pathogenesis, clinical variants and treatment approaches. *Autoimmun Rev* 2014;13:814–21.
- 4 Rennebohm R, Susac JO, Egan RA, *et al*. Susac's Syndrome — Update. *J Neurol Sci* 2010;299:86–91.
- 5 Susac JO, Murtagh FR, Egan RA, *et al*. MRI findings in Susac's syndrome. *Neurology* 2003;61:1783–7.
- 6 Garg N, Reddel SW, Miller DH, *et al*. The corpus callosum in the diagnosis of multiple sclerosis and other CNS demyelinating and inflammatory diseases. *JNNP* 2015;86:1374–82.
- 7 Jarius S, Kleffner I, Dörr JM, *et al*. Clinical, paraclinical and serological findings in Susac syndrome: an international multicenter study. *J Neuroinflammation* 2014;11:46.
- 8 García-Carrasco M, Mendoza-Pinto C, Cervera R. Diagnosis and classification of Susac syndrome. *Autoimmun Rev* 2014;13:347–50.
- 9 Kleffner I, Duning T, Lohmann H, *et al*. A brief review of Susac syndrome. *J Neurol Sci* 2012;322:35–40.

Copyright 2017 BMJ Publishing Group. All rights reserved. For permission to reuse any of this content visit <http://group.bmj.com/group/rights-licensing/permissions>.  
BMJ Case Report Fellows may re-use this article for personal use and teaching without any further permission.

Become a Fellow of BMJ Case Reports today and you can:

- Submit as many cases as you like
- Enjoy fast sympathetic peer review and rapid publication of accepted articles
- Access all the published articles
- Re-use any of the published material for personal use and teaching without further permission

For information on Institutional Fellowships contact [consortiasales@bmjgroup.com](mailto:consortiasales@bmjgroup.com)

Visit [casereports.bmj.com](http://casereports.bmj.com) for more articles like this and to become a Fellow