

A Case of Lenticulostriate Stroke Due to Minor Closed Head Injury in a 2-Year-Old Child

Role of Mineralizing Angiopathy

Emin Fidan, MD,* Dana D. Cummings, MD, PhD,† and Mioara D. Manole, MD‡

Objective: Cerebral infarction due to minor head injury is rare. Mineralizing angiopathy is considered a predisposing factor for lenticulostriate stroke after minor closed head injury. This entity is characterized by infarction of the basal ganglia and most often occurs in young children, from infancy to 2 years of age. Symptoms usually occur immediately after the injury.

Methods and Results: We present the case of a previously healthy 2-year-old female child presenting with right facial hemiparesis and aphasia, along with right arm and leg weakness that occurred immediately after a fall from the couch onto a carpeted floor. A brain computed tomography scan revealed small and linear calcifications of the basal ganglia and subcortical frontoparietal area, in the absence of signs of intracranial hemorrhage. Brain magnetic resonance imaging with stroke protocol revealed restriction of water diffusion in the left basal ganglia on diffusion-weighted imaging sequences as well as apparent diffusion coefficient sequences, suggesting an acute infarct of the left basal ganglia within the distribution of the lenticulostriate vessels. The patient was treated with aspirin and conservative management and had gradual improvement over the next few days, with full recovery of the aphasia, facial nerve function, and arm and leg mobility, within 2 months.

Conclusions: Some infants can present with the onset of stroke-like symptoms after minor head injuries. Presence of linear calcifications of the basal ganglia noticed on brain computed tomography in many of these patients suggests that mineralizing angiopathy may be a predisposing factor for lenticulostriate stroke after minor closed head injury in infants. Brain magnetic resonance imaging to further delineate possible cerebral infarction is indicated.

Key Words: concussion, mineralizing angiopathy, stroke

(*Pediatr Emer Care* 2017;00: 00–00)

Each year, almost half a million children experience traumatic brain injury in the United States, with 80% having mild closed head injury (CHI).^{1,2} Most of the patients with mild CHI have an uneventful course.³ A rare complication of mild pediatric CHI occurring in some infants is infarction of the basal ganglia.^{4–6} Mineralizing angiopathy of lenticulostriate arteries is postulated to be a risk factor for infarction of the basal ganglia after mild CHI.⁶ We present a case of a 2-year-old female child who developed hemiparesis just minutes after a mild CHI. We describe the clinical and radiological features of this case and review the predisposing factors, pathophysiology, and clinical evaluation of lenticulostriate strokes occurring after CHI.

From the Divisions of *Pediatric Critical Care Medicine, †Child Neurology, and ‡Pediatric Emergency Medicine, Children's Hospital of Pittsburgh of University of Pittsburgh Medical Center, Pittsburgh, PA.

Disclosure: The authors declare no conflict of interest.

Reprints: Mioara D. Manole, MD, Division of Pediatric Emergency Medicine, Children's Hospital of Pittsburgh of University of Pittsburgh Medical Center, 4401 Penn Ave, Pittsburgh, PA 15224 (e-mail: manomd@upmc.edu).

Copyright © 2017 Wolters Kluwer Health, Inc. All rights reserved.

ISSN: 0749-5161

CASE

A previously healthy 2-year-old female child presented to our emergency department for evaluation of acute facial droop, inability to speak, and gait abnormality, which developed within 3 to 5 minutes after a fall. Parents reported that the patient fell off a couch onto a carpeted floor, hitting her occipital area. She had no loss of consciousness and no emesis; she cried immediately. Shortly after the fall, the parents noticed that the patient had a facial droop and was less active than usual; she had a language disturbance consistent with aphasia; she communicated by crying and grunting. She continued to ambulate and was active. She was initially evaluated at an urgent care center, where she was assessed as being a neurologically intact 2-year-old child; however, she was transferred to our tertiary care center at mother's request. Initial physical examination at our hospital 90 minutes after the event showed an awake and alert patient. She was able to follow commands, but she was not communicating verbally. Neurological examination was positive for right-sided facial weakness limited to the lower half of the face, associated with slight drooling. Cranial nerve function was otherwise intact. Right hemiparesis was noted. Strength was 3/5, tone was decreased, but muscle mass was normal. Deep tendon reflexes were absent in the right upper and lower extremity, but they were normal in the left upper and lower extremity. Plantar reflexes were absent on the right side and downgoing on the left side. Sensation was grossly intact. Her gait was wide based, hemiparetic, but without ataxia.

A computed tomography (CT) scan of the brain obtained in the emergency department revealed small bilateral calcifications of the basal ganglia (Fig. 1A), as well as small calcium deposition over the left frontoparietal area, without signs of intracranial hemorrhage or any obvious hypoattenuation suggesting ischemic infarct. Brain magnetic resonance imaging (MRI) with stroke protocol revealed restriction of diffusion in the left basal ganglia with apparent diffusion coefficient correlate, suggesting an acute infarct in the area of the basal ganglia within the distribution of the lenticulostriate vessels (Fig. 1B). Magnetic resonance spectroscopy demonstrated elevated lactate in the left basal ganglia, without definite evidence of elevation of lactate in the contralateral basal ganglia. Laboratory evaluation obtained to exclude hematological, metabolic, or infectious causes was normal, including the following: complete blood count, comprehensive metabolic panel, inflammatory markers (erythrocyte sedimentation rate, C-reactive protein, antinuclear antibody, rheumatoid factor, anti-neutrophil cytoplasmic antibody), lactate, pyruvate, iron studies, thyroid studies, Lyme screen, serum amino acids, creatine phosphokinase, urine organic acids, hypercoagulable profile, and lipoprotein A panels. Echocardiography was normal.

The patient was diagnosed with lenticulostriate stroke precipitated by mild CHI and was admitted to the intensive care unit for monitoring. Aspirin was started in the emergency department at a dose of 5 mg/kg per day. The right-sided hemiparesis improved during the following 48 hours. All symptoms gradually

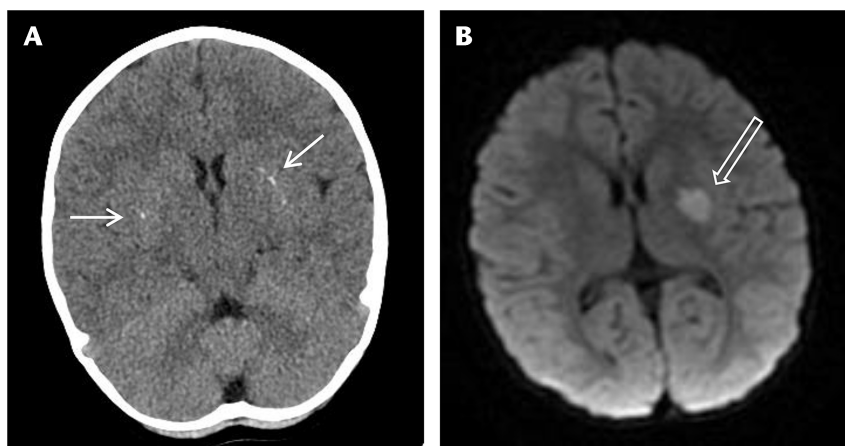


FIGURE 1. Brain CT and MRI images of a 2-year-old patient with signs and symptoms of stroke after a mild CHI. A, The brain CT image shows calcifications of the basal ganglia suggesting mineralizing angiopathy (solid arrows). B, The brain MRI image shows an infarct in the distribution of the lenticulostriate artery (open arrow).

improved over the next weeks, and the patient had full recovery of aphasia, facial nerve function, and upper and lower extremity function within 2 months.

DISCUSSION

A very small subset of children with mild CHI can present with signs and symptoms of cerebral infarction. A thorough neurological examination will identify the infants and children with abnormal neurological examination who need further evaluation and imaging. Mineralizing angiopathy is believed to be a predisposing factor for lenticulostriate stroke occurring after CHI in infants and toddlers.

Lenticulostriate stroke has been previously reported in infants and constitutes less than 2% of all childhood ischemic strokes.⁴ Despite rarity of lenticulostriate stroke, there have been few case reports and 2 case series suggesting an association of mild CHI with lenticulostriate stroke, especially in infants younger than 2 years.^{4–13} Recently, Yang et al⁵ described a series of 16 infants who developed cerebral infarction after mild CHI. Similar to our patient, 10 of the 16 patients had basal ganglia calcifications detected on brain CT. In addition, lenticulostriate artery mineralization was observed in a series of 23 infants with basal ganglia ischemic stroke after mild CHI. The authors describe the following characteristics of lenticulostriate stroke after CHI: (i) age 6 to 24 months, previously healthy patient; (ii) neurological deficits of rapid onset, minutes to hours after a mild CHI; (iii) hemiparesis on the affected side; (iv) bilateral linear mineralization along lenticulostriate arteries on brain CT; and (v) good short-term and long-term outcome, with the exception of patients with recurrent stroke.⁶

Several mechanisms are postulated for lenticulostriate stroke occurring after mild CHI. Vasospasm or thromboembolism of the lenticulostriate artery due to rapid brain displacement during the traumatic impact is one proposed mechanism.¹⁴ The lenticulostriate arteries, responsible for the flow to the basal ganglia, are end arteries originating from the initial segment of middle cerebral artery.¹⁵ These vessels originate at an acute angle from the middle cerebral artery, and in infants and children, the angle is more acute. Stretching and distorting of the arteries during trauma may lead to vasospasm, with consequent decrease in regional blood flow.^{14,16,17} Another anatomical age variation is at the level of the sphenoid bone, which is not fully developed in children, possibly predisposing

this age group to a higher risk of stretch injury secondary to increased brain mobility.¹⁸ Supporting this hypothesis, in one large case series, patients with stroke were 36 more times likely to have had head trauma in the week before the stroke.¹⁹ In addition, mineralizing angiopathy represents another predisposing factor for lenticulostriate stroke after a mild CHI in the pediatric population. Mineralizing angiopathy can be idiopathic or secondary to infection such as cytomegalovirus, echovirus, Epstein-Barr virus, and mycoplasma.⁵ Mineralizing angiopathy might result in more rigid vessels and increased sensitivity to stretch injury, with vascular maturation occurring as the child ages, mineralizing angiopathy might regress so that the risk of stroke by this mechanism would decline in older children.²⁰

Pediatric patients with lenticulostriate stroke generally have onset of symptoms within an hour after the injury.^{4,6,9–14} A thorough neurological examination in the emergency department will identify these abnormalities. Brain imaging is indicated for the acute evaluation of children with focal neurological deficits after mild CHI.²¹ Recent studies highlight the higher diagnostic ability of thin-section spiral CT with multiplanar reconstructions as an alternative choice to standard CT^{5,6}; however, in young children, there is a concern of increased radiation administered using the thin-section spiral CT. Magnetic resonance imaging can further delineate the ischemic injury; however, if head CT is not obtained, the pathological entity of mineralizing angiopathy might not be recognized. Exclusion of other possible etiologies of stroke in children should be performed using hematological, metabolic, cardiac, and infection investigations.

In conclusion, although most infants presenting with CHI will present with headache, nausea, vomiting, or altered consciousness, a few infants will present with focal hemiparesis or other acute stroke deficits. Basal ganglia infarction after minor CHI in infants with mineralizing angiopathy requires a high index of suspicion and thorough neurological examination. Imaging including brain CT to detect calcified vessels and MRI to detect acute cytotoxic edema can confirm the suspected diagnosis.

REFERENCES

1. Faul MXL, Wald MM, Coronado VG. *Traumatic Brain Injury in the United States: Emergency Department Visits, Hospitalizations and Deaths 2002–2006*. Atlanta, GA: Centers for Disease Control and Prevention, National Center for Injury Prevention and Control; 2010.

2. Monje ML, Toda H, Palmer TD. Inflammatory blockade restores adult hippocampal neurogenesis. *Science*. 2003;302:1760–1765.
3. Kuppermann N, Holmes JF, Dayan PS, et al. Identification of children at very low risk of clinically-important brain injuries after head trauma: a prospective cohort study. *Lancet*. 2009;374:1160–1170.
4. Landi A, Marotta N, Mancarella C, et al. Basal ganglia stroke due to mild head trauma in pediatric age—clinical and therapeutic management: a case report and 10 year literature review. *Ital J Pediatr*. 2011;37:2.
5. Yang FH, Wang H, Zhang JM, et al. Clinical features and risk factors of cerebral infarction after mild head trauma under 18 months of age. *Pediatr Neurol*. 2013;48:220–226.
6. Lingappa L, Varma RD, Siddaiahgari S, et al. Mineralizing angiopathy with infantile basal ganglia stroke after minor trauma. *Dev Med Child Neurol*. 2014;56:78–84.
7. Nabika S, Kiya K, Satoh H, et al. Ischemia of the internal capsule due to mild head injury in a child. *Pediatr Neurosurg*. 2007;43:312–315.
8. Rana KS, Behera MK, Adhikari KM. Ischemic stroke following mild head injury is it the cause. *Indian Pediatr*. 2006;43:994–997.
9. Ahn JY, Han IB, Chung YS, et al. Posttraumatic infarction in the territory supplied by the lateral lenticulostriate artery after minor head injury. *Childs Nerv Syst*. 2006;22:1493–1496.
10. Seçkin H, Demirci AY, Değerliyurt A, et al. Posttraumatic infarction in the basal ganglia after a minor head injury in a child: case report. *Turk Neurosurg*. 2008;18:415–419.
11. Erbayraktar S, Tekinsoy B, Acar F, et al. Posttraumatic isolated infarction in the territory of Heubner's and lenticulostriate arteries: case report. *Kobe J Med Sci*. 2001;47:113–121.
12. Shaffer L, Rich PM, Pohl KR, et al. Can mild head injury cause ischaemic stroke? *Arch Dis Child*. 2003;88:267–269.
13. Kaya T, Ozkan R, Bozoğlu N, et al. Basal ganglia infarcts with calcifications in children. *Eur J Radiol*. 1995;20:48–51.
14. Dharker SR, Mittal RS, Bhargava N. Ischemic lesions in basal ganglia in children after minor head injury. *Neurosurgery*. 1993;33:863–865.
15. Umansky F, Gomes FB, Dujovny M, et al. The perforating branches of the middle cerebral artery. A microanatomical study. *J Neurosurg*. 1985;62:261–268.
16. Martin NA, Doberstein C, Zane C, et al. Posttraumatic cerebral arterial spasm: transcranial Doppler ultrasound, cerebral blood flow, and angiographic findings. *J Neurosurg*. 1992;77:575–583.
17. Stein SC, Graham DI, Chen XH, et al. Association between intravascular microthrombosis and cerebral ischemia in traumatic brain injury. *Neurosurgery*. 2004;54:687–691; discussion 691.
18. Garg K. *BD Chaurasia's Human Anatomy: Vol. 3: Head-Neck Brain*. New Delhi, India: CBS Publishers & Distributors; 2015:43–45.
19. Hills NK, Johnston SC, Sidney S, et al. Recent trauma and acute infection as risk factors for childhood arterial ischemic stroke. *Ann Neurol*. 2012;72:850–858.
20. Deveber G. Stroke in infancy: a convergence of causes. *Dev Med Child Neurol*. 2014;56:9–10.
21. National Clinical Guideline Centre (UK). *Head Injury: Triage, Assessment, Investigation and Early Management of Head Injury In Children, Young People and Adults*. London, UK: National Institute for Health and Care Excellence (UK); 2007.