

# Serial Arterial Spin Labeling May Be Useful in Assessing the Therapeutic Course of Cerebral Venous Thrombosis: Case Reports

Sho FURUYA,<sup>1</sup> Masahito KAWABORI,<sup>1,2</sup> Noriyuki FUJIMA,<sup>3</sup> Kikutaro TOKAIRIN,<sup>1</sup> Shuho GOTO,<sup>1</sup> Motoyuki IWASAKI,<sup>1</sup> Yoshimasa NIIYA,<sup>1</sup> and Shoji MABUCHI<sup>1</sup>

<sup>1</sup>Department of Neurosurgery, Otaru General Hospital, Otaru, Hokkaido, Japan;

<sup>2</sup>Department of Neurosurgery, Hokkaido University Graduate School of Medicine, Sapporo, Hokkaido, Japan;

<sup>3</sup>Department of Diagnostic and Interventional Radiology, Hokkaido University Hospital, Sapporo, Hokkaido, Japan

## Abstract

We report two cases of cerebral venous thrombosis (CVT) which serial arterial spin labeling (ASL) was useful in evaluating the clinical course of the disease. A 48-year-old female presented with acute seizure, and was diagnosed as transverse-sigmoid sinus thrombosis. ASL imaging revealed low signal intensity in the right temporal lobe, suggesting the decreased perfusion by elevated venous pressure. Soon after the treatment, while the development of venous collateral has not fully observed by magnetic resonance (MR) angiography, low ASL signal within the right temporal lobe have shown remarkable improvement. A 65-year-old female presented with vomiting and subsequent seizure was diagnosed as superior sagittal sinus thrombosis. The low ASL signal within the right frontal lobe seen in the acute stage improved to the normal level by the course of time, before the good collateral can be seen by MR angiography. This is the first report to assess the sequential change of the cerebral perfusion of CVT by ASL, and ASL may provide additional useful information in combination with conventional modalities.

Keywords: cerebral venous sinus thrombosis, arterial spin labeling, transverse-sigmoid sinus thrombosis, superior sagittal sinus thrombosis

## Introduction

Cerebral venous sinus thrombosis (CVST) is an uncommon disease with potentially serious consequence.<sup>1–3</sup> Its mortality rate was around 30–50% according to the early reports,<sup>4</sup> however, the recent neuroimaging technique enabled fast and reliable diagnostic accuracy against the disease and its mortality rate has dropped to 5–9.4%.<sup>5</sup> The diagnosis of CVST can be most easily established based on the findings of magnetic resonance (MR) venography, fluid-attenuation inversion recovery (FLAIR), computed tomography venography (CTV) and conventional angiography.<sup>2,3,6</sup> However, precise evaluation of the treatment efficacy of CVST is still somewhat challenging. MR venography (MRV) or CTV may provide arterial and venous morphological information, but it is not suitable for elucidating the development of collateral

circulation and the improvement of the brain perfusion. Arterial spin labeling (ASL) is a newly developed non-invasive MR method to identify brain perfusion, and is increasingly adapted to the clinical settings.<sup>7</sup> In the present cases, the authors report that the serial ASL can detect decreased local brain perfusion in CVST patient which is probably due to the elevation of the capillary pressure and can provide important information of the sequential change in cerebral hemodynamics after the treatment. ASL evaluation of the cerebral hemodynamics may be of value in gaining further insight into pathophysiological characteristics of cerebral venous thrombosis.

## Case Reports

The first patient is a 48-year-old female with a past history of sinusitis, presented with slight conscious disturbance due to acute seizure. FLAIR imaging (Fig. 1A) demonstrated hyper intense, and Diffusion Weighted MR imaging (DWI) (Fig. 1E) showed slight hyper intense in the right temporal lobe. Gadolinium-enhanced T1-weighted MR imaging demonstrated cerebral ring enhancing lesions

Received February 14, 2017; Accepted May 8, 2017

Copyright© 2017 by The Japan Neurosurgical Society  
This work is licensed under a Creative Commons Attribution-NonCommercial-NoDerivatives International License.

in the right temporal lobe. MRV showed that the right transverse-sigmoid sinus was occluded by thrombosis (Fig. 1H), and CTV and conventional angiography confirmed the diagnosis of CVST by right transverse-sigmoid sinus occlusion. Cerebral angiography revealed venous congestion of the affected temporal lobe. ASL (post labeling delay; PLD 2200 msec) taken soon after the diagnosis showed marked low signal intensity within the affected right temporal lobe, suggesting that venous congestion led to elevate capillary pressure and decrease arterial perfusion (Fig. 1K). The lesion to normal ASL ratio was around 0.5 (Fig. 1D). She was immediately started with continuous heparin and anti-convulsant treatment. The neurological condition of the patient soon recovered after the treatment and the patient did not show any further seizure like episode. Although MRV taken at Day 14 showed only a slight improvement of the collateral circulation, ASL, FLAIR, and DWI showed marked improvement in the affected lesion (Figs. 1B, 1F, 1I, and 1L). She was discharged from hospital without neurological deficit five weeks from the onset. MR imaging taken at the time of discharge showed further improvement of ASL and MRV, suggesting the development of venous collateral drainage route. Follow-up MRI imaging 5 months after the onset showed almost full recovery of ASL signal, suggesting collateral venous drainage has decreased the capillary

pressure and that led to elevate brain arterial perfusion at the affected lobe (Figs. 1C, 1G, 1J, and 1M). Figure 1D presents the sequential change of the ASL from Day 1 to Day 140 and the gradual improvement of the ASL signal can be found.

The second patient is a 65-year-old female with a past medical history of hypertension and diabetes mellitus. Two days before her admission, the patient recognized numbness of her left hand. She was transported to our hospital complaining of vomiting and seizure. DWI demonstrated slight high intensity in the right frontal lobe (Fig. 2E). FLAIR imaging showed high intensity in the affected area (Fig. 2A). Computed tomography and T2\* MR imaging revealed the presence of intraparenchymal hemorrhage. MRV (Fig. 2H) and conventional angiography showed that the superior sagittal sinus was occluded, and she was diagnosed as superior sagittal sinus (SSS) thrombosis and the congestion of the venous perfusion. ASL (PLD: 2200 msec) on Day 3 showed marked low-signal-intensity within the affected right frontal area showing poor perfusion due to elevated capillary pressure by venous congestion (Fig. 2K). The lesion to normal ratio was around 0.4 (Fig. 2D). Because the patient showed intraparenchymal hemorrhage, she did not receive heparin treatment but only anti-convulsant therapy. For a few days, her symptoms of seizure continued and expansion of the cerebral

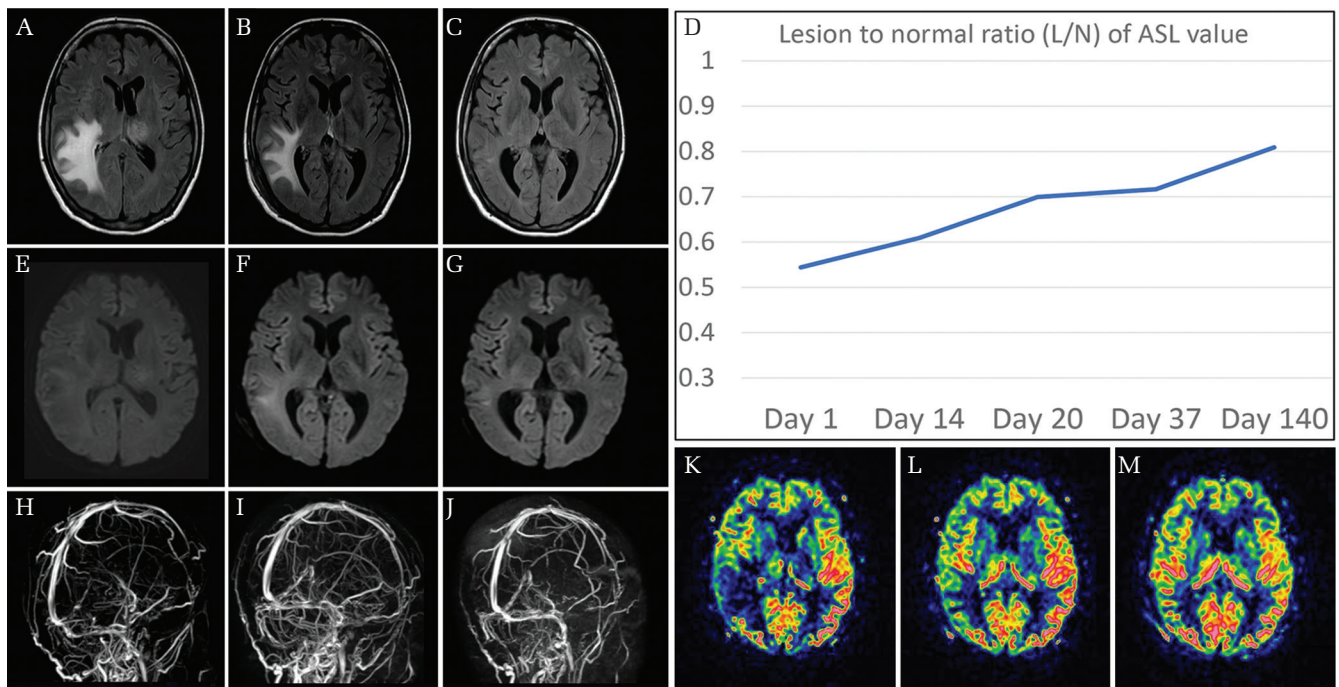


Fig. 1 The sequential change of the MRV, ASL, FLAIR, and DWI for patient with right transverse sinus occlusion. While DWI (E) showed slight hyper-intensity in the right temporal lesion, FLAIR imaging (A) demonstrated marked elevation in the affected area. Faint signal of right transverse sinus and straight sinus by MRV (H), with decreased ASL at the right temporal cortex can be seen at Day 1 (K). While the development of venous collateral is partial, improvement of ASL, FLAIR, DWI can be found at Day 14 (B, F, I, L). Further recovery of venous collateral and other parameters can be seen at Day 140 (C, G, J, M). The graph shows the serial change of the ASL signal by lesion to normal ratio (L/N) (D).

hemorrhage was observed. Follow-up MRV taken two weeks from the onset revealed slight development of collateral vessels and marked improvement of the ASL in the affected frontal cortex, suggesting that development of collateral circulation led to decrease the venous congestion and subsequent arterial perfusion (Figs. 2B, 2F, 2I, and 2L). One month after the onset, the patient recovered with a slight left upper extremity deficit and was transferred to the rehabilitation hospital. Follow-up MR imaging taken at the time of discharge showed further recovery of ASL signal (Figs. 2C, 2G, 2J, and 2M). Figure 2D presents the sequential change of the ASL from Day 2 to Day 32 and the gradual improvement of the ASL signal can be found.

All imaging was performed at 3.0T (Ingenia 3.0T; Philips) and included following sequences: MR venography (TR/TE/, 15/5 ms) with 384 mm thickness, fluid-attenuated inversion recovery (TR/TE/TI, 10000/120/2600 ms) with 5-mm thickness, 1.5 mm skip. ASL imaging was performed by using a pseudo-continuous mode with a reception time of 3488/3486/3460 ms, an echo time of 15 ms, and was performed by using a labeling period of 1200 ms followed by a PLD of 1000 ms or 2200 ms, with the labeling plane at the level of the foramen magnum. In order to semi-quantitatively analyze the ASL, semi-oval ROI was placed on the both temporal hemisphere and lesion to normal ratio (L/N) was calculated using the image analyzing system (Image J 1.41, National Institutes of Health, MD, USA) as described previously.<sup>8)</sup>

## Discussion

CVST is relatively uncommon disease with potentially serious consequences.<sup>1,3,6)</sup> Although development of modern diagnostic modality including MRV and CTV have achieved early diagnosis and treatment of the disease resulted with decreasing neurological sequelae, current mortality and morbidity rate of this disease is not negligibly low and the outcome of CVST remains largely unpredictable.<sup>2,4,5)</sup> Anticoagulation therapy using heparin is considered to be one of the current standard treatments,<sup>2)</sup> however, the data are still lacking regarding the adequate modality to monitor the treatment effect. Recanalization of the occluded sinus under MRV, CTV, and angiography are one of the indicators of treatment effect, however, it is well established that clinical recovery begins earlier than vessel recanalization and can even occur in the absence of recanalization.<sup>9)</sup> Kawabori et al. have reported the efficacy of susceptibility-weighted MR imaging (SWI) for monitoring the effectiveness of anticoagulation therapy against CVST.<sup>1)</sup> SWI is an extremely sensitive technique to detect magnetic susceptibility changes between blood product and tissues, developed as a method of high resolution MR venography based on the blood oxygen level dependent effect, and is suitable for detecting the cortical vein. They reported that dilated cortical vein can be found at the acute stage of CVST, and it will subsequently vanish after initiating the treatment, even though the SSS is still mostly occluded. Kawai

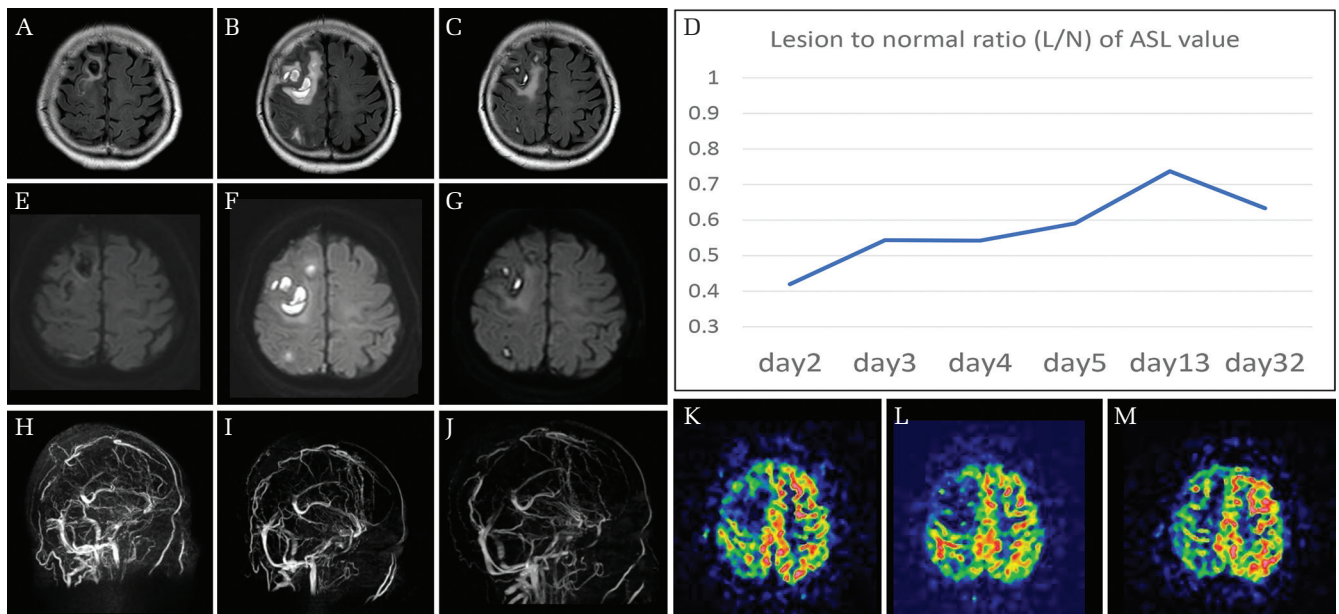


Fig. 2 The sequential change of the FLAIR (A, B, C), DWI (E, F, G), MRV (H, I, J), and ASL (K, L, M) for patient with superior sagittal sinus (SSS) thrombosis. Faint signal of the SSS with decreased ASL at the right frontal cortex can be found at Day 3 (H, K). While the patient showed expansion of the hemorrhage during this period (B, F), improvement of the ASL with only a partial recanalization of the sinus can be seen at Day 13 (I, L). Further improvement of the ASL and other parameters can be seen at Day 32 (C, G, J, M). The graph shows the serial change of the ASL signal by lesion to normal ratio (L/N) (D).

et al. have also focused on the efficacy of positron emission tomography (PET) scanning. Increased regional cerebral blood volume (rCBV) and decreased regional cerebral blood flow (rCBF) were seen at the acute phase of CVST, and they also found the rapid improvement of both rCBV and rCBF parameters with only a partial recanalization of the occluded sinus after treatment.<sup>10</sup> Elevated CBV is thought to suggest increased venous and capillary blood volume caused by congestion of the venous drainage, and increased venous pressure in microcirculation leads to decreased CBF.<sup>11,12</sup>

Our present study also demonstrated that serial ASL may be an alternative method to monitor cerebral perfusion after the treatment. ASL is a newly developed non-invasive MR technique that magnetically labelled inflowing blood in the feeding artery proximal to the brain can be monitored at the brain imaging slice level, and quantify regional CBF with high reproducibility. ASL has several significant advantages over the conventional hemodynamic assessment method including PET and single photon emission computed tomography (SPECT), because this method can be done under relatively simple set up with shorter acquisition time and does not require ionizing radiation. ASL also has advantages over other MRI and CT technique such as dynamic susceptibility contrast, which requires injection of a contrast agent which is not suitable for frequent study.<sup>13</sup> Although the standardized protocol and method to quantitatively measure CBF is still lacking, ASL has been increasingly adopted to clinical settings including leptomeningeal collateral circulation,<sup>7</sup> brain tumor vascularity,<sup>14</sup> epilepsy,<sup>15</sup> and so on. To our knowledge, this is the first report of using ASL as an assessment tool of the cerebral circulation with CVST patient, and we have found that not only the lesion of impaired cerebral perfusion can be distinguished in the acute phase of the CVST, but also ASL might be useful for assessing the treatment effect of the disease. It is quite interesting that ASL showed mild improvement of the cerebral perfusion soon after the initiation of treatment with lack of obvious visualization of collateral development by MRV. These data suggest the development of microcirculatory collateral and improvement of the capillary perfusion.

However, there are several limitations which should be noted. First, although some reports have shown a good correlation of ASL and cerebral perfusion monitored by standard method such as SPECT and PET,<sup>16–18</sup> it is unclear whether ASL in CVST accurately correlates with cerebral perfusion since ASL values are known to be modified by several parameters including blood pressure, arterial vessel diameter size and so on.<sup>19</sup> In this report we have adopted L/N to evaluate the improvement of cerebral perfusion, however, further validation of ASL value and cerebral perfusion are necessary. Second, there are currently no data to show optimized PLD time for

this disease. In this report, we have obtained both 1000 and 2200 msec for PLD, however, data from 1000 msec did not demonstrate the difference between the affected and normal lesion. This is probably due to the fact that anti-convulsant and hypertensive drug decreases the blood pressure and brain perfusion, and it is too short for labeled water to enter even the unaffected brain. Alsop et al. have also reported the difficulty of determining the optimal PLD for ischemic disease, since the longer PLD lead to improve CBF quantification, though at the price of a loss in signal to L/N ratio due to T1-related decay of the labeled spins.<sup>20</sup> Multiple PLD with mapping of the inflow of label water in the tissue and suitable kinetic model followed by standardized SPECT or PET study may offer the potential to elucidate the accurate CBF value. Third, the limited number of subjects in this study is also a shortcoming and further prospective studies in a larger patient population are required to confirm the impact of ASL imaging as a method to follow up CSVT.

The present cases illustrate that ASL can non-invasively demonstrate the impaired hemodynamics in the acute phase of the CVST and the sequential treatment effect. ASL may provide additional understanding against the pathophysiological of the CVST and can provide additional value to conventional modalities.

### Conflicts of Interest Disclosure

The authors have no conflict of interest.

### References

- 1) Kawabori M, Kuroda S, Kudo K, et al.: Susceptibility-weighted magnetic resonance imaging detects impaired cerebral hemodynamics in the superior sagittal sinus thrombosis—case report. *Neurol Med Chir (Tokyo)* 49: 248–251, 2009
- 2) Saposnik G, Barinagarrementeria F, Brown RD, et al.: American Heart Association Stroke Council and the Council on Epidemiology and Prevention: Diagnosis and management of cerebral venous thrombosis: a statement for healthcare professionals from the American Heart Association/American Stroke Association. *Stroke* 42: 1158–1192, 2011
- 3) Walecki J, Mruk B, Nawrocka-Laskus E, Piliszek A, Przelaskowski A, Sklinda K: Neuroimaging of cerebral venous thrombosis (CVT) - old dilemma and the new diagnostic methods. *Pol J Radiol* 80: 368–373, 2015
- 4) de Bruijn SF, Stam J: Randomized, placebo-controlled trial of anticoagulant treatment with low-molecular-weight heparin for cerebral sinus thrombosis. *Stroke* 30: 484–488, 1999
- 5) Isensee C, Reul J, Thron A: Magnetic resonance imaging of thrombosed dural sinuses. *Stroke* 25: 29–34, 1994
- 6) Qu H, Yang M: Early imaging characteristics of 62 cases of cerebral venous sinus thrombosis. *Exp Ther Med* 5: 233–236, 2013

- 7) Lou X, Yu S, Scalzo F, et al.: Multi-delay ASL can identify leptomeningeal collateral perfusion in endovascular therapy of ischemic stroke. *Oncotarget* 8: 2437–2443, 2017
- 8) Ito M, Kuroda S, Sugiyama T, et al.: Validity of bone marrow stromal cell expansion by animal serum-free medium for cell transplantation therapy of cerebral infarct in rats—a serial MRI study. *Transl Stroke Res* 2: 294–306, 2011
- 9) Brucker AB, Vollert-Rogenhofer H, Wagner M, et al.: Heparin treatment in acute cerebral sinus venous thrombosis: a retrospective clinical and MR analysis of 42 cases. *Cerebrovasc Dis* 8: 331–337, 1998
- 10) Kawai N, Shindou A, Masada T, Tamiya T, Nagao S: Hemodynamic and metabolic changes in a patient with cerebral venous sinus thrombosis: evaluation using O-15 positron emission tomography. *Clin Nucl Med* 30: 391–394, 2005
- 11) Schaller B, Graf R, Wienhard K, Heiss WD: A new animal model of cerebral venous infarction: ligation of the posterior part of the superior sagittal sinus in the cat. *Swiss Med Wkly* 133: 412–418, 2003
- 12) Gotoh M, Ohmoto T, Kuyama H: Experimental study of venous circulatory disturbance by dural sinus occlusion. *Acta Neurochir (Wien)* 124: 120–126, 1993
- 13) Fan AP, Jahanian H, Holdsworth SJ, Zaharchuk G: Comparison of cerebral blood flow measurement with [15O]-water positron emission tomography and arterial spin labeling magnetic resonance imaging: A systematic review. *J Cereb Blood Flow Metab* 36: 842–861, 2016
- 14) Law-Ye B, Schertz M, Galanaud D, Dormont D, Pyatigorskaya N: Arterial spin labeling to predict brain tumor grading: limits of cutoff cerebral blood flow values. *Radiology* 282: 610–612, 2017
- 15) Shimogawa T, Morioka T, Sayama T, et al.: The initial use of arterial spin labeling perfusion and diffusion-weighted magnetic resonance images in the diagnosis of nonconvulsive partial status epileptics. *Epilepsy Res* 129: 162–173, 2017
- 16) Hosoda K: The significance of cerebral hemodynamics imaging in carotid endarterectomy: a brief review. *Neurol Med Chir (Tokyo)* 55: 782–788, 2015
- 17) Yamamoto D, Hosoda K, Uchihashi Y, et al.: Perioperative changes in cerebral perfusion territories assessed by arterial spin labeling magnetic resonance imaging are associated with postoperative increases in cerebral blood flow in patients with carotid stenosis. *World Neurosurg* 102: 477–486, 2017
- 18) Uchihashi Y, Hosoda K, Zimine I, et al.: Clinical application of arterial spin-labeling MR imaging in patients with carotid stenosis: quantitative comparative study with single-photon emission CT. *Am J Neuroradiol* 32: 1545–1551, 2011
- 19) Zaharchuk G: Arterial spin label imaging of acute ischemic stroke and transient ischemic attack. *Neuroimaging Clin N Am* 21: 285–301, x, 2011
- 20) Alsop DC, Detre JA: Reduced transit-time sensitivity in noninvasive magnetic resonance imaging of human cerebral blood flow. *J Cereb Blood Flow Metab* 16: 1236–1249, 1996

---

Address reprint requests to: Masahito Kawabori, MD, PhD, Department of Neurosurgery, Hokkaido University Graduate School of Medicine, Kita 15 Nishi 7, Kita-ku, Sapporo, Hokkaido 060-8638, Japan.  
e-mail: masahitokawabori@yahoo.co.jp