

Case Report

Mechanical thrombectomy for pediatric acute stroke and ventricular assist device

Robert Clinton Stowe^{a,*}, Peter Kan^b, Day Burruss Breen^a, Sonika Agarwal^a

^a Department of Pediatric Neurology and Developmental Neuroscience, Baylor College of Medicine, Houston, TX, United States

^b Department of Neurosurgery, Baylor College of Medicine, Houston, TX, United States

Received 19 June 2017; received in revised form 1 August 2017; accepted 4 August 2017

Abstract

Background: Certain pediatric populations have increased risk of ischemic strokes, including those with cardiac disease and those dependent on mechanical circulatory devices such as ventricular assist devices. Due to their need for chronic anticoagulation, patients with mechanical circulatory devices are not candidates for systemic thrombolysis and thus treatment of acute ischemic stroke is limited.

Case: A 9-year-old boy with a ventricular assist device presented with acute onset of dense right hemiparesis, global aphasia, and a pediatric NIHSS score of 23. Vessel imaging showed an occlusive proximal left middle cerebral artery thrombus successfully removed via mechanical thrombectomy within 4.5 h of symptom onset. His pediatric NIHSS 72 h after presentation was 3.

Conclusions: This case represents only the third report of successful mechanical thrombectomy for acute ischemic stroke in a pediatric patient with a ventricular assist device and the first using the Trevo stent retriever system. Our patient's excellent outcome highlights mechanical thrombectomy as a potential therapeutic option for children with ventricular assist devices experiencing acute neurological changes and radiologic evidence of proximal vessel occlusion.

© 2017 The Japanese Society of Child Neurology. Published by Elsevier B.V. All rights reserved.

Keywords: Acute ischemic stroke; LVAD; Mechanical thrombectomy; Arterial stroke; Angiography

1. Introduction

Ischemic strokes are generally rare in the pediatric population and risk factors are multitudinous, including cardiac disease, prothrombotic states, and arteriopathy. The Canadian Pediatric Ischemic Stroke Registry noted

an incidence of arterial ischemic stroke of 1.72 events per 100,000 children per year [1]. Children on mechanical circulatory support devices for heart failure, such as left ventricular assist devices (LVADs), have a risk of stroke as high as 29% and any focal neurologic deficit in these children is suspicious for thromboembolic strokes [2,3].

There is a lack of standardized guidelines to aid in assessment or treatment of pediatric patients with acute ischemic strokes or LVAD-associated strokes. The risk or benefits of various treatments have not been well established. A population-based evaluation of

Abbreviations: LVAD, left ventricular assist device; NIHSS, National Institute of Health Stroke Scale; CT, computed tomography; MCA, middle cerebral artery

* Corresponding author at: 6701 Fannin Street, Clinical Care Center #1250, Houston, TX 77030, United States.

E-mail address: stowe@bcm.edu (R.C. Stowe).

endovascular therapy in pediatric stroke demonstrated that it was a very rare procedure (<1% of the cohort of 3184 patients) performed in patients that tended to be older (>10 years) and present with more significant focal neurological deficits [4]. Some centers have institutional guidelines that facilitate timely selection of various treatment options, however current evidence to offer thrombectomy to children is insufficient [5].

2. Case report

A 9-year-old male with a history of complete atrioventricular block with subsequent biventricular chamber pacemaker placement and severe dilated cardiomyopathy with continuous flow HVAD (Heartware Inc.; Framingham, Massachusetts) on daily warfarin and aspirin developed acute onset of right-sided weakness and loss of speech at approximately 9:30 AM. He arrived to the emergency room at approximately 12:30 PM. Non-contrast head computed tomography (CT) was relatively normal with a high Alberta Stroke Program Early CT score of 9 (Fig. 1). CT angiography of the head demonstrated an acute thrombus of the M1 segment of the left middle cerebral artery (MCA) (Fig. 2). His INR was elevated to 3.4 (goal was 2–3). His glucose was normal.

Physical examination demonstrated a drowsy, globally aphasic young male with left gaze preference and right facial droop. The right extremities were unable to provide antigravity resistance. He demonstrated right-sided extinction and sensory loss. The National Institute of Health Stroke Scale (NIHSS) was 23.

Angiography corroborated a left M1 occlusion (Fig. 3A). A microcatheter was placed distal to the clot and a Trevo (Stryker Neurovascular; Fremont, California) 4 × 20 mm stent retriever was deployed wherein the clot was pulled via aspiration to the carotid terminus through the distal access catheter. Afterwards, the entire MCA vasculature was open with normal filling of the superior and inferior MCA divisions as well as the left

temporal branch (Fig. 3B); a small non-occlusive thrombus remained in the distal M1 (Thrombolysis in Cerebral Infarction 2b grade).

The patient's NIHSS improved to 7 approximately 24 h later. Head CT 48 h later demonstrated an evolving, small left MCA territory infarct (Fig. 4). Approximately 72 h after presentation, the NIHSS improved further to 3. He was alert, active, and conversant in full sentences with only mild dysarthria. He had a persistent mild right nasolabial fold flattening and right upper extremity drift. While in the intensive care unit, a heparin infusion was initiated for anticoagulation while warfarin was re-initiated with an increased INR goal of 3–3.5. He was discharged on hospital day 20 with outpatient rehabilitation services while awaiting heart transplantation.

3. Discussion

Our patient had a successful outcome with mechanical thrombectomy and did well in the rehabilitation period with remarkable improvement in his NIHSS. Thrombectomy was offered to this patient as he met criteria consistent with the American Heart Association/American Stroke Association 2015 guidelines [6]. Treatment with warfarin precluded him from systemic thrombolysis with tissue plasminogen activator. Use of endovascular treatment with direct thrombolysis or thrombectomy for acute cardioembolic stroke in pediatric patients with LVADs is rare [5,7]. Only two prior reports describe pediatric patients with LVADs and acute ischemic strokes being treated with mechanical thrombectomy and neither utilized the Trevo stent retriever system [8,9].

The mortality rate for pediatric patients with neurological events in the Berlin Heart Trial was 42% (25 of 59); significant ischemic stroke prompted withdrawal of care in 14 of those patients [3]. Based on the patient's presenting NIHSS score of 23, the likelihood of severe and possibly permanent neurological disability and how that may influence healthcare decision making cannot be underestimated.

A recent review of mechanical thrombectomy for pediatric acute ischemic stroke found high recanalization rates and good clinical outcome, though the sample size was small ($n = 29$) and provided only class IVC evidence [10]. Most available literature is retrospective case reports or series with small sample size, thus there is a high probability of ascertainment bias. This case adds to the available evidence for success of thrombectomy utilizing the Trevo stent retriever system and highlights the timely utilization of this new treatment modality in cardiac cases with mechanical devices who are at an extremely high risk for embolic stroke. Studies aimed at developing national guidelines or registries will help pool cases from all centers and better analyze the

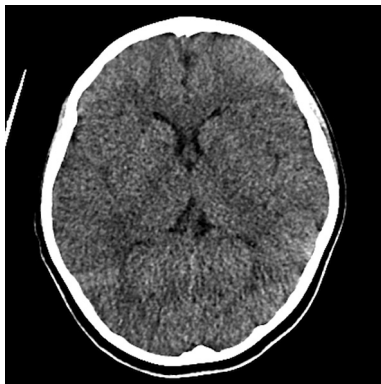

Fig. 1. Axial non-contrast computed tomography of the head at presentation.

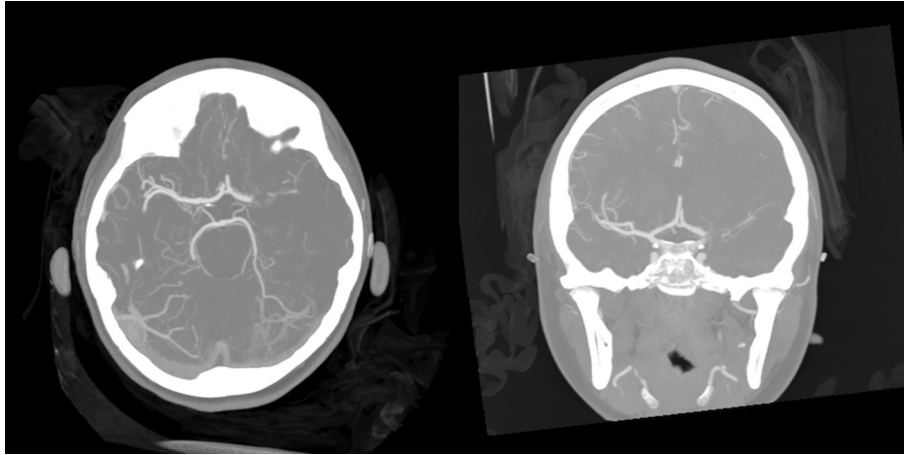


Fig. 2. Axial and coronal computed tomography angiography demonstrating blockage of left middle cerebral artery and loss of distal flow.

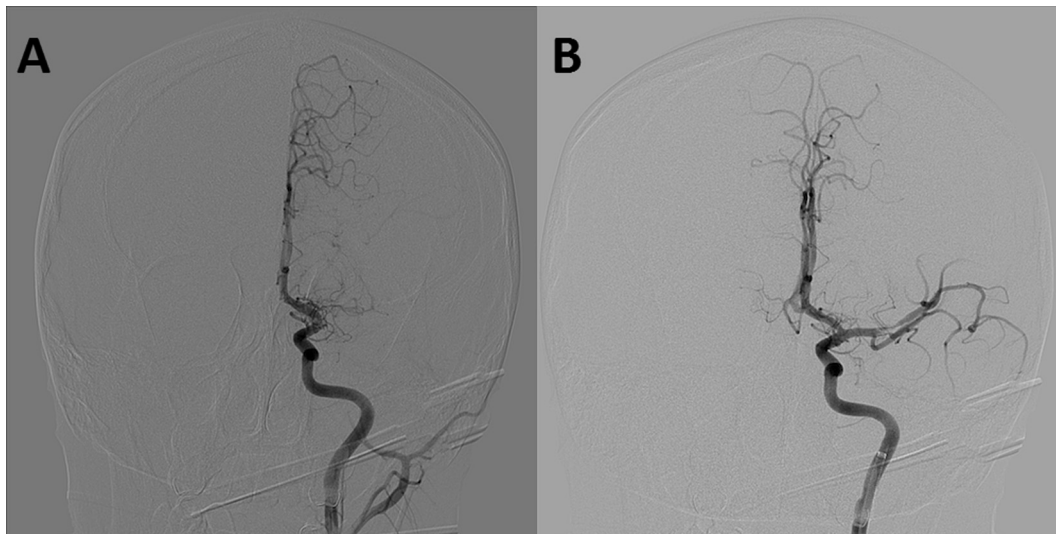


Fig. 3. A) Coronal angiography of left internal carotid artery demonstrating absent flow through left middle cerebral artery and B) coronal angiography demonstrating revascularization of left middle cerebral artery with small filling-defect thrombus still noted.

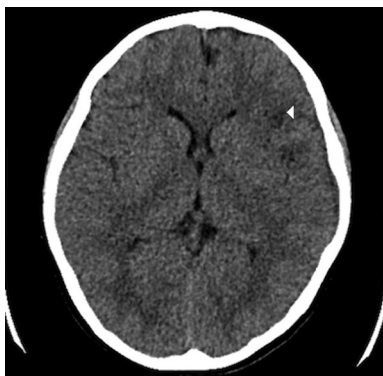


Fig. 4. Axial non-contrast computed tomography of the head demonstrating a small left middle cerebral artery distribution hypodensity denoted by the white triangle in frontal white matter.

outcomes of these newer treatments in the pediatric population and especially in the cohort with mechanic devices who are precluded from other treatment trials due to anticoagulant use.

Funding source

No funding was secured for this study.

Financial disclosure

Peter Kan acts as a consultant for Stryker Neurovascular (Fremont, California) and Medtronic (Minneapolis, Minnesota). The remaining authors have no financial relationships relevant to his article to disclose.

Table of contents summary

A 9-year-old boy with a ventricular assist device developed an acute left MCA thromboembolism successfully removed via mechanical thrombectomy with good clinical outcome.

Contributors' statement page

Dr. Stowe conceptualized and designed the study, drafted the initial manuscript, acquired and edited images, reviewed literature, and reviewed and revised the manuscript for intellectual content.

Dr. Kan and Dr. Breen aided in review and revision of the manuscript for intellectual content.

Dr. Agarwal conceptualized and designed the study, aided in drafting initial manuscript and literature review, and reviewed and revised the manuscript for intellectual content.

All authors approved the final manuscript as submitted and agree to be accountable for all aspects of the work.

Acknowledgments

Dr. Stowe conceptualized and designed the study, drafted the initial manuscript, acquired and edited images, reviewed literature, and reviewed and revised the manuscript for intellectual content. Dr. Kan and Dr. Breen aided in review and revision of the manuscript for intellectual content. Dr. Agarwal conceptualized and designed the study, aided in drafting initial manuscript and literature review, and reviewed and revised the manuscript for intellectual content. No funding was secured for this study.

References

- [1] deVeber GA, Kirton A, Booth FA, Yager YJ, Wirrell EC, Wood E, et al. Epidemiology and outcomes of arterial ischemic stroke in children: the Canadian pediatric ischemic stroke registry. *Pediatr Neurol* 2017;69:58–70.
- [2] Fraser Jr CD, Jaquiss RDB, Rosenthal DN, Humpl T, Canter CE, Blackstone EH, et al. Prospective trial of pediatric ventricular assist device. *N Engl J Med* 2012;367:532–41.
- [3] Jordan LC, Ichord RN, Reinhartz O, Humpl T, Pruthi S, Tjossem C, et al. Neurological complications and outcomes in the Berlin Heart EXCOR[®] pediatric investigational device exemption trial. *J Am Heart Assoc* 2015;4:e001429.
- [4] Wilson JL, Eriksson CO, Williams CN. Endovascular therapy in pediatric stroke: utilization, patient characteristics, and outcomes. *Pediatr Neurol* 2017;69(87–92):e2.
- [5] Buompadre MC, Andres K, Slater LA, Mohseni-Bod H, Guerrierian AM, Branson H, et al. Thrombectomy for acute stroke in childhood: a case report, literature review, and recommendations. *Pediatr Neurol* 2017;66:21–7.
- [6] Powers WJ, Derdeyn CP, Biller J, Coffey CS, Hoh BL, Jauch EC, et al. 2015 American heart association/American stroke association focused update of the 2013 guidelines for the early management of patients with acute ischemic stroke regarding endovascular treatment: a guideline for healthcare professionals from the American heart association/American stroke association. *Stroke* 2015;46:3020–35.
- [7] Byrnes JW, Williams B, Prodhan P, Erdem E, James C, Williamson R, et al. Successful intra-arterial thrombolytic therapy for a right middle cerebral artery stroke in a 2-year-old supported by a ventricular assist device. *Transpl Int* 2012;25:e31–3.
- [8] Alnaami I, Buchholz H, Ashforth R, Yeo T, Kotylak T, Alakabi M, et al. Successful use of solitaire FR for stroke in a pediatric ventricular assist device patient. *Ann Thorac Surg* 2013;96:e65–7.
- [9] Rhee E, Hurst R, Pukenas B, Ichord R, Cahill AM, Rossano J, et al. Mechanical embolectomy for ischemic stroke in a pediatric ventricular assist device patient. *Pediatr Transplant* 2014;18:e88–92.
- [10] Satti S, Chen J, Sivapatham T, Jayaraman M, Orbach D. Mechanical thrombectomy for pediatric acute ischemic stroke: review of the literature. *J Neurointerv Surg* 2017;9:732–7.