

# Accepted Manuscript

Moyamoya disease in a 8 year-old boy: direct bypass surgery in a province of Peru

Joham Choque-Velasquez, MD, Roberto Colasanti, MD, Danil A. Kozirev, MD, Juha Hernesniemi, MD, PhD, Akitsugu Kawashima, MD, PhD



PII: S1878-8750(17)31413-4

DOI: [10.1016/j.wneu.2017.08.112](https://doi.org/10.1016/j.wneu.2017.08.112)

Reference: WNEU 6362

To appear in: *World Neurosurgery*

Received Date: 8 July 2017

Revised Date: 1878-8750 1878-8750

Accepted Date: 15 August 2017

Please cite this article as: Choque-Velasquez J, Colasanti R, Kozirev DA, Hernesniemi J, Kawashima A, Moyamoya disease in a 8 year-old boy: direct bypass surgery in a province of Peru, *World Neurosurgery* (2017), doi: 10.1016/j.wneu.2017.08.112.

This is a PDF file of an unedited manuscript that has been accepted for publication. As a service to our customers we are providing this early version of the manuscript. The manuscript will undergo copyediting, typesetting, and review of the resulting proof before it is published in its final form. Please note that during the production process errors may be discovered which could affect the content, and all legal disclaimers that apply to the journal pertain.

**Title Page****Title**

Moyamoya disease in a 8 year-old boy: direct bypass surgery in a province of Peru

**Author names and affiliations:**

Joham Choque-Velasquez, MD,<sup>1,2</sup> Roberto Colasanti, MD,<sup>1,2,4</sup> Danil A. Kozirev, MD,<sup>2</sup> Juha Hernesniemi, MD, PhD<sup>1,2</sup>, Akitsugu Kawashima, MD, PhD<sup>1,3</sup>

<sup>1</sup>Neurosurgical Unit EsSalud Trujillo, Peru

<sup>2</sup>Department of Neurosurgery, Helsinki University Central Hospital, Helsinki, Finland

<sup>3</sup>Department of Neurosurgery, Tokyo Women's Medical University, Tokyo, Japan

<sup>4</sup>Department of Neurosurgery, Umberto I General Hospital, Università Politecnica delle Marche, Ancona, Italy

**Corresponding author:**

Joham Choque-Velasquez, MD

Department of Neurosurgery, Helsinki University Central Hospital,

Topeliuksenkatu 5, 00260 Helsinki, Finland

Email: johchove@hotmail.com

**Abstract**

**Background:** Pediatric moyamoya cases may be very arduous, even more in a developing country where the access to specialized centers may be prevented by different factors.

**Case description:** Herein, we report a challenging case, which was managed in the new Neurosurgical Center of Trujillo, regarding the direct anastomosis between the left superficial temporal artery and a cortical branch of the left middle cerebral artery in a 8-year-old Peruvian boy with moyamoya disease. Postoperatively motor deficits and aphasia improved. To the best of our knowledge, this is the first time that a direct revascularization for a pediatric moyamoya case was performed in Peru.

**Conclusions:** The creation of high specialized neurosurgical centers in the main strategic places of developing countries may allow an optimal treatment of neurosurgical patients with complex diseases.

**Keywords:**

Bypass, Developing countries, Direct revascularization, Microneurosurgery, Pediatric moyamoya disease

## Introduction

Direct bypass surgery as treatment for moyamoya disease is particularly demanding, even more in a developing country where the access to specialized centers may be impeded by different factors.

The absence of neurosurgeons with a specific experience in bypass procedures for pediatric moyamoya disease makes practically impossible to employ direct revascularization for these cases.

Moreover, as previously reported, economic issues, an inequitable geographic distribution of major specialistic services, together with the presence of some cultural aspects, such as a large variety of native languages, contribute to exacerbate the disparities in the healthcare quality between rural and urban populations in Peru.<sup>1-4</sup>

Since 2013, EsSalud (Peruvian Social Security Health System) started a crucial plan called "Plan Confianza" with the aim to improve the aforementioned problems. This project promotes the development of specialized neurosurgical centers in the main strategic places all around the country in order to make feasible an optimal treatment of neurosurgical patients. The creation of a "Neurosurgical Center of Excellence in Trujillo", led by Professor Juha Hernesniemi and his TEAM, falls within this plan.<sup>4,5</sup>

Herein, we present a challenging case, which was managed in the new Neurosurgical Center of Trujillo, regarding the direct anastomosis between the left superficial temporal artery and a cortical branch of the left middle cerebral artery in a 8-year-old Peruvian boy with moyamoya disease. To the best of our knowledge, this is the first time that a direct revascularization for a pediatric moyamoya case was performed in Peru.

## Case report

A right-handed 8-year-old peruvian boy was admitted to his local hospital in El Callao for recurrent right-sided tonic-clonic seizures associated to motor deficits and partial language deficit. His pathological anamnesis was unremarkable, except for a 4 years history of chronic headache.

CT scan revealed a diffuse cerebral edema in the left frontal region. Due to the absence of angiographic studies, viral encephalitis was initially suspected and an empiric antiviral therapy was started, together with antiepileptic drugs.

Twenty days after the first admission, the patient had again tonic-clonic seizures associated with severe left-sided motor deficit. Moreover, speech deficit reappeared, and it was graver than the first time. During the next 48 hours the patient had a severe neurological deterioration, and was transferred to the intensive care unit.

Then, the patient was moved to a neurological center of higher complexity in Lima, where he underwent to further diagnostic studies. Cerebral CT scan and MRI evidenced acute ischemia in the right middle cerebral artery and right anterior cerebral artery territories. Cerebral digital subtraction angiography revealed a complete occlusion of both internal carotid arteries, distal to the ophthalmic artery on the right side, and distal to the posterior communicating artery on the left side. Basal ganglia moyamoya collaterals were observed bilaterally. The right posterior communicating artery was patent after the injection of the contralateral left internal carotid artery; however, no significant collateralization was evident, particularly from the right external carotid artery (Figure 1).

Due to the absence of neurosurgeons with experience in bypass procedures for pediatric moyamoya disease, it was decided to schedule an indirect revascularization procedure for the following months. Meanwhile, the neurological status partially improved, and the patient presented severe left hemiparesis and expressive aphasia. Since February 2016, thanks to the cooperation of the Helsinki Neurosurgery Team and EsSalud Peru, a high center of excellence in microneurosurgery has been developed in Trujillo, Peru. As a part of our activities, the “First cerebral bypass and vascular microsurgery live course” was held.

Hence, the patient underwent two direct bypasses between the left superficial temporal artery and the left middle cerebral artery, which were performed by the senior author (A.K.) (Figure 2).

The postoperative course was uneventful, and surprisingly the patient could articulate some simple word at the immediate postoperative evaluation. One year after his surgery, the patient can perform his daily activities with some assistance, he is able to walk without any support and can pronounce simple words, still with some difficulty (**Video, Supplemental Digital Content**, showing preoperative and postoperative radiologic studies, as well as the postoperative neurologic status of the patient).

However, a moderate left side hemiparesis with severe distal dysfunction is still present. The possibility to perform an indirect or direct revascularization is latent, and is related to the availability of a bypass surgeon for this young patient.

## Discussion

Economic, cultural, and geographical reasons usually limit the access to specialized health centers in developing countries, especially in rural areas.<sup>1-4</sup>

In Peru, a country with a population of approximately 30 millions, the most developed neurosurgical centers are in Lima, the capital of the country. The few neuroendovascular units of the country are also concentrated in the capital district.

As the patients transfer system does not work effectively, the transport of an inpatient from more than a thousand of kilometers far inside the country to Lima implies a huge monetary investment, and may represent a high risk for the inpatient him/herself.

As described in our previous paper, benefits of centralized systems comprise a more simple protocol for the management of neurosurgical patients. Few neurosurgical centers assemble the best technological resources, as well as highly specialized surgical and diagnostic skills. The resulting high volume of specialistic procedures in few centers makes easier and quicker the training of doctors, thus improving the quality of neurosurgical care. Obviously, centralized systems require an impeccable patients transfer.<sup>4</sup>

On the other hand, as other experiences demonstrate,<sup>6-8</sup> we believe that an effective decentralization of major specialistic services, together with an efficient use of the available resources, may allow to improve healthcare systems in developing countries. In fact, a wise decentralization could help to distribute and retain high-specialized health workers in remote areas, thus ameliorating treatment outcomes of rural populations. As a result, this could make possible a straightforward management of most of the neurosurgical cases, and of all emergencies, while decreasing/limiting the transfer of the patients to other centers just to the more complex and non-urgent cases. In addition, this could also permit to reduce the wait list for elective cases, while offering to the entire population an appropriate and well-timed clinical and surgical care.<sup>4,5</sup>

In May 2016, thanks to the “Plan confianza” program of EsSalud, the first Peruvian Neurosurgical Center of Excellence was created in Trujillo.<sup>4,5,9-13</sup> Moreover, thanks to the participation of prominent vascular neurosurgeons, the first cerebral bypass and vascular microsurgery live course was carried out. The senior author (A.K.) performed for the first time in Peru a left superficial temporal artery-middle cerebral artery bypass procedure in a pediatric patient with severe moyamoya disease.

A pediatric patient with severe moyamoya disease and bihemispheric symptoms is very challenging. Even though we initially planned to perform an indirect revascularization, finally direct bypass surgery was carried out with the aim to reduce the risk of future ischemic complications in the relatively less damaged left cerebral hemisphere. Indeed, even if the brain MR did not show infarcts into the left language area, a complete expressive aphasia was present. We believe that the impairment of language was related to an hypoperfusion due to narrow

cerebral vessels in a still developing brain. Hence, we selected a direct revascularization procedure because of the limited left cerebral hemisphere ischemia in a patient with aphasia.

Initially, a simultaneous right side bypass was also thought. However, at the end the plan of a simultaneous bilateral bypass was dismissed due to the high risk of hyperperfusion syndrome and/or postoperative hemorrhage in a patient with a relatively recent large right cerebral hemisphere ischemia.

At one year follow-up, the clinical status of the patient is good and stable, and a new procedure for right direct or indirect revascularization is pending.

Diagnosis of moyamoya disease requires the evidence of a narrowing of the distal internal carotid arteries, which extends to the proximal middle cerebral and anterior cerebral arteries, along with collateral circulation formation at the base of the brain. Cerebral angiography is the gold standard for moyamoya disease diagnosis.<sup>14,15</sup>

Class I recommendations for moyamoya disease treatment emphasize revascularization surgeries, which may be categorized in direct and indirect procedures.<sup>16</sup> Indirect revascularization is characterized by the placement of dura mater, temporalis muscle, or superficial temporal artery onto the surface of the brain to stimulate subsequent angiogenesis. Direct revascularization is usually mediated by the anastomosis between the superficial temporal artery and a cortical branch of the middle cerebral artery. This last procedure is challenging and demands an experienced vascular neurosurgeon. As a consequence, children with moyamoya disease underwent indirect revascularization procedures in most of the cases.<sup>15</sup>

The senior author (A.K.), which has performed more than 1000 bypass procedures and has a wide experience in direct bypass for moyamoya disease, decided to perform superficial temporal artery-middle cerebral artery anastomosis on the basis of the above mentioned clinical-radiological features.<sup>17-19</sup>

According to a recent systematic review, indirect revascularization is associated with superior long-term results compared with direct procedures in both children and adults. Moreover, possible complications related with direct bypass are: hyperperfusion syndrome; probable rapid stenosis of the internal carotid artery, as well as disturbance in the development of moyamoya collaterals.<sup>20</sup>

In addition, indirect techniques, which are technically less demanding, do not require temporary occlusion of middle cerebral artery branches. Nonetheless, with indirect revascularization procedures, the development of collaterals is limited to the area of the craniotomy.<sup>21</sup> Moreover, indirect techniques take several months of angiogenesis in contrast to the immediate reperfusion offered by a low flow superficial temporal artery-middle cerebral artery bypass.<sup>22</sup>

**Conclusion**

Bypass procedures for moyamoya disease treatment are particularly challenging in developing countries due to the necessity of special environment and equipment. However, a good teamwork coordination, as well as a judicious application of microsurgical principles, and the presence of experienced vascular neurosurgeons may allow to perform these surgeries with reliable results, even in resource-challenged environments.

**Disclosure**

Prof. Juha Hernesniemi is an Aesculap counselor. The C. Ehrnrooth Foundation partially supported the development of a high specialized neurosurgical center in the Es-Salud Trujillo hospital, La Libertad region, Perú. The authors have no personal financial or institutional interest in any of the drugs, materials, and devices described in this article.



## References

1. Behrman JR, Behrman JA, Perez NM. Out of sync? Demographic and other social science research on health conditions in developing countries. *Demogr Res.* 2011;24(2):45-78. doi:10.4054/DemRes.2011.24.2.
2. Camacho AV, Castro MD, Kaufman R. Cultural aspects related to the health of Andean women in Latin America: a key issue for progress toward the attainment of the Millennium Development Goals. *Int J Gynaecol Obstet.* 2006;94(3):357-363. doi:10.1016/j.ijgo.2006.04.028.
3. Larme AC. Health care allocation and selective neglect in rural Peru. *Soc Sci Med* 1982. 1997;44(11):1711-1723.
4. Choque-Velasquez J, Colasanti R, Baffigo-Torre V, et al. Developing the First Highly Specialized Neurosurgical Center of Excellence in Trujillo, Peru: Work in Progress-Results of the First Four Months. *World Neurosurg.* 2017;102:334-339. doi:10.1016/j.wneu.2017.01.063.
5. Choque-Velasquez J, Colasanti R, Fotakopoulos G, Elera-Florez H, Hernesniemi J. Seven Cerebral Aneurysms: A Challenging Case from the Andean Slopes Managed with 1-Stage Surgery. *World Neurosurg.* 2017;97:565-570. doi:10.1016/j.wneu.2016.10.078.
6. Adeleye AO, Fasunla JA, Young PH. Skull base surgery in a large, resource-poor, developing country with few neurosurgeons: prospects, challenges, and needs. *World Neurosurg.* 2012;78(1-2):35-43. doi:10.1016/j.wneu.2011.07.015.
7. Wahba MY, Kelly ME. The high cost of endovascular neurosurgery therapies and the need to sustain quality on limited resources. *World Neurosurg.* 2014;82(1-2):7-8. doi:10.1016/j.wneu.2014.04.062.
8. Davis MC, Than KD, Garton HJ. Cost effectiveness of a short-term pediatric neurosurgical brigade to Guatemala. *World Neurosurg.* 2014;82(6):974-979. doi:10.1016/j.wneu.2014.08.038.
9. Velasquez JC, Lau J, Kozyrev D, et al. Clean, fast and preserving normal anatomy: "the Helsinki revolution" in microneurosurgery. *J Neurosurg Sci.* 2016;60(1):44-53.
10. Choque-Velasquez J, Colasanti R, Jahromi BR, Hernesniemi J. "Squeeze Maneuver" Assisted by Indocyanine Green Videoangiography: Simple Technique to "Resuscitate" Partially Occluded Bridging Veins During Microneurosurgical Operations. *World Neurosurg.* 2017;97:225-230. doi:10.1016/j.wneu.2016.09.107.

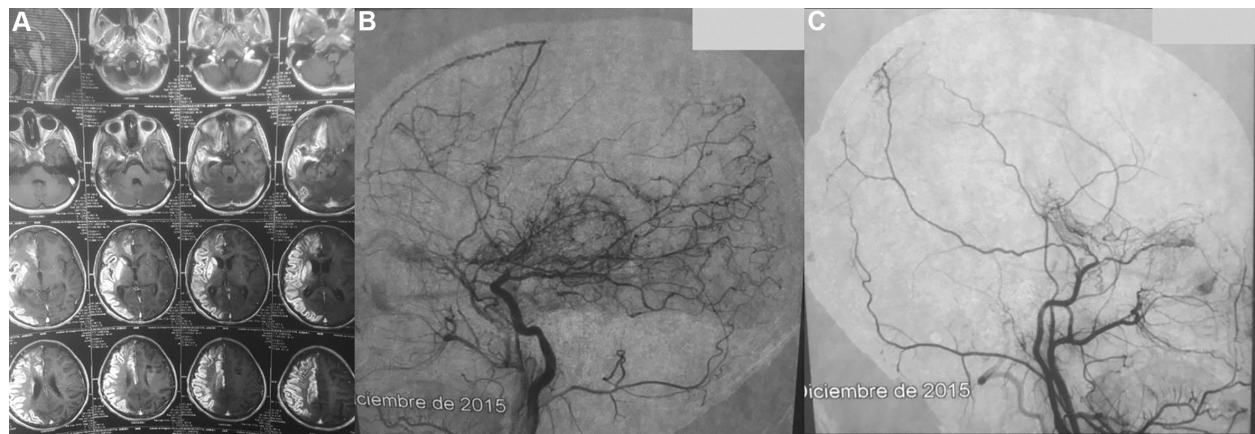
11. Choque-Velasquez J, Colasanti R, Jahromi BR, Rafei A, Sharafeddin F, Hernesniemi J. Short-Burst Bipolar Coagulation for Repairing Partially Damaged Brain Arteries Preserving Their Flow: Technical Note. *World Neurosurg.* 2016;93:324-329. doi:10.1016/j.wneu.2016.06.013.
12. Sharafeddin F, Hafez A, Lehecka M, et al. A5 segment aneurysm of the anterior cerebral artery, imbedded into the body of the corpus callosum: A case report. *Surg Neurol Int.* 2017;8:18. doi:10.4103/2152-7806.199559.
13. Choque-Velasquez J, Colasanti R, Resendiz-Nieves JC, et al. Supracerebellar infratentorial paramedian approach in Helsinki Neurosurgery: cornerstones of a safe and effective route to the pineal region. *World Neurosurg.* June 2017. doi:10.1016/j.wneu.2017.06.007.
14. Rhee JW, Magge SN. Moyamoya disease and surgical intervention. *Curr Neurol Neurosci Rep.* 2011;11(2):179-186. doi:10.1007/s11910-010-0173-8.
15. Scott RM, Smith ER. Moyamoya disease and moyamoya syndrome. *N Engl J Med.* 2009;360(12):1226-1237. doi:10.1056/NEJMra0804622.
16. Roach ES, Golomb MR, Adams R, et al. Management of stroke in infants and children: a scientific statement from a Special Writing Group of the American Heart Association Stroke Council and the Council on Cardiovascular Disease in the Young. *Stroke.* 2008;39(9):2644-2691. doi:10.1161/STROKEAHA.108.189696.
17. Kawashima A, Kawamata T, Yamaguchi K, Hori T, Okada Y. Successful superficial temporal artery-anterior cerebral artery direct bypass using a long graft for moyamoya disease: technical note. *Neurosurgery.* 2010;67(3 Suppl Operative):ons145-149; discussion ons149. doi:10.1227/01.NEU.0000382975.86267.40.
18. Okada Y, Kawashima A, Hori T. [STA-MCA and STA-ACA anastomosis for moyamoya disease]. *No Shinkei Geka.* 2009;37(10):959-971.
19. Morisawa H, Kawamata T, Kawashima A, et al. Hemodynamics and changes after STA-MCA anastomosis in moyamoya disease and atherosclerotic cerebrovascular disease measured by micro-Doppler ultrasonography. *Neurosurg Rev.* 2013;36(3):411-419. doi:10.1007/s10143-012-0441-y.
20. Macyszyn L, Attiah M, Ma TS, et al. Direct versus indirect revascularization procedures for moyamoya disease: a comparative effectiveness study. *J Neurosurg.* 2017;126(5):1523-1529. doi:10.3171/2015.8.JNS15504.

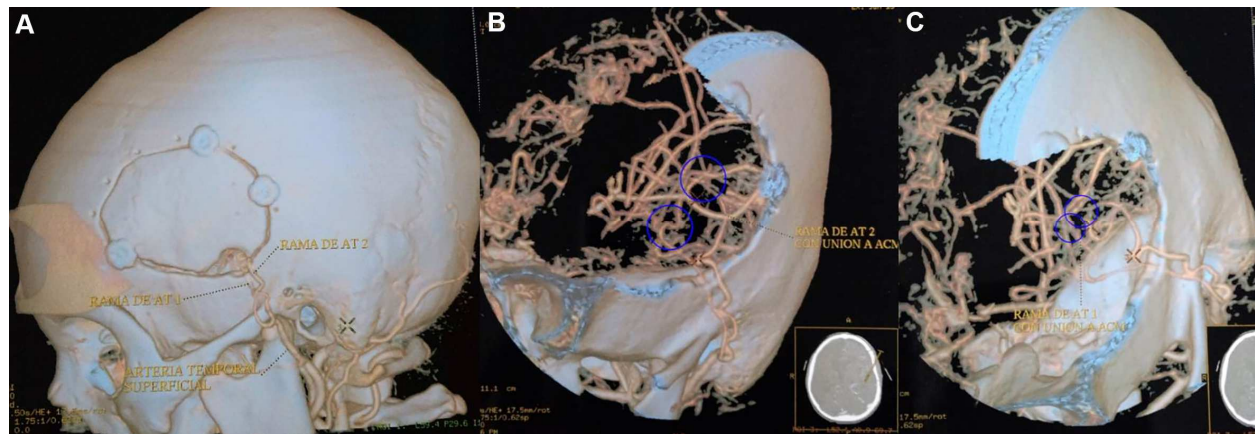
21. Kuroda S, Houkin K, Ishikawa T, et al. Determinants of intellectual outcome after surgical revascularization in pediatric moyamoya disease: a multivariate analysis. *Childs Nerv Syst.* 2004;20(5):302-308. doi:10.1007/s00381-004-0924-4.
22. Houkin K, Nakayama N, Kuroda S, Ishikawa T, Nonaka T. How does angiogenesis develop in pediatric moyamoya disease after surgery? A prospective study with MR angiography. *Childs Nerv Syst.* 2004;20(10):734-741. doi:10.1007/s00381-004-0971-x.

**Figure Legends**

**Fig. 1** Preoperative cerebral MRI (A) showing acute ischemia in the right middle cerebral artery and right anterior cerebral artery territories. Preoperative cerebral digital subtraction angiography (B, left internal and external carotid artery branches; C, right internal and external carotid artery branches) revealing a complete occlusion of both internal carotid arteries, distal to the ophthalmic artery on the right side, and distal to the posterior communicating artery on the left side. Basal ganglia moyamoya collaterals were observed bilaterally.

**Fig. 2** Postoperative CT angiogram 3D reconstructions illustrating the size of the craniotomy, as well as the two direct bypasses which were carried out between the left superficial temporal artery and the left middle cerebral artery.





**Title**

Moyamoya disease in a 8 year-old boy: direct bypass surgery in a province of Peru

**Highlights**

Direct bypass was performed in a 8 year-old Peruvian boy with moyamoya disease

This is the first direct revascularization for a pediatric moyamoya case in Peru

Postoperatively motor deficits and aphasia improved