


# Accepted Manuscript

Medullary decompression by sling repositioning of the Vertebral Artery with operative video: Technical Case Report

Luis C. Ascanio, Abdulrahman Y. Alturki, Christoph J. Griessenauer, Rouzbeh Motiei-Langroudi, Sandeep Kumar, Christopher S. Ogilvy



PII: S1878-8750(17)31513-9

DOI: [10.1016/j.wneu.2017.09.009](https://doi.org/10.1016/j.wneu.2017.09.009)

Reference: WNEU 6453

To appear in: *World Neurosurgery*

Received Date: 7 July 2017

Accepted Date: 2 September 2017

Please cite this article as: Ascanio LC, Alturki AY, Griessenauer CJ, Motiei-Langroudi R, Kumar S, Ogilvy CS, Medullary decompression by sling repositioning of the Vertebral Artery with operative video: Technical Case Report, *World Neurosurgery* (2017), doi: 10.1016/j.wneu.2017.09.009.

This is a PDF file of an unedited manuscript that has been accepted for publication. As a service to our customers we are providing this early version of the manuscript. The manuscript will undergo copyediting, typesetting, and review of the resulting proof before it is published in its final form. Please note that during the production process errors may be discovered which could affect the content, and all legal disclaimers that apply to the journal pertain.

**Medullary decompression by sling repositioning of the Vertebral Artery with operative  
video: Technical Case Report**

Luis C. Ascanio<sup>1</sup>, Abdulrahman Y Alturki<sup>1,2</sup>, Christoph J. Griessenauer<sup>11</sup>, Rouzbeh Motiei-  
Langroudi<sup>1</sup>, Sandeep Kumar<sup>3</sup>, Christopher S. Ogilvy<sup>1</sup>

<sup>1</sup>Neurosurgical Service, Beth Israel Deaconess Medical Center, Harvard Medical School, Boston,  
Massachusetts, USA

<sup>2</sup>Department of Neurosurgery, National Neurosciences Institute, King Fahad Medical City,  
Riyadh, Saudi Arabia

<sup>3</sup>Department of Neurology, Beth Israel Deaconess Medical Center, Harvard Medical School,  
Boston, Massachusetts, USA

Corresponding Author:

Christopher S. Ogilvy, M.D.

Neurosurgical Service

Beth Israel Deaconess Medical Center

110 Francis Street, Suite 3B.

Boston, MA 02215-5501

Phone: (617) 632-7246

cogilvy@bidmc.harvard.edu

---

<sup>1</sup>CJG Present address: Department of Neurosurgery, Geisinger Medical Center, Danville, Pennsylvania, USA

Keywords: Case report, cerebrovascular disorders, decompression, medulla oblongata, paresis, surgical, vertebral artery.

#### Disclosure

None of the authors have any personal, financial or institutional interest in any of the drugs, materials or devices described in this paper.

#### Funding Sources

This research did not receive any specific grant from funding agencies in the public, commercial, or not-for-profit sectors.

## **Abstract**

### *Background*

Vascular compression of the medullary pyramid resulting in neurological compromise is rare, therefore, diagnosis is difficult and ultimately delayed. Most patients present with a combination of cranial nerve, autonomic, and/or motor and sensory dysfunction. Presentation with a single sign such as hemiparesis is rare. The low number of cases reported has made it impossible to define a standard treatment for this unusual disorder.

### *Case description*

Here, we present a patient with a progressive left hemiparesis due to compression of the upper medulla by the vertebral artery, which was treated with repositioning of the artery using a sling. Clinical and radiological features including upper medullary compression by the left vertebral artery with effacement of the left medullary pyramid and T2/FLAIR signal changes in the right medulla are illustrated. The patient underwent a standard left retrosigmoid craniectomy for mobilization of the left vertebral artery with a Hemashield® (Maquet Cardiovascular, San Jose, California) sling (video). Postoperatively, the patient had significant improvement of the left hemiparesis and follow-up imaging showed decompression of the medulla with edema reduction.

### *Conclusions*

Vascular decompression using a sling has proven to be a valuable option for treatment of symptomatic vascular brain stem compression.

## Background

Vascular brain stem compression may be caused by dolichoectasia of the vertebrobasilar system<sup>1</sup> manifesting with a wide spectrum of signs and symptoms, including cranial nerve involvement, long tract dysfunction and/or autonomic abnormalities.<sup>2-7</sup> Vascular compression of the root entry zones of the facial and trigeminal nerve resulting in hemifacial spasm and trigeminal neuralgia is much more common.<sup>2,4,8</sup> Symptomatic medullary compression by the vertebral artery is a rare finding and a challenging diagnosis. Vascular decompression with slings for repositioning the vertebral artery has been reported in patients with hemifacial spasm<sup>2</sup> and trigeminal neuralgia.<sup>9</sup> For medullary compression by the vertebral artery, vascular decompression has been rarely reported.<sup>4</sup>

Here, we present a patient with a progressive left hemiparesis due to compression of the left upper medulla by the vertebral artery, which was treated with repositioning of the artery using a sling along with an operative video.

## Case description

A 57-year-old male developed progressive left lower extremity weakness in 2011 that worsened with prolonged standing and improved with resting. Over time, symptomatology also involved the ipsilateral upper extremity. Past medical history was significant for type 1 diabetes mellitus, hypercholesterolemia, hypertension, diabetic retinopathy, colonic polyps, and meniscal tear. The patient also has left Bell's palsy paresis unrelated to this condition. He quit smoking 30 years ago. On neurological examination, the patient had left-sided hemiparesis with motor strength 4/5 and ipsilateral hyperreflexia. Magnetic resonance angiography (MRA) showed that the left V4 segment of the vertebral artery effaced the left upper medullary pyramid at the decussation. This was associated with a T2/FLAIR signal change in the right medullary pyramid (Figure 1). Cerebral digital subtraction angiography revealed a mildly tortuous left vertebral artery with no signs of stenosis, dilatations, aneurysms, or atherosclerosis. Transcranial magnetic stimulation using a Nexstim® system (Nexstim Inc., Chicago, Illinois) showed increased motor evoked potential latency in the left first dorsal interosseous muscle compared to the right and absent motor evoked potential response from left tibialis anterior muscle at rest, suggestive of left sided corticospinal dysfunction. After consent was obtained, the patient was taken to the operating room for a repositioning of the left vertebral artery using a Hemashield® Platinum Finesse sling (Maquet Cardiovascular, San Jose, California) through a standard left retrosigmoid craniectomy. The sling of 3.5 mm width was slipped around the vertebral artery and pulled superiorly and laterally to suture against the left clival dura (Figure 2). No changes in somatosensory and motor evoked potentials occurred (Video 1). He was discharged to inpatient rehabilitation after 3 days in stable neurological condition. At 3 months' follow-up, the patient continued to show

improvement with almost complete resolution in his hemiparesis (4+/5). At 6 months' follow-up, MRI/MRA revealed decompression of the medulla with persistence of some of the T2/FLAIR signal change (Figure 3).

## Discussion

Here, we present a case of upper medullary dysfunction resulting in hemiparesis successfully treated with sling repositioning of the vertebral artery. Wolters et al. conducted a systematic review of cases with vertebrobasilar dolichoectasia and found that 28% of patients had brainstem compression with a five-year risk of progression of 10.9%.<sup>10</sup> Unfortunately, the report does not specify the precise location of brain stem compression and provides no data on medullary compression by the vertebral artery. Although medullary compression by vertebral arteries is rare with few documented reports<sup>2</sup>, there are no established treatment paradigms.

Vascular decompression is well established for hemifacial spasm, trigeminal neuralgia, and glossopharyngeal neuralgia.<sup>2-4,11,12</sup> Nakahara et al. and Savitz et al. reviewed all documented cases of medullary compression by the vertebral artery and their outcomes.<sup>7,12</sup> Most patients showed combined medullary dysfunction including cranial nerve dysfunction, paresis, and autonomic dysfunction. In the present case, the patient presented with isolated progressive left hemiparesis.

Kim et al. were the first in describing hemiparesis secondary vascular medullary compression.<sup>6</sup> Since then, 20 patients have been reported with similar symptomatology, 4 of which only experienced hemiparesis.<sup>4,7</sup> To our knowledge, the present case is only the fifth of its kind.

Despite compression of the left upper medulla, preoperatively MRI/MRA revealed T2/FLAIR signal change on the right side of the medulla above the decussation resulting in left hemiparesis. Savitz et al. reported that direct medullary compression can cause ipsilateral or contralateral motor dysfunction.<sup>7</sup> This may explain why the medullary compression in the present case did not localize to the ipsilateral corticospinal tract. Another possibility is that the medullary



compression may have led to ischemic injury on the right side, giving rise to the signal change in the right medullary pyramid.

Vertebral artery repositioning using a sling have been described for vascular decompression of the brain stem in various locations.<sup>2,11,3,12,4,6,13,9,14,15</sup> In fact, Sadashiva et al. described the use of a Teflon Hemashield® (Maquet Cardiovascular, San Jose, California) sling for medullary decompression. In the study, 2 patients had quadriparesis secondary to vascular medullary compression by the vertebral artery but declined surgery.<sup>4</sup> Hongo et al. pursued a different approach where decompression was achieved by sectioning the left vertebral artery after an unsuccessful attempt to mobilize of the left vertebral artery.<sup>16</sup> In the literature, 3 out of 4 documented patients experience a similar outcome to our patient.<sup>4,6,16</sup> However, Savitz et al. conducted a prospective study with 9 patients with medullary compression in which only 1 presented with left hemiparesis and was treated conservatively with aspirin and the hemiparesis did improve progressively over a 3-year period.<sup>777</sup> In the same study, 7 of 9 patients underwent medical treatment and the remaining 2 underwent vascular decompression. Patients treated conservatively did not have progression of symptoms and showed better outcomes than patients who underwent decompression. Despite these findings, no direct comparisons can be made as most of the patients in this study had more than 1 symptom from medullary compression.

### *Limitations*

For rare diseases, such as the present, it is extraordinarily difficult to achieve higher level medical evidence beyond the case report or series level. Also, we are lacking long-term clinical outcomes in the present case. While decompression should not be a first-line option for these

patients, it may be considered for selected cases, such as those with progressive or disabling deficits with a reasonable chance of improvement postoperatively.

**Conclusion**

Vascular decompression using a Hemashield<sup>®</sup> (Maquet Cardiovascular, San Jose, California) sling has proven to be a valuable option for treatment in selected cases of symptomatic vascular brain stem compression such as the medulla.

## References

1. Lou M, Caplan LR. Vertebrobasilar dilatative arteriopathy (dolichoectasia). *Ann N Y Acad Sci*. 2010;1184:121-133. doi:10.1111/j.1749-6632.2009.05114.x.
2. Grigoryan YA, Goncharov MZ, Lazebny VV. Hemifacial spasm caused by a contralateral vertebral artery: case report. *Surg Neurol*. 2000;53(5):493-497; discussion 497.
3. Zaidi HA, Awad A-W, Chowdhry SA, Fusco D, Nakaji P, Spetzler RF. Microvascular decompression for hemifacial spasm secondary to vertebrobasilar dolichoectasia: surgical strategies, technical nuances and clinical outcomes. *J Clin Neurosci Off J Neurosurg Soc Australas*. 2015;22(1):62-68. doi:10.1016/j.jocn.2014.09.008.
4. Sadashiva N, Shukla D, Bhat DI, Devi BI. Vertebral artery dolicoectasia with brainstem compression: role of microvascular decompression in relieving pyramidal weakness. *Acta Neurochir (Wien)*. 2016;158(4):797-801. doi:10.1007/s00701-016-2715-6.
5. Bejjani GK, Sekhar LN. Repositioning of the vertebral artery as treatment for neurovascular compression syndromes. Technical note. *J Neurosurg*. 1997;86(4):728-732. doi:10.3171/jns.1997.86.4.0728.
6. Kim P, Ishijima B, Takahashi H, Shimizu H, Yokochi M. Hemiparesis caused by vertebral artery compression of the medulla oblongata. Case report. *J Neurosurg*. 1985;62(3):425-429. doi:10.3171/jns.1985.62.3.0425.
7. Savitz SI, Ronthal M, Caplan LR. Vertebral artery compression of the medulla. *Arch Neurol*. 2006;63(2):234-241. doi:10.1001/archneur.63.2.234.
8. Ogawa A, Suzuki M, Shirane R, Yoshimoto T. Repositioning of the tortuous vertebrobasilar artery for trigeminal neuralgia: a technical note. *Surg Neurol*. 1992;38(3):232-235.
9. Masuoka J, Matsushima T, Kawashima M, Nakahara Y, Funaki T, Mineta T. Stitched sling retraction technique for microvascular decompression: procedures and techniques based on an anatomical viewpoint. *Neurosurg Rev*. 2011;34(3):373-379-380. doi:10.1007/s10143-011-0310-0.
10. Wolters FJ, Rinkel GJE, Vergouwen MDI. Clinical course and treatment of vertebrobasilar dolichoectasia: a systematic review of the literature. *Neurol Res*. 2013;35(2):131-137. doi:10.1179/1743132812Y.0000000149.
11. Lin C-F, Chen H-H, Hernesniemi J, et al. An easy adjustable method of ectatic vertebrobasilar artery transposition for microvascular decompression. *Clin Neurol Neurosurg*. 2012;114(7):951-956. doi:10.1016/j.clineuro.2012.02.021.
12. Nakahara Y, Kawashima M, Matsushima T, et al. Microvascular decompression surgery for vertebral artery compression of the medulla oblongata: 3 cases with respiratory failure

- and/or dysphagia. *World Neurosurg.* 2014;82(3-4):535.e11-16. doi:10.1016/j.wneu.2014.01.012.
13. Tandon A, Chandela S, Langer D, Sen C. A novel sling technique for microvascular decompression of a rare anomalous vertebral artery causing cervical radiculopathy. *Neurosurg Focus.* 2013;35(3):E2. doi:10.3171/2013.6.FOCUS1339.
  14. Lee SH, Park JS, Ahn YH. Bioglue-Coated Teflon Sling Technique in Microvascular Decompression for Hemifacial Spasm Involving the Vertebral Artery. *J Korean Neurosurg Soc.* 2016;59(5):505-511. doi:10.3340/jkns.2016.59.5.505.
  15. Ubogu EE, Chase CM, Verrees MA, Metzger AK, Zaidat OO. Cervicomedullary junction compression caused by vertebral artery dolichoectasia and requiring surgical treatment. Case report. *J Neurosurg.* 2002;96(1):140-143. doi:10.3171/jns.2002.96.1.0140.
  16. Hongo K, Kobayashi S, Hokama M, Sugita K. Vertebral artery section for treating arterial compression of the medulla oblongata. Case report. *J Neurosurg.* 1993;79(1):116-118. doi:10.3171/jns.1993.79.1.0116.

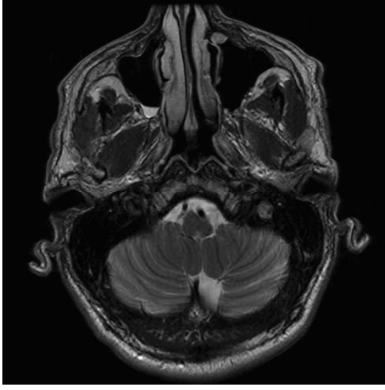
**Figure and video legend**

Figure 1. Preoperative images show the vertebral artery compressing the upper left medulla (Panel A) resulting in T2/FLAIR signal change in the right medullary pyramid (Panel B, white arrowhead). Digital subtraction angiography shows a mildly tortuous left vertebral artery.

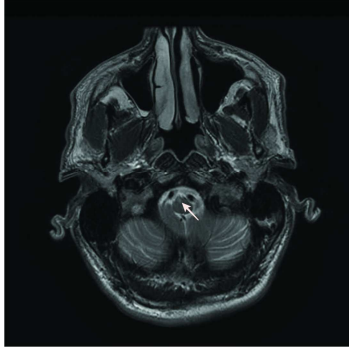
Figure 2. Intraoperative image showing the vertebral artery (white arrowhead) repositioned by a sling away from the medulla (black arrowhead).

Figure 3. Follow-up imaging shows decompression of the medulla (Panel A) and reduction of T2/FLAIR signal change (Panel B).

Video 1. Vertebral artery repositioning for decompression of medulla, Video.mov

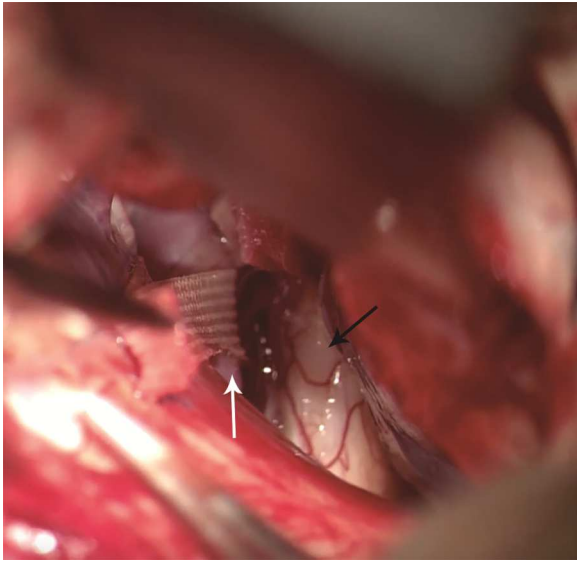


ACCEPTED MANUSCRIPT

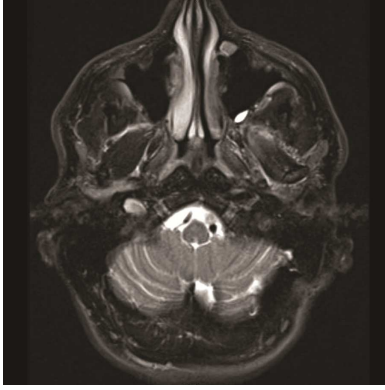


ACCEPTED MANUSCRIPT

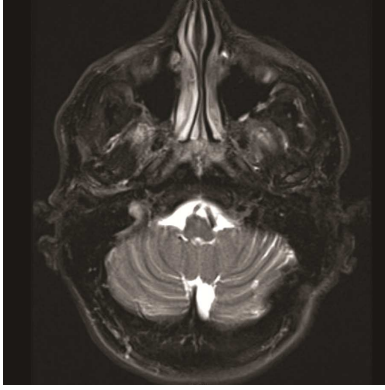




ACCEPTED MANUSCRIPT



ACCEPTED MANUSCRIPT



ACCEPTED MANUSCRIPT

### Highlights

- Hemiparesis secondary to medullary compression by the vertebral artery has been rarely reported
- The present case is only the fifth reported of its kind
- Vascular decompression using a sling has proven to be a valuable option for selected cases

Abbreviations

FLAIR: fluid-associated inversion recovery

MRA: magnetic resonance angiogram

MRI: magnetic resonance imaging

ACCEPTED MANUSCRIPT