

Received: 2017.03.02
Accepted: 2017.04.30
Published: 2017.09.15

A Case of Tranexamic Acid as Adjunctive Treatment for Chronic Subdural Hematoma with Multiple Recurrences

Authors' Contribution:
Study Design A
Data Collection B
Statistical Analysis C
Data Interpretation D
Manuscript Preparation E
Literature Search F
Funds Collection G

AEF 1 **Ronni Mikkelsen**
AEF 2 **Thorkil Anker-Møller**
AEF 2 **Anne-Mette Hvas**
AEF 1 **Niels Sunde**

1 Department of Neurosurgery, Aarhus University Hospital, Aarhus, Denmark
2 Centre for Haemophilia and Thrombosis, Department of Clinical Biochemistry, Aarhus University Hospital, Denmark

Corresponding Author: Ronni Mikkelsen, e-mail: ronni.mikkelsen@rm.dk
Conflict of interest: None declared

Patient: Male, 64
Final Diagnosis: Chronic subdural hematoma
Symptoms: Aphasia • headache • paresis
Medication: —
Clinical Procedure: Burr hole evacuation • Tranexamic acid
Specialty: Neurosurgery

Objective: Unusual clinical course


Background: Chronic subdural hematoma (CSDH) is a common neurosurgical condition that is treated using a cranial burr hole evacuation procedure, but recurrence is common. The use of anticoagulant therapy can increase the risk of developing a recurrent subdural hematoma. We present a challenging case of a patient on long-term anti-coagulant therapy following previous aortic and aortic valve surgery who had CSDH with multiple recurrences and was ultimately treated with tranexamic acid as an adjunct to surgery.

Case Report: A male patient in his mid-sixties presented with a headache and bilateral CSDH. Apart from a mechanical heart valve, he was otherwise healthy. A standard burr hole evacuation was performed, but the left hematoma and symptoms recurred after three months, and he presented with additional symptoms of aphasia and right-hand weakness. He had an additional three procedures followed by recurrences over a period of six weeks. Following his fifth and final surgical procedure, he was given postoperative intravenous tranexamic acid 10 mg/kg four times during the first 24 hours with dalteparin sodium 9,500 international units (IU) twice daily. His symptoms resolved, and after nine months he had no residual hematoma, and no thromboembolic complications occurred.

Conclusions: This case has demonstrated that tranexamic acid can be used as an adjunctive treatment to surgery when dealing with recurring CSDH, even in patients who require concomitant anticoagulant therapy. Although clinical trials are underway to evaluate tranexamic acid as a medical treatment for CSDH, this case report may support further studies that include patients with risk factors for thromboembolic disease.

MeSH Keywords: Hematoma, Subdural, Chronic • Recurrence • Tranexamic Acid

Full-text PDF: <https://www.amjcaserep.com/abstract/index/idArt/904117>



1620



—



2



7



Background

Chronic subdural hematoma (CSDH) is a common neurosurgical condition that is treated using a cranial burr hole evacuation procedure. However, recurrence is common, with recurrence rates reported to be between 3–33% [1]. For patients with risk factors for thromboembolic disease who require anticoagulant therapy, these patients have an increased risk of developing CSDH [2].

We present a challenging case of a patient requiring anticoagulant therapy due to previous aortic surgery and a mechanical aortic valve, who had CSDH with multiple recurrences and was ultimately treated with tranexamic acid following surgery. This case illustrates the possible use of tranexamic acid as an adjunct to normal burr hole evacuations in the setting of recurring CSDH, even in patients requiring anticoagulant therapy due to a high thromboembolic risk.

Case Report

Past medical history

A man in his mid-sixties had been treated with warfarin for several years following repair of a dissection of the ascending aorta (Stanford type A dissection) with an aortic prosthesis and a mechanical aortic valve replacement. The patient was otherwise healthy. However, although he made a good recovery from his previous cardiothoracic surgery, during his rehabilitation, a brain magnetic resonance imaging (MRI) scan showed a middle cerebral artery aneurysm measuring 6 mm, but cerebrovascular surgery was not considered to be indicated at that time.

Presentation and surgery

The patient presented to our neurosurgical department with a gradually worsening headache. A computed tomography (CT) scan showed bilateral isodense chronic subdural hematoma (CSDH) with a mass effect (Figure 1A). His international

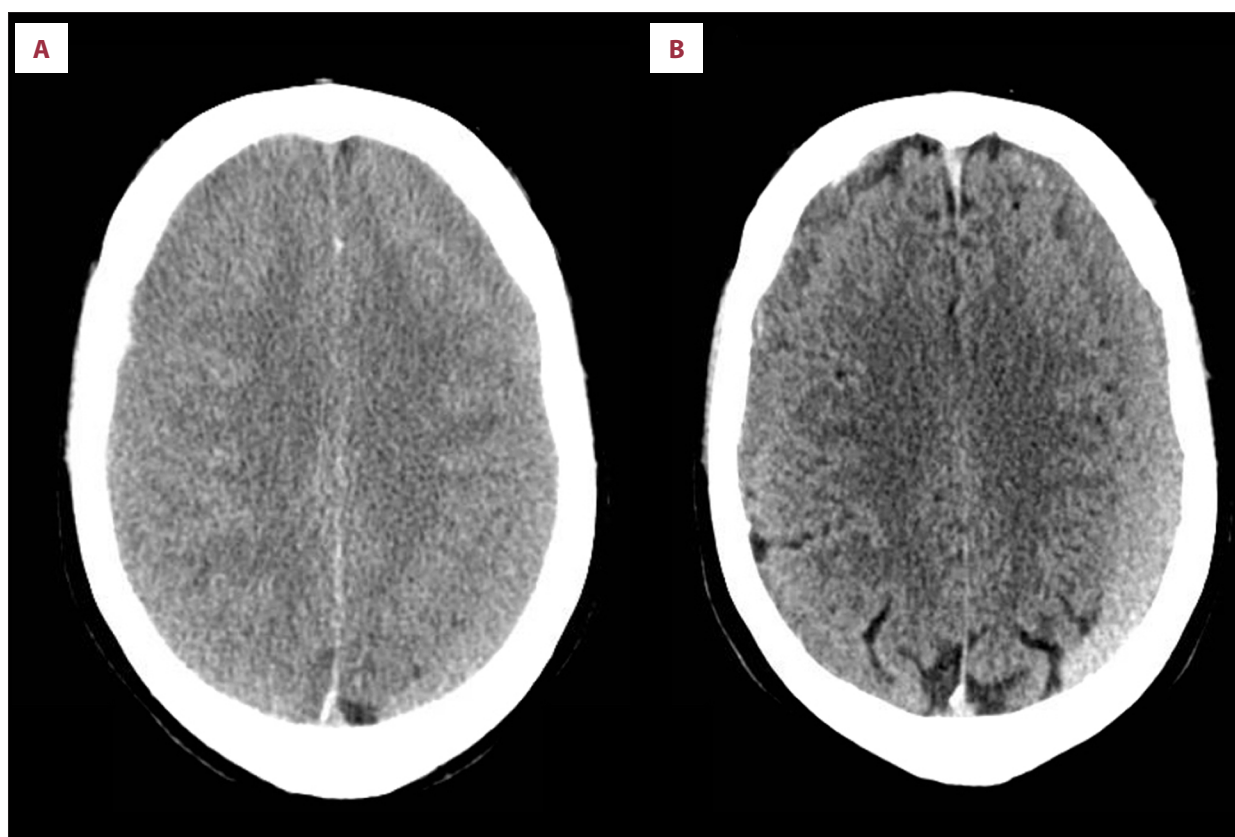


Figure 1. Computed tomography (CT) scan of bilateral chronic subdural hematoma (CSDH). (A) Computed tomography (CT) scan showing bilateral isodense chronic subdural hematoma (CSDH) with compression of the cerebral sulci. (B) CT scan six weeks after the first operation, showing reduced size of both hematomas, but with bilateral recurrence. The hematoma is compressing the left frontal lobe. The follow-up scans between this and the one prior to the fifth operation showed little difference.

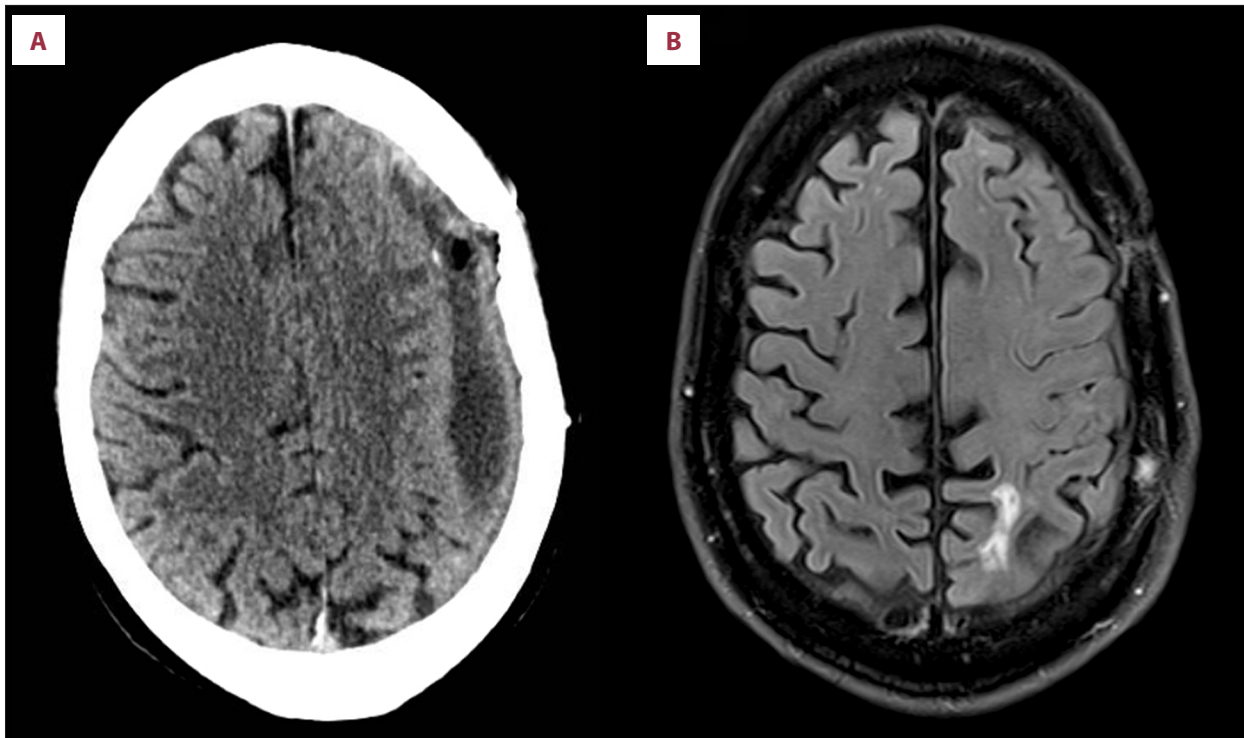


Figure 2. Computed tomography (CT) and magnetic resonance imaging (MRI) following surgery and treatment with tranexamic acid. (A) Computed tomography (CT) scan two weeks after surgery and treatment with tranexamic acid showing a small residual hematoma on the left side. (B) Magnetic resonance imaging (MRI) showing complete resolution of the hematomas, as well as a small parietal ischemic lesion.

normalized ratio (INR) was 5.8. His longstanding warfarin anticoagulation was discontinued, and he was given vitamin K and started a high dose dalteparin 7,500 international units (IU) twice daily.

After the first day of admission, his level of consciousness declined, and emergency evacuation of the right CSDH was performed through a burr hole, which is the standard procedure at our institute. Following this procedure, he regained consciousness without neurological deficit. The contralateral CSDH was treated the following day with a burr hole evacuation. He resumed warfarin therapy and was discharged from hospital.

Patient follow-up

At follow-up, six weeks after the operation, the patient was well without any neurological symptoms, although a CT-scan showed bilateral recurrent hematomas (Figure 1B). After one and a half months, the patient returned to our department with a headache and non-fluent aphasia. A CT-scan showed an unchanged right CSDH, with a slight increase in the size of the left CSDH, which compressed his left frontal lobe, explaining his symptoms. His INR was 2.5.

At the second operation, the left CSDH was evacuated using a burr hole, and his warfarin medication was switched to dalteparin during his hospital admission. Warfarin therapy was resumed following surgery. His symptoms initially improved after surgery, but then recurred with non-fluent aphasia and weakness of the right hand two weeks following surgery.

Two more burr hole operations were performed, but with a recurrence of symptoms within just a few days after each procedure. During the latter, i.e. fourth operation, the frontal burr hole was enlarged, and an abundance of membranes with little hematoma fluid was present.

Recurrence of CSDH and treatment with tranexamic acid

After recurring symptoms of aphasia and right-hand weakness a few days following his fourth operation, we consulted the department of clinical biochemistry and the department of cardiothoracic surgery. Following consultation, a decision was made to maintain the patient on dalteparin as anticoagulant therapy, make a new burr hole over the parietal area of the hematoma, as a fifth surgical procedure, and to treat the patient with 10 mg/kg tranexamic acid intravenously four times during the first 24 hours postoperatively, commencing just after the operation, while maintaining treatment with dalteparin.

The patient's symptoms resolved after the fifth operation, and the patient was discharged on dalteparin, adjusted to 9.500 IU twice daily in accordance with his body weight of 95 kg. The follow-up postoperative scan at two weeks showed a discrete residual hematoma (Figure 2A), but the patient had no symptoms. Six weeks after the last operation the patient was switched from dalteparin to warfarin anticoagulation.

Nine months following the fifth and final operation, follow-up MRI scan of the middle cerebral artery aneurysm showed no residual hematoma (Figure 2B) and the patient had no symptoms. The MRI scan showed small ischemic lesions in the parietal and occipital cortex, but the patient had no symptoms from these. Because no imaging was done between two weeks and nine months postoperatively, it is unclear when these ischemic lesions occurred. The patient did not experience symptoms of thromboembolism during his treatment.

Discussion

We present a case of a patient on anticoagulation therapy for thromboembolic risk, where multiple recurrences of CSDH was successfully treated with tranexamic acid following burr hole surgery.

In 2006, a study showed that the incidence of CSDH in patients on anticoagulant therapy was up to 42 times greater than in the non-anticoagulated population, and anticoagulant therapy should be considered to be a considerable risk factor for CSDH [2]. However, in the same study, the risk of re-evacuation procedures was similar among patients taking warfarin when compared with other patients [2]. In another study by Stanic et al. that included 99 patients with CSDH, they found no significant difference in recurrence rate after surgery among patients on anticoagulant therapy and non-anticoagulated patients [3]. In this study, anticoagulation treatment was discontinued before surgery and resumed four weeks after surgery unless strictly contraindicated [3].

A recent review of the surgical management of chronic subdural hematoma has also concluded that there were no statistically significant differences in the rates of recurrence between anticoagulated and non-anticoagulated patients, but that definitive clinical guideline recommendations for the management of anticoagulant treatment in these patients are also lacking [1]. We had a compelling reason to maintain our patient on anticoagulation treatment and therefore kept him on a therapeutic dose of dalteparin after discontinuation of warfarin, because of the concern that discontinuing his anticoagulant treatment could lead to a thromboembolic event. The choice of dalteparin was made to avoid unnecessary fluctuations in the patient's level of anticoagulation.

In 2013, Kageyama et al. studied 21 patients with CSDH treated with tranexamic acid without concomitant surgery over a period of 58 days and discussed the potential role of inhibition of the fibrinolytic and the inflammatory (kinin-kallikrein) systems when using tranexamic acid in CSDH [4]. This previous study reported that before treatment with tranexamic acid began, the median hematoma volume for all the 21 patients was 58.5 ml (range, 7.5–223.2 ml); for the 18 patients in the study who did not have surgery, the median hematoma volume was 55.6 ml (range, 7.5–140.5 ml), and after treatment with tranexamic acid, the median CSDH volume for the 21 patients studied was 3.7 ml (range, 0–22.1 ml) and no CSDH recurred [4]. However, patients taking warfarin were excluded from this study [4].

A large phase IIB randomized controlled clinical trial, the Tranexamic Acid (TXA) in Chronic Subdural Hematomas (TRACS) trial, is currently recruiting patients (NCT02568124) [5]. The aim of the TRACS trial is to investigate whether treatment with tranexamic acid can increase the resolution rate of CSDH following conservative management, reduce the number of surgical procedures, and reduce the rate of recurrence of CSDH following surgical evacuation [5]. However, patients receiving anticoagulant therapy will be excluded in this study [5].

In 2016, Tanweer et al. conducted a study of 14 patients with 20 CSDHs using treatment with oral tranexamic acid (650 mg daily) following the use of a bedside subdural evacuating port system (SEPS) [6]. This previous study showed a significant reduction of the hematoma size by 92% when compared with the presenting hematoma volume [6]. No adverse effects of tranexamic acid treatment were reported [6].

In this case report, we also found stabilization and resolution of the CSDH after a short treatment duration with tranexamic acid, with complete resolution of the patient's symptoms. We rationalized that giving tranexamic acid immediately following surgery would stabilize small bleeds from the membranes surrounding the hematoma and halt inflammation. We also decided that giving tranexamic acid at a dose of 10 mg/kg was safe, as this dose had been used without resulting in harmful effects in a previously reported randomized trial, the CRASH-2 Intracranial Bleeding Study [7].

In this reported case, the symptoms resolved after the initial treatment with tranexamic acid and we saw no reason for him to continue, given the risk of potential thromboembolic complications. However, the patient did develop two very small ischemic lesions in his parietal and occipital cortex at the nine-month follow-up scan, but the patient did not experience any symptoms from these lesions, and he did not have any thromboembolic symptoms. We only gave tranexamic acid for 24 hours following surgery, and we cannot be certain that

this is what prevented the patient from a further recurrence. Our patient suffered an ischemic lesion which could have given him a disability, had it been more severe. Therefore, caution and further studies are still needed on this topic, but we hope to add to the ongoing discussions by presenting this case.

This case report demonstrates our experience of managing a difficult case, but with a good clinical outcome. However, a single case report does not provide sufficient evidence upon which to make recommendations for future clinical practice, and this evidence awaits the outcome of controlled clinical trials.

References:

1. Ducruet AF, Grobelny BT, Zacharia BE et al: The surgical management of chronic subdural hematoma. *Neurosurg Rev*, 2012; 35(2): 155–69
2. Rust T, Kiemer N, Erasmus A: Chronic subdural haematomas and anticoagulation or anti-thrombotic therapy. *J Clin Neuroscience*, 2006; 13(8): 823–27
3. Stanisic M, Lund-Johansen M, Mahesparan R: Treatment of chronic subdural hematoma by burr hole craniostomy in adults: Influence of some factors on postoperative recurrence. *Acta Neurochir*, 2005; 147(12): 1249–56
4. Kageyama H, Toyooka T, Tsuzuki N, Oka K: Nonsurgical treatment of chronic subdural hematoma with tranexamic acid. *J Neurosurg*, 2013; 119(2): 332–37
5. Iorio-Morin C, Blanchard J, Richer M, Mathieu D: Tranexamic Acid in Chronic Subdural Hematomas (TRACS): Study protocol for a randomized controlled trial. *Trials*, 2016; 17(1): 235
6. Tanweer O, Frisoli FA, Bravate C et al: Tranexamic acid for treatment of residual subdural hematoma after bedside twist-drill evacuation. *World Neurosurg*, 2016; 91: 29–33
7. CRASH-2 Collaborators Intracranial Bleeding Study: Effect of tranexamic acid in traumatic brain injury: A nested randomised, placebo controlled trial (CRASH-2 Intracranial Bleeding Study). *BMJ*, 2011; 343: d3795

Conclusions

This case has demonstrated that tranexamic acid can be used as an adjunctive treatment to surgery when dealing with recurring CSDH, even in patients who require concomitant anticoagulant therapy. Although clinical trials are underway to evaluate tranexamic acid as a medical treatment for CSDH, this case report may support further studies that include patients with risk factors for thromboembolic disease.