

CASE REPORT

Chronic subdural haematoma presenting as freezing of gait

Kazuyuki Noda,¹ Nobutaka Hattori,² Yasuyuki Okuma,¹ Takuji Yamamoto³

¹Department of Neurology, Juntendo Shizuoka Hospital, Izunokuni, Shizuoka, Japan
²Department of Neurology, Juntendo University School of Medicine, Tokyo, Japan
³Department of Neurosurgery, Juntendo Shizuoka Hospital, Izunokuni, Japan

Correspondence to
 Dr Kazuyuki Noda,
 k-noda@juntendo.ac.jp

Accepted 15 September 2017

SUMMARY

In this report, we describe a case of freezing of gait (FOG) in a patient with chronic subdural haematoma (CSDH). An 81-year-old patient presented with progressive FOG about 6 weeks after a minor head trauma. MRI revealed CSDH in the left hemisphere, resulting in a marked compression of the hemisphere. His FOG disappeared after neurosurgical evacuation of the haematoma. It is suggested that the subdural haematoma in his left frontal cortices caused FOG. CSDH should be considered as a differential diagnosis when FOG develops after a head trauma in elderly patients, and prompt evaluations including neuroimaging and timely neurosurgical intervention are required.

BACKGROUND

Chronic subdural haematoma (CSDH) is one of the most common neurological disorders, and is especially prevalent among elderly individuals.¹ CSDH is an old collection of blood and blood breakdown products in the subdural space. Here, we describe the case of a patient with subacute freezing of gait (FOG) caused by CSDH whose FOG was improved after evacuation of the haematoma. Clinicians should pay close attention to CSDH as an important and treatable cause of FOG in elderly patients.

CASE PRESENTATION

An 81-year-old man developed progressive impairment of his gait and balance over approximately 3 weeks. Six weeks before the onset of his symptoms, he tripped during a walk and fell and hit his head on a concrete path. He had no history of diabetes mellitus or prior neuroleptic drug exposure. He had no significant family history of any neurological disorders. On examination, he was alert but apathetic. No aphasia, apraxia or agnosia was observed. His cranial nerves were intact except for bilateral age-related hearing loss. No rigidity or resting tremor was detected. His muscle strength and sensory were normal and cerebellar signs were absent. His deep tendon reflexes were normal and his plantar reflex was flexor bilaterally. He was able to initiate gait by himself but he has complete FOG, which begins with reduction of forward progression of the right foot (see online supplementary video 1).

INVESTIGATIONS

Brain MRI carried out immediately after the head trauma showed no abnormal findings except for age-related cortical atrophy (figure 1A,B). A laboratory work-up showed normal haematological and biochemical findings. His presurgical MR images showed CSDH in the left hemisphere resulting in a marked compression of the hemisphere (figure 1C,D). His brain MR images carried out 4 weeks after his operation revealed improvement of his subdural haematoma without recurrence (figure 1E,F).

DIFFERENTIAL DIAGNOSIS

The asymmetrical onset of his FOG may include cerebral infarction, cerebral haemorrhagic and a 'space occupying lesion' of some type (ie, abscess and tumour) for the differential diagnoses. These conditions could be ruled out on the basis of his brain MRI findings. The subacute progressive nature of his symptoms means that Parkinson's disease, progressive supranuclear palsy, Binswanger disease and idiopathic normal pressure hydrocephalus are the less likely diagnoses.

TREATMENT

He was immediately referred to the neurosurgical department of our hospital and the subdural haematoma was successfully evacuated by unilateral burr hole drainage.

OUTCOME AND FOLLOW-UP

Four days after his operation, his FOG disappeared (see online supplementary video 2). Four weeks after his operation, he fully recovered to his preoperative level of function without any sequelae such as headaches, impairment of gait and cognitive impairment caused by his CSDH.

DISCUSSION

Trauma is an important factor in the development of CSDH in the elderly. Nevertheless, not all patients with CSDH have a clear history of trauma, or trauma may have been minor. CSDH usually becomes symptomatic 21 days after a trauma on average. Old age is associated with cerebral atrophy and increased venous fragility.¹ The leading clinical features are headaches, an altered mental state or focal neurological symptoms, which in the absence of a clear history of head injury frequently lead to the erroneous diagnosis of stroke.¹ Several cases of parkinsonism caused by subdural haematomas have



CrossMark

To cite: Noda K, Hattori N, Okuma Y, et al. *BMJ Case Rep* Published Online First: [please include Day Month Year]. doi:10.1136/bcr-2017-221469

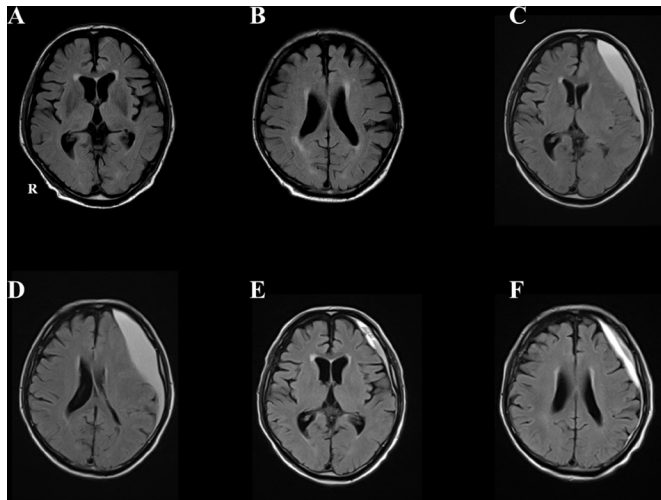


Figure 1 (A, B) Axial fluid-attenuated inversion recovery (FLAIR) images carried out immediately after the head trauma showing no structural lesions in basal ganglia and cerebral cortices. (C, D) Presurgical FLAIR images showing large subdural haematoma in the left convexity with marked compression of the left hemisphere. (E, F) FLAIR images carried out 4 weeks after his operation showing improvement of haematoma.

been reported, and some of these patients benefited from treatment with levodopa.²⁻⁴ To the best of our knowledge, cases of patients with FOG caused by CSDH have not been reported.

Recently, functional brain imaging techniques have been shown to be ideally suited for exploring the pathophysiology of FOG.⁵ The basic patterns of locomotion, that is, rhythmical leg movements, are generated in the spinal cord, which is innervated by supraspinal segments.⁶ This supraspinal control is necessary for initiating gait, turning, stopping or avoiding obstacles. The most important supraspinal regions involved in locomotion are the pontomedullary reticular formation, mesencephalic locomotor region, basal ganglia and frontal cortical regions.⁶ The development of FOG largely involves the frontal cortex, basal ganglia and locomotor centres in the midbrain.^{5,6} His left haematoma caused the direct mechanical compression of the frontal cortices or indirect compression of the basal ganglia caused by a midline shift. Subsequent alterations in the network of cortical areas such as the supplementary motor area, as well as subcortical areas such as the striatum and the locomotor regions may be the causative factors for his FOG. Recently, Fasano *et al* suggested that lesions causing FOG are heterogeneous and no single lesion could be considered necessary for symptom generation.⁷ They showed using a recently validated technique termed lesion network mapping that lesions causing FOG are located

within a common functional network characterised by connectivity to the cerebellar locomotor regions.⁷ Multiple lesions in different brain areas can cause FOG, but these areas are part of a common functional network connected to a focal area in the dorsal medial cerebellum. Further study is required to determine the pathophysiology of FOG.

In conclusion, our case clearly demonstrated that prompt evaluations including neuroimaging are crucial for accurate diagnosis and timely neurosurgical intervention for the complete resolution of FOG caused by CSDH.

Learning points

- ▶ Chronic subdural haematoma (CSDH) is one of the most common neurosurgical conditions in the elderly.
- ▶ Freezing of gait (FOG) is a brief, episodic marked reduction of forward progression of the feet despite the intention to walk.
- ▶ CSDH cases presenting as FOG have not been reported. Prompt evaluations and timely neurosurgical intervention for the complete resolution of FOG caused by CSDH are crucial.
- ▶ Disturbance of the dynamic network of frontal cortical areas, such as the supplementary motor area, basal ganglia and mesencephalic locomotor region including the pedunculo-pontine nucleus, is the possible cause of FOG.

Contributors KN and TY cared for the patient in the inpatient and in the outpatient settings. NH and YO reviewed the manuscript and provided suggestions. All the authors contributed to the writing of the manuscript, and read and approved the final version of the manuscript.

Competing interests None declared.

Patient consent Obtained.

Provenance and peer review Not commissioned; externally peer reviewed.

© BMJ Publishing Group Ltd (unless otherwise stated in the text of the article) 2017. All rights reserved. No commercial use is permitted unless otherwise expressly granted.

REFERENCES

- 1 Koliass AG, Chari A, Santarius T, *et al*. Chronic subdural haematoma: modern management and emerging therapies. *Nat Rev Neurol* 2014;10:570–8.
- 2 Ellul MA, Cross J, Barker RA. L-dopa responsive parkinsonism secondary to a subdural haematoma. *J Clin Neurosci* 2013;20:1022–4.
- 3 Bostantjopoulou S, Katsarou Z, Michael M, *et al*. Reversible parkinsonism due to chronic bilateral subdural hematomas. *J Clin Neurosci* 2009;16:458–60.
- 4 Gelabert-Gonzalez M1, Serramito-García R, Aran-Echabe E. Parkinsonism secondary to subdural haematoma. *Neurosurg Rev* 2012;35:457–60.
- 5 Fasano A, Herman T, Tessitore A, *et al*. Neuroimaging of freezing of gait. *J Parkinsons Dis* 2015;5:241–54.
- 6 Nutt JG, Bloem BR, Giladi N, *et al*. Freezing of gait: moving forward on a mysterious clinical phenomenon. *Lancet Neurol* 2011;10:734–44.
- 7 Fasano A, Laganieri SE, Lam S, *et al*. Lesions causing freezing of gait localize to a cerebellar functional network. *Ann Neurol* 2017;81:129–41.

Copyright 2017 BMJ Publishing Group. All rights reserved. For permission to reuse any of this content visit <http://group.bmj.com/group/rights-licensing/permissions>.

BMJ Case Report Fellows may re-use this article for personal use and teaching without any further permission.

Become a Fellow of BMJ Case Reports today and you can:

- ▶ Submit as many cases as you like
- ▶ Enjoy fast sympathetic peer review and rapid publication of accepted articles
- ▶ Access all the published articles
- ▶ Re-use any of the published material for personal use and teaching without further permission

For information on Institutional Fellowships contact consortiasales@bmjgroup.com

Visit casereports.bmj.com for more articles like this and to become a Fellow