

A Report of 2 Cases of Brainstem Hemorrhage After Suboccipital Craniectomy for Chiari Decompression

Sean P. Polster, MD*
 Mark C. Dougherty, BS*
 Hussein A. Zeineddine, MD*
 Seon-Kyu Lee, MD, PhD*
 David Frim, MD, PhD*

*Section of Neurosurgery, Department of Surgery, University of Chicago Medicine, Chicago, Illinois; †Section of Neuro-interventional Radiology, Department of Radiology, University of Chicago Medicine, Chicago, Illinois

Correspondence:

David Frim, MD, PhD,
 Section of Neurosurgery, Department of Surgery,
 University of Chicago Medicine,
 5841 S Maryland Ave,
 MC3026/Neurosurgery J341,
 Chicago, IL 60637.
 E-mail: dfrim@surgery.bsd.uchicago.edu

Received, January 3, 2017.

Accepted, May 22, 2017.

Published Online, July 11, 2017.

Copyright © 2017 by the
 Congress of Neurological Surgeons

BACKGROUND AND IMPORTANCE: Decompression surgery for Chiari malformation is known to have very low procedure-related complications. There has been no report of post-Chiari malformation decompression surgery development of brainstem hemorrhage. We report 2 post-Chiari decompression surgery brainstem hemorrhage cases with 2-yr follow-up.

CLINICAL PRESENTATION: Two cases were reviewed in which patients underwent uncomplicated suboccipital craniectomy with expansive autologous pericranium duraplasty for Chiari decompression. Postoperatively, both patients awoke with hemibody sensory and motor deficits. Immediate postoperative magnetic resonance imaging revealed a small hemorrhage within the dorsal medulla in both cases. Follow-up imaging shows resolution along with near complete clinical recovery of deficits.

CONCLUSION: These cases demonstrate a rare postdecompression surgery-related complication in Chiari malformation. We hypothesize that these hemorrhages may occur from the rapid drainage of cerebrospinal fluid resulting in a loss of positive pressure, allowing a low-pressure hemorrhage to occur. Given that these hemorrhages are of low pressure, recovery is excellent.

KEY WORDS: Brainstem hemorrhage, Chiari, Decompression, Case report

Operative Neurosurgery 14:E58–E62, 2018

DOI: 10.1093/ons/oxp146

Chiari malformation is a heterogeneous group of developmental anomalies that share the common feature of posterior fossa crowding secondary to ectopic cerebellar tissue at the foramen magnum.¹ Chiari I malformation is generally defined as caudal displacement of the cerebellar tonsils through the foramen magnum.^{2,3} The cause of Chiari I malformation is not fully understood, but certain factors seem to be associated with its development, including genetics, birth injury, female gender, and a history of trauma.⁴⁻⁶ Clinical indications for surgical decompression include downbeat nystagmus, signs of medullary compression (neurogenic dysphagia or neurogenic apnea), tussive suboccipital headaches, and syringomyelia.^{6,7}

Chiari decompression surgery is known to have very few procedure-related complications.⁸

In a Multicenter National Surgical Quality Improvement program database analysis, the overall postoperative complication rate from over 1400 Chiari decompression surgeries was reported at 5.3%, the majority being related to wound complication. Intraventricular hemorrhage occurred in 2 patients and death in 1. No report of intraparenchymal brainstem hemorrhage has been described. These findings are similar to numerous other series of Chiari decompression surgery.^{8,9}

Brainstem hemorrhage has not been reported in the setting of Chiari decompressive surgery, and hemorrhage in any location is very rare. Here, we report 2 similar cases of medullary hemorrhage with neurological deficit immediately after Chiari decompression with excellent recovery.

CLINICAL PRESENTATION

The local Institutional Review Board evaluated and approved this research. Patient consent was not required for this report.

ABBREVIATIONS: CSF, cerebrospinal fluid; MRI, magnetic resonance imaging

Case 1

A 46-yr-old woman with a history of spinal cord untethering presented with 3 yr of chronic debilitating occipital tussive headaches. Symptoms also included left-sided face, neck, and arm pain exacerbated by extension, flexion, and axial rotation of the neck. Imaging revealed Chiari I malformation (Figure 1A). The decision to intervene was based on cerebellar crowding along with the correlative symptoms. Suboccipital craniectomy, C1 laminectomy, and expansile pericranial duraplasty were performed. Intraoperatively, tonsillar crowding causing fourth ventricular outflow restriction was noted with arachnoid adhesions and a rhomboid roof. These were lysed as

part of the decompressive surgery; no intradural bleeding was observed, the dorsal pial plane of the medulla was not violated, and the procedure was completed without notable complication. Review of the anesthesia record showed no evidence of elevated systemic blood pressure or increased airway pressures during the operation.

The patient awoke from general anesthesia with left upper- and lower-extremity paresthesia and motor deficits, as well as left upper extremity dysmetria and decreased proprioception. Postoperative magnetic resonance imaging (MRI) of the brain and cervical spine revealed a small focus of left dorsal medullary hemorrhage with surrounding edema (Figures 1B-1E). The

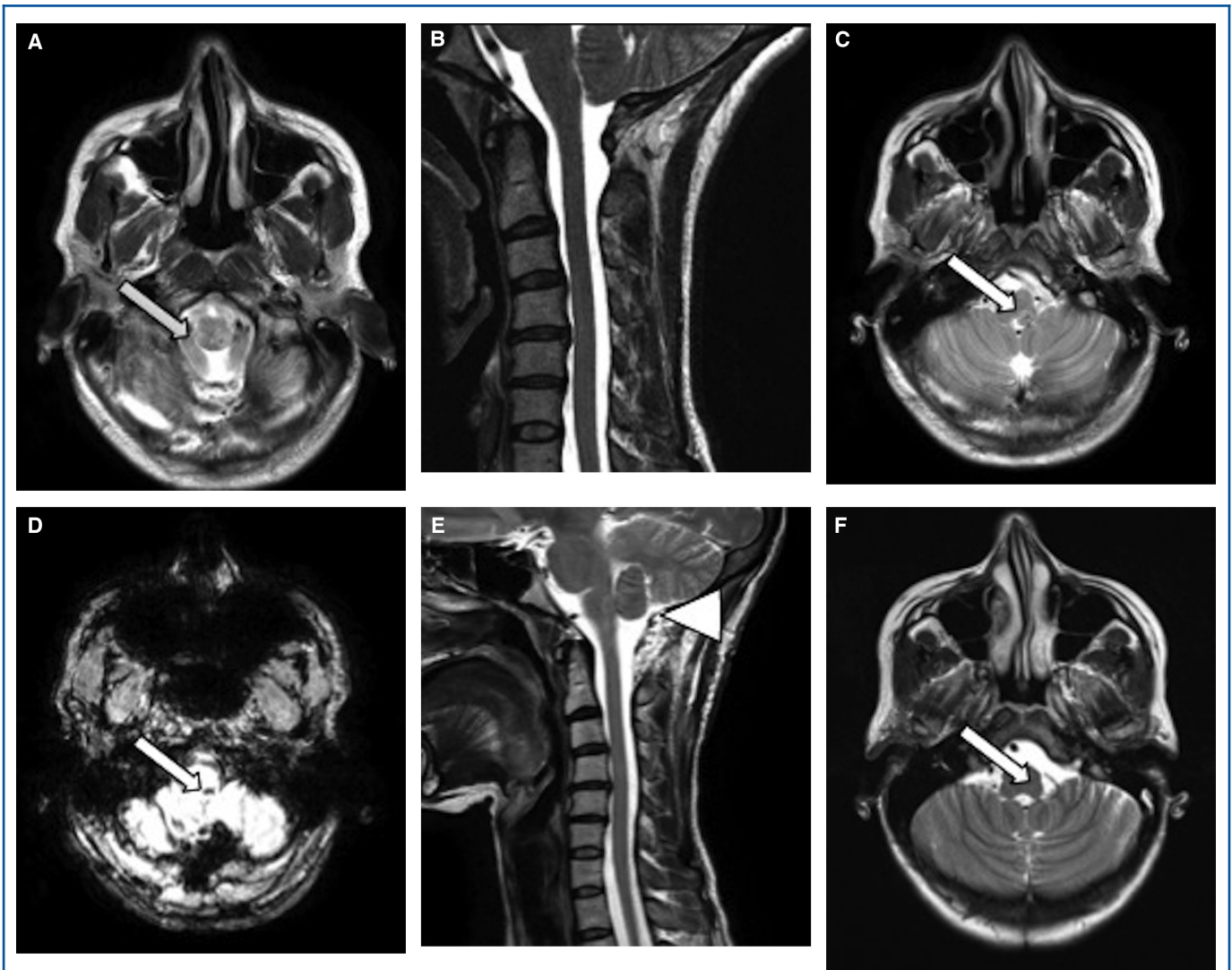


FIGURE 1. Case 1. **A** and **B**, Preoperative T2-MRI axial and sagittal section highlighting ectopic cerebellar tonsil (arrow, **A**) resulting in crowding of foramen magnum. Immediate postoperative MRI T2 axial **C**, SWI **D**, and sagittal **E** slices with left-side acute medulla hemorrhage (arrows in **C** and **D**), with successful tonsillar decompression (arrow head, **E**). Follow-up MRI T2 axial **F** section showing resolution of hemorrhage (arrow).

patient's symptoms were managed conservatively, and she was discharged to a rehabilitation facility after 8 d.

Follow-up examination at 2 wk showed improvement in head and neck pain but persistent mild left-sided weakness. Postoperative MRI at 3 mo showed resolution of the left dorsal medullary hemorrhage (Figure 1F). At 2 yr postoperatively, the patient reported virtually complete resolution of symptoms.

Case 2

A 30-yr-old woman with multiple orthopedic injuries of the upper and lower extremities related to an athletic past presented

to our clinic with a 2-yr history of diffuse head, neck, and back complaints. These included neuropathic pain in the neck and shoulders; midthoracic band-like pressure; tussive occipital headache; and intermittent nausea, vomiting, dizziness, photophobia, phonophobia, and tinnitus. She also reported 2 fainting episodes in the past year associated with elevation of her hands above her head. Her symptoms prompted neuroaxis imaging that revealed a Chiari I malformation with a thoracic syrinx (Figure 2A). The remainder of her neuroaxis imaging was normal.

The patient underwent suboccipital craniectomy, C1 laminectomy, and expansile pericranial duraplasty. Her operation

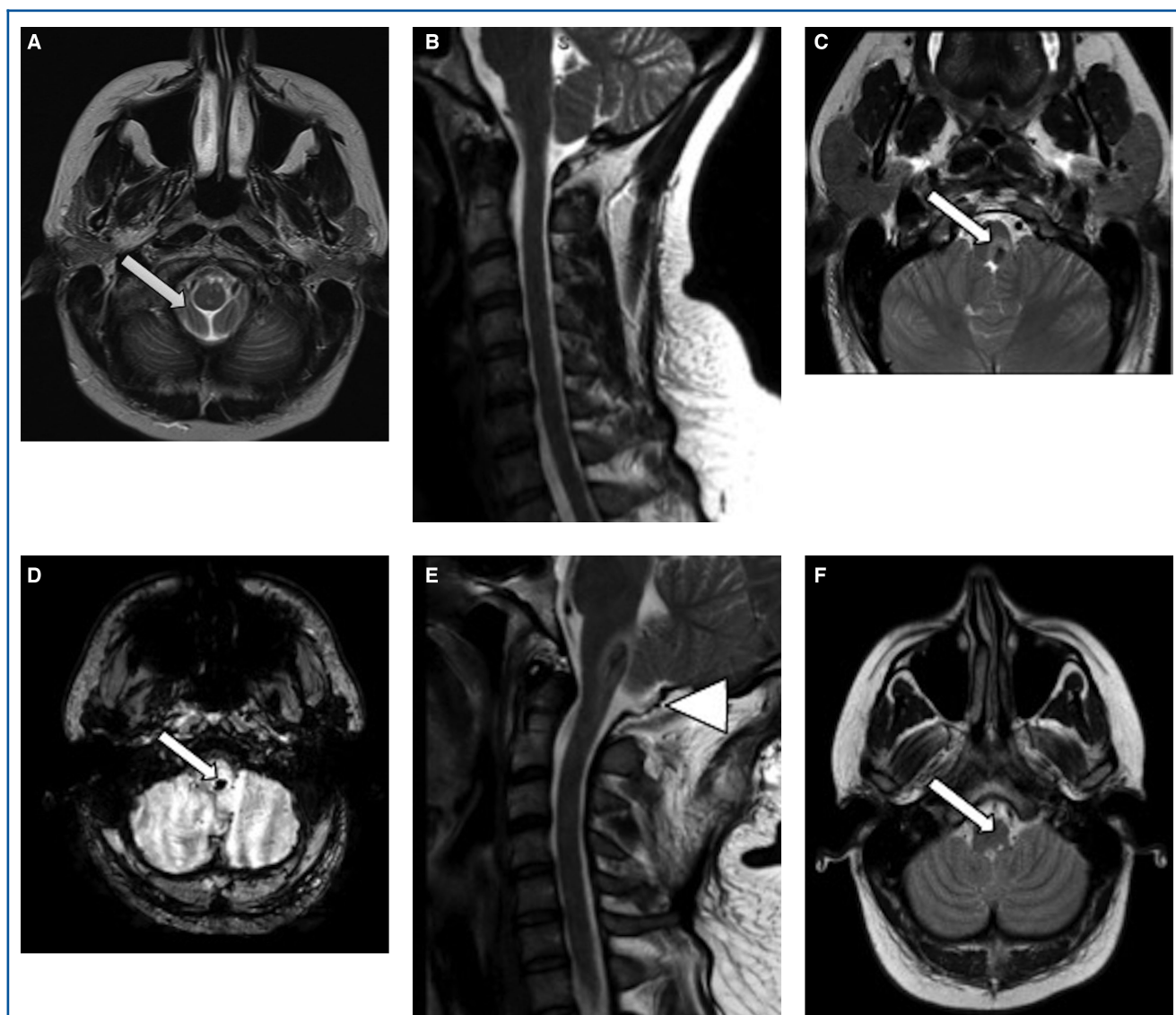


FIGURE 2. Case 2. **A and B**, Preoperative T2-MRI axial and sagittal section highlighting ectopic cerebellar tonsil (arrow, **A**) resulting in crowding of foramen magnum. Immediate postoperative MRI T2 axial **C**, SWI **D**, and sagittal **E** slices with left-side acute medulla hemorrhage (arrows in **C** and **D**) with successful tonsillar decompression (arrow head, **E**). Follow-up MRI T2 axial **F** section showing resolution of hemorrhage (arrow).

and anesthesia course were unremarkable, with no elevations in blood pressure or airway pressures during the case. In the hours following surgery, she began endorsing left-sided numbness and was found on exam to have 3/5 strength and dysmetria in her left upper extremity, as well as decreased sensation of the left hemibody. Postoperative head computed tomography was unremarkable, but subsequent MRI revealed acute hemorrhage of the left dorsal medulla with associated edema (Figures 2B-2E). She was discharged to an acute rehabilitation facility after 13 d, at which time her left-sided neurological symptoms had improved significantly.

Six weeks postoperatively, she still had mild left hand spasticity and left leg numbness. MRI showed resolution of the left dorsal medullary hemorrhage and edema with a small area of residual encephalomalacia (Figure 2F). The surgery was otherwise successful, with complete resolution of her head and neck pain. At 2-yr follow-up, she reported complete resolution of her postsurgical symptoms.

DISCUSSION

A review of the literature regarding complication rates of suboccipital decompression of Chiari I malformation, including case reports, shows a rate of about 4% to 6%, with some smaller studies in the pediatric population quoting up to 20%.¹⁰ The most commonly reported postoperative complications include pseudomeningocele, cerebrospinal fluid (CSF) leak, aseptic meningitis, wound infection, and meningitis.¹⁰ In a case series of 371 Chiari decompressions, postoperative hemorrhage was identified in only 2 patients (0.5%); 1 was attributed to systemic lupus.⁸ The only other intraparenchymal, nonbrainstem hemorrhage reported is in a single case report, published in 2011, in which a distal cerebellar hemorrhage in the setting of Chiari decompression occurred. The authors postulated stretching of the inferior cerebellar bridging veins as the etiology of the low-pressure hemorrhage.¹¹

Medullary hemorrhage as an isolated finding usually portends a poor prognosis.¹² However, our 2 cases after Chiari decompression surgery demonstrated significant neurological recovery compared to other causes of medullary hemorrhage. This may indicate a different pathophysiologic mechanism underlying the medullary hemorrhage seen in our cases.

One possible explanation is that a rapid or excessive drainage of CSF leads to significant intracranial hypotension. In both cases the arachnoid was inadvertently opened along with the dura. This is typically avoided because, in general, controlled opening of the arachnoid is preferred. Therefore, the CSF egress in these 2 cases was likely more abrupt than usual. As well, in both operations, the patients were prone, in headpin fixation, with the head slightly elevated above the heart. Another possible cause of distant hemorrhage could be elevated venous pressure produced by high ventilatory pressures at the time of CSF drainage. Careful review of the anesthesia record discounts this possibility, as there were

no unusual elevations in systemic blood pressure or ventilatory airway pressures.

Remote parenchymal bleeding after neurosurgical procedures has been previously described in the context of subdural hematoma evacuation, tumor resection, epilepsy operation, spine surgery, and cisternal entry for supratentorial vascular access. The commonality for cases reported with this type of complication is that CSF spaces were accessed abruptly and with presumably fast or excessive drainage. On the other hand, no reports were located for access via lumbar puncture or for procedures in which the CSF access was slow or of low volume. These observations may support our hypothesis.

Abrupt CSF drainage is a common factor between our reported cases and other reports of postprocedure brain parenchymal hemorrhage. This process may place the cerebral venous system under tension, resulting in collapse and, ultimately, venous insufficiency with hemorrhagic infarction.¹³⁻¹⁵ That the etiology of these reported hemorrhages is likely venous in origin is also supported by the recovery in our 2 patients—which was far more benign than that experienced by patients with hypertensive hemorrhage within the brainstem.

Typically, in the course of a decompression procedure, we incise the dura mater sharply with the intent of maintaining the superficial arachnoid plane so that dural tacking may take place in preparation for autograft application. If this is successfully achieved, as with most cases, then CSF loss occurs slowly prior to full access to the fourth ventricle. If the arachnoid plane is violated for various reasons, then CSF egress occurs over a much shorter time, leading to an abrupt change in intracranial pressure. This technical nuance may have prevented undue stress on the venous system and allowed for adequate equilibration of the intracranial pressures.

CONCLUSION

Medullary hemorrhage post-Chiari decompression is extremely rare. However, the clinical outcome of medullary hemorrhage from postdecompression hemorrhage appears to be favorable. The pathophysiology of such hemorrhages remains speculative, but care should be taken to decompress CSF spaces in a cautious and slow manner.

Disclosure

The authors have no personal, financial, or institutional interest in any of the drugs, materials, or devices described in this article.

REFERENCES

1. Koehler PJ. Chiari's description of cerebellar ectopy (1891). With a summary of Cleland's and Arnold's contributions and some early observations on neural-tube defects. *J Neurosurg.* 1991;75(5):823-826.
2. Rozenfeld M, Frim DM, Katzman GL, Ginat DT. MRI findings after surgery for Chiari malformation type I. *AJR Am J Roentgenol.* 2015;205(5):1086-1093.
3. Tubbs SR, OW. Introduction and classification of the chiari malformations. In: Tubbs SR, Oakes WJ, eds. *The Chiari Malformations*. New York: Springer; 2013.

4. Lacy M, Ellefson SE, DeDios-Stern S, Frim DM. Parent-reported executive dysfunction in children and adolescents with Chiari malformation type 1. *Pediatr Neurosurg*. 2016;51(5):236-243.
5. Fagan LH, Ferguson S, Yassari R, Frim DM. The Chiari pseudotumor cerebri syndrome: symptom recurrence after decompressive surgery for Chiari malformation type I. *Pediatr Neurosurg*. 2006;42(1):14-19.
6. Heiss JD. Epidemiology of the Chiari I malformation. In: Tubbs RS, Oakes WJ, eds. *The Chiari Malformations*. New York: Springer; 2013:83-92.
7. Heiss JD, Oldfield EH. Treatment of the adult Chiari I malformation. In: Tubbs RS, Oakes WJ, eds. *The Chiari Malformations*. New York: Springer; 2013:291-306.
8. Klekamp J. Surgical treatment of Chiari I malformation—analysis of intraoperative findings, complications, and outcome for 371 foramen magnum decompressions. *Neurosurgery*. 2012;71(2):365-380; discussion 380.
9. Hekman KE, Aliaga L, Straus D, et al. Positive and negative predictors for good outcome after decompressive surgery for Chiari malformation type 1 as scored on the Chicago Chiari Outcome Scale. *Neurol Res*. 2012;34(7):694-700.
10. Arnautovic A, Splavski B, Boop FA, Arnautovic KI. Pediatric and adult Chiari malformation type I surgical series 1965–2013: a review of demographics, operative treatment, and outcomes. *J Neurosurg Pediatr*. 2015;15(2):161-177.
11. Kaneko T, Koyanagi I, Murakami T. Remote cerebellar hemorrhage after foramen magnum decompression surgery for Chiari I malformation—case report. *Neurol Med Chir (Tokyo)*. 2011;51(2):134-136.
12. Barinagarrementeria F, Cantu C. Primary medullary hemorrhage. Report of four cases and review of the literature. *Stroke*. 1994;25(8):1684-1687.
13. Ziyal I, Bilginer B, Yavuz K, Turk C, Ozgur C, Benli K. Does ventricular opening promote remote cerebellar haemorrhage? *Turk Neurosurg*. 2012;22(1):102-104.
14. Friedman JA, Ecker RD, Piepgras DG, Duke DA. Cerebellar hemorrhage after spinal surgery: report of two cases and literature review. *Neurosurgery*. 2002;50(6):1361-1363; discussion 1363-1364.
15. Cohen-Gadol AA. Remote contralateral intraparenchymal hemorrhage after overdrainage of a chronic subdural hematoma. *Int J Surg Case Rep*. 2013;4(10):834-836.

COMMENT

Two cases are reported of unexplained early postoperative identification of medullary hemorrhage following uncomplicated foramen magnum decompression for Chiari malformation. Possible mechanisms are explored, and although some may take issue with the diagnosis of Chiari malformation in case 1, the important point is that foramen magnum decompression can provoke medullary hemorrhage. Both hemorrhages were small, and both resolved leaving minimal deficit, after rehabilitation only. This represents a novel complication of the operation, though the authors identified 3 previous reports of distant hemorrhage, none affecting the medulla, but 1 being in the “distal” cerebellum.

Surgeons need to be alert to this rare but serious complication of foramen magnum decompression, the mechanism for which remains obscure.

Owen Sparrow

Southampton, United Kingdom