


# Accepted Manuscript

Postoperative cerebral ischemia due to hypotension in a moyamoya patient with autonomic dysfunction: A case report

Toshio Machida, Yoshinori Higuchi, Shigeki Nakano, Satoshi Ishige, Junichiro Shimada, Koichi Honma



PII: S1878-8750(17)31679-0

DOI: [10.1016/j.wneu.2017.09.163](https://doi.org/10.1016/j.wneu.2017.09.163)

Reference: WNEU 6607

To appear in: *World Neurosurgery*

Received Date: 14 July 2017

Revised Date: 22 September 2017

Accepted Date: 23 September 2017

Please cite this article as: Machida T, Higuchi Y, Nakano S, Ishige S, Shimada J, Honma K, Postoperative cerebral ischemia due to hypotension in a moyamoya patient with autonomic dysfunction: A case report, *World Neurosurgery* (2017), doi: 10.1016/j.wneu.2017.09.163.

This is a PDF file of an unedited manuscript that has been accepted for publication. As a service to our customers we are providing this early version of the manuscript. The manuscript will undergo copyediting, typesetting, and review of the resulting proof before it is published in its final form. Please note that during the production process errors may be discovered which could affect the content, and all legal disclaimers that apply to the journal pertain.

**Title**

Postoperative cerebral ischemia due to hypotension in a moyamoya patient with autonomic dysfunction: A case report

Toshio MACHIDA<sup>1</sup>, Yoshinori HIGUCHI<sup>3</sup>, Shigeki NAKANO<sup>1</sup>, Satoshi ISHIGE<sup>1</sup>,  
Junichiro SHIMADA<sup>2</sup>, Koichi HONMA<sup>2</sup>

Department of <sup>1</sup>Neurosurgery and <sup>2</sup>Neurology, Chiba Cerebral and Cardiovascular Center, Ichihara City, Chiba, Japan

<sup>3</sup>Department of Neurological surgery, Chiba University Graduate School of Medicine, Chiba City, Chiba, Japan

Corresponding author: Dr. Toshio Machida

Department of Neurosurgery, Chiba Cerebral and Cardiovascular Center

575 Tsurumai, Ichihara City, Chiba 290-0512, Japan

Tel: +81 43688 3111; Fax: +81 43688 3032

E-mail: tmachida@ca2.so-net.ne.jp

**Key words**

autonomic dysfunction, ischemic complication, moyamoya disease, revascularization

## Abstract

**Background.** Hypotension is a significant risk factor for the development of ischemic complication following revascularization surgery for moyamoya disease (MMD).

However, it is currently unknown whether autonomic dysfunction also plays a role.

**Case description.** Here we report a case of MMD in which hypotension due to autonomic dysfunction caused postoperative cerebral ischemia. A 30-year-old female patient with MMD had a history of transient right hemiparesis following laughter. Single-photon emission computed tomography showed impaired cerebral blood flow (CBF) in both cerebral hemispheres and so she underwent revascularization surgery in her left cerebral hemisphere. She awoke from anesthesia uneventfully; however, 1 hour after the surgery her blood pressure suddenly dropped to 90/40 mmHg and she became comatose. A perfusion computed tomography scan demonstrated a widespread reduction in CBF in the left hemisphere. Bezold–Jarisch reflex was thought to be the cause of the hypotension. Following treatment with a vasopressor agent, her BP increased and her consciousness rapidly recovered. The reduced CBF had almost completely recovered the next day. Head-up tilt test conducted 2 weeks after surgery demonstrated latent vasopressor-type autonomic dysfunction, which was possibly another cause of the hypotension. She was discharged from the hospital, and the laughter-induced hemiparesis gradually resolved.

**Conclusion.** Situational neurological deterioration in patients with MMD suggests latent autonomic dysfunction, which may be a risk factor for postoperative ischemic complications.

## Text

### Introduction

Revascularization surgery is a therapeutic option for the treatment of moyamoya disease (MMD) and prevents future strokes.[1] However, approximately 5% of patients suffer ischemic complication during the early postoperative period.[2] Several risk factors, such as progressive disease, impaired cerebral blood flow (CBF), and unstable circulatory conditions,[3-5] have been reported for ischemia complications, but the role of autonomic dysfunction is currently unknown. Here, we report a case of a patient with MMD in which latent autonomic dysfunction and Bezold–Jarisch reflex may have caused postoperative ischemic complications.

### Case report

A 30-year-old woman had experienced transient right hemiparesis after laughing since childhood. She presented at a nearby clinic with dysphasia and motor weakness that had lasted for several days. Magnetic resonance imaging (MRI) demonstrated cerebral infarction in her left temporal lobe and occlusion of the terminal portion of the bilateral internal carotid artery (Fig. 1A, B). She was referred to our hospital for further examination and treatment. Digital subtraction angiography showed the occlusion of the terminal portion of the bilateral internal carotid artery and moyamoya vessels in the basal ganglia. Thus, she was diagnosed with stage III MMD according to the criteria of the Research Committee on Spontaneous Occlusion of the Circle of Willis of the Ministry of Health, Labor, and Welfare, Japan.[6] Single-photon emission computed tomography using N-isopropyl[123I]-p-iodoamphetamine with and without

acetazolamide showed marked decreases in cerebral blood flow (CBF) and cerebral vascular reserve capacity (CVRC) in both cerebral hemispheres (Fig. 1C, D). Superficial temporal artery to middle cerebral artery anastomosis with encephalo-myo-synangiosis was performed in the patient's left cerebral hemisphere under general anesthesia using propofol and fentanyl. The estimated blood concentration of propofol and the dosage of continuous fentanyl infusion were 2–3  $\mu\text{g/ml}$  and 0.1–0.2  $\mu\text{g/kg/min}$ , respectively. Intraoperative bispectral index, systolic blood pressure (BP), and heart rate (HR) were maintained at approximately 35, 110 mmHg, and 60 bpm, respectively. The anesthetic time was 4 h 55 min, and the total quantities of crystalloid infusion and urinary output were 1800 and 860 ml, respectively. Postoperative hemoglobin concentration decreased from 12.6 to 10.9 g/dl, and total blood loss was estimated at approximately 500 ml. The patient recovered from the anesthesia without exhibiting any new neurological symptoms and returned to the ward. BP and HR on admission were 110/60 mmHg and 70 bpm, respectively, which were almost the same as the preoperative values at resting condition (Fig. 2A). However, 20 minutes later she turned pale and demonstrated right hemiparesis and aphasia (Fig. 2B). An emergency brain MRI demonstrated no ischemic lesion and a patent bypass (Fig. 3A, B). However, a perfusion CT scan demonstrated a widespread reduction in CBF in the left cerebral hemisphere (Fig. 3C, D). Soon after the examinations, she felt nauseous, her BP and HR dropped to 90/50 mmHg and 48 bpm, respectively, and she became comatose. This loss of consciousness might be caused by widespread cerebral ischemia due to Bezold–Jarisch reflex, and so we placed her in the Trendelenburg position and rapidly administered 240 ml of red blood cells in an albumin solution with 5–10  $\mu\text{g/kg/min}$  of dopamine hydrochloride (Fig. 2C). However, this did not greatly increase

her BP. Therefore, we administered 2mg of ephedrine, following which her BP and HR rapidly increased to 180/85 mmHg and 100 bpm and she recovered consciousness (Fig. 2D). A perfusion CT scan performed the next day revealed almost normalized CBF (Fig. 3E), and her postoperative course was uneventful thereafter. Head-up tilt test was conducted 2 weeks after the surgery. Her systolic BP decreased from 112 to 53 mmHg by head-up tilt with normal elevation of HR, suggesting impaired vasoconstrictive activity (vasopressor type autonomic dysfunction) (Fig. 4). However, she did not suffer from symptoms that may be due to orthostatic hypotension, and she was discharged 3 weeks after the surgery. The laughter-induced hemiparesis gradually resolved thereafter.

## Discussion

Here, we report a case of MMD in which autonomic dysfunction may have played a critical role in the development of postoperative cerebral ischemia.

Both clinical and surgical risk factors have been postulated for the development of postoperative ischemic complication. The former includes older age, manifestations of ischemia, recent or recurrent strokes, frequent transient ischemic attacks (TIAs), progressive vascular stenosis, and presence of hemodynamic compromise, [2, 3, 5, 7]; the latter includes hypotension, hypocarbia, crying, and hypovolemia.[5, 8-10] In the current case, the patient demonstrated frequent TIAs and suffered severely impaired cerebral hemodynamics before surgery and was therefore thought to be a high-risk patient for the surgery. Therefore, the patient was carefully managed, and surgery was performed successfully. However, her BP dropped, and she became comatose after the surgery. Because her BP and HR simultaneously decreased after she developed nausea, the hypotension was considered to be caused by Bezold–Jarisch reflex. In addition,

head-up tilt test demonstrated insufficient vasoconstrictive activity against circulatory blood volume loss. Thus, we speculate that Bezold–Jarisch reflex together with latent impaired vasoconstrictive activity caused pronounced hypotension.

Interestingly, this patient had suffered from unique symptoms of hemiparesis following laughter. It has been reported that laughter may elicit the Bezold–Jarisch reflex.[11] That is, laughter increases intrathoracic pressure and reduces venous return to the heart, which stimulates both sympathetic and parasympathetic systems. In some patients whose parasympathetic response overrides the sympathetic response (Bezold–Jarisch reflex), laughter causes syncope (laughter syncope). In this patient, laughter ordinarily may have also elicited the reflex, and conceivably, with latent impaired vasoconstrictive reactivity, may have reduced CBF in her left hemisphere, with impaired hemodynamics. We speculate that the patient was prone to elicit the reflex; thus, situational neurological symptoms, such as laughter-induced hemiparesis, may be risk factors for ischemic complications after revascularization surgery for MMD.

### **Conclusions**

Situational neurological dysfunction, such as hemiparesis following laughter, may suggest latent autonomic malfunction; thus, careful postoperative management is mandatory for patients with such conditions.

### **Acknowledgments**

TM, SN, SI, JS, and KH performed the surgery, managed the postoperative course, and obtained any clinical data. TM and YH wrote the paper. All authors have read and approved the final manuscript.

This research did not receive any specific grant from funding agencies in the public, commercial, or not-for-profit sectors.



### Figure legends

Fig. 1. Preoperative radiological examinations.

A: Fluid attenuated inversion recovery image showing cerebral infarction in the left temporal lobe. B: Magnetic resonance angiography showing the occlusion of the bilateral internal carotid artery and the proliferation of moyamoya vessels. C, D: Preoperative single-photon emission computed tomography with (C) and without (D) acetazolamide showing decreased cerebral blood flow and impaired vascular reserve capacity, particularly in the left cerebral hemisphere.

Fig. 2. Serial changes in postoperative blood pressure, heart rate, and Glasgow Coma Scale score.

(A) Upon admittance to the ward. (B) After the patient exhibited right hemiparesis and aphasia, when magnetic resonance imaging and computed tomography scans were performed. (C) After the patient became comatose, when red blood cells in an albumin solution with dopamine started to be administered. (D) When ephedrine started to be administered. E: eye opening; V: verbal response; M: motor response; sBP: systolic blood pressure; dBP: diastolic blood pressure; HR: heart rate.

Fig. 3. Postoperative radiological examinations.

A: Diffusion weighted image 1 hour after surgery showing no ischemic lesions. B: Magnetic resonance angiography showing the patent bypass (arrow). C: Computed tomogram perfusion image (pCT) before surgery showing no laterality in cerebral blood flow (CBF). D: pCT performed 1 hour after the surgery demonstrating widespread reductions in CBF in the left cerebral hemisphere (arrow), except for the region around

the anastomosis site (arrowhead). E: Follow-up pCT the next day showing recovered CBF.

Fig. 4. Head-up tilt test performed 2 weeks after the surgery.

Pronounced decrease in systolic blood pressure (sBP) by head-up tilt, with increase in heart rate and delayed recovery of BP (arrow). sBP: systolic blood pressure, dBP: diastolic blood pressure, HR: heart rate.

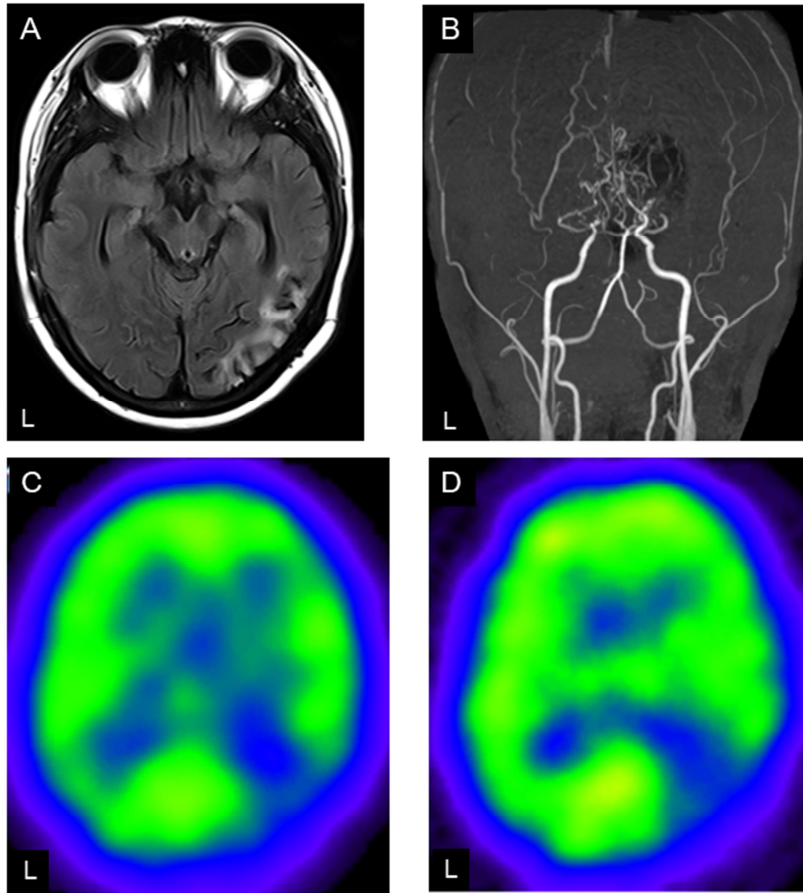
## References

- [1] Kuroda S, Houkin K. Moyamoya disease: current concepts and future perspectives. *Lancet Neurol.* 2008;7(11):1056-66.
- [2] Kazumata K, Ito M, Tokairin K, Ito Y, Houkin K, Nakayama N, Kuroda S, Ishikawa T, Kamiyama H. The frequency of postoperative stroke in moyamoya disease following combined revascularization: a single-university series and systematic review. *J. Neurosurg.* 2014;121(2):432-40.
- [3] Funaki T, Takahashi JC, Takagi Y, Kikuchi T, Yoshida K, Mitsuhara T, Kataoka H, Okada T, Fushimi Y, Miyamoto S. Unstable moyamoya disease: clinical features and impact on perioperative ischemic complications. *J. Neurosurg.* 2015;122(2):400-7.
- [4] Iwama T, Hashimoto N, Tsukahara T, Murai B. Peri-operative complications in adult moyamoya disease. *Acta Neurochir. (Wien.)* 1995;132(1-3):26-31.
- [5] Sato K, Shirane R, Yoshimoto T. Perioperative factors related to the development of ischemic complications in patients with moyamoya disease. *Childs Nerv. Syst.* 1997;13(2):68-72.
- [6] Research Committee on the P, Treatment of Spontaneous Occlusion of the Circle of W, Health Labour Sciences Research Grant for Research on Measures for Infractable D. Guidelines for diagnosis and treatment of moyamoya disease (spontaneous occlusion of the circle of Willis). *Neurol. Med. Chir. (Tokyo)* 2012;52(5):245-66.
- [7] Kim SH, Choi JU, Yang KH, Kim TG, Kim DS. Risk factors for postoperative ischemic complications in patients with moyamoya disease. *J. Neurosurg.* 2005;103(5 Suppl):433-8.
- [8] Jung YJ, Ahn JS, Kwon do H, Kwun BD. Ischemic complications occurring in the contralateral hemisphere after surgical treatment of adults with moyamoya disease. *J. Korean Neurosurg. Soc.* 2011;50(6):492-6.
- [9] Sakamoto T, Kawaguchi M, Ohnishi H, Touho H, Karasawa J, Furuya H, Okuda T. [Preoperative sedation for childhood moyamoya disease--clinical evaluation of rectally administered midazolam]. *Masui* 1994;43(5):781-5.
- [10] Nomura S, Kashiwagi S, Uetsuka S, Uchida T, Kubota H, Ito H. Perioperative management protocols for children with moyamoya

- disease. Childs Nerv. Syst. 2001;17(4-5):270-4.
- [11] Kim AJ, Frishman WH. Laughter-induced syncope. Cardiol. Rev. 2012;20(4):194-6.

ACCEPTED MANUSCRIPT

Figure 1



ACCEPTED

Figure 2

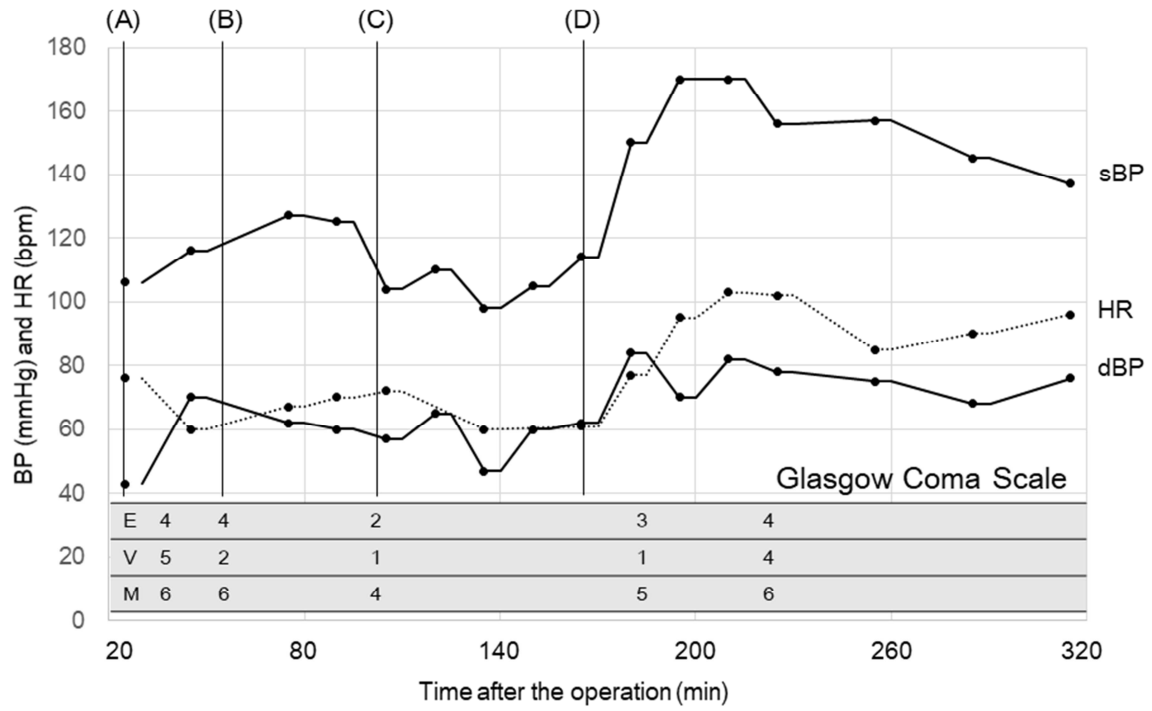


Figure 3

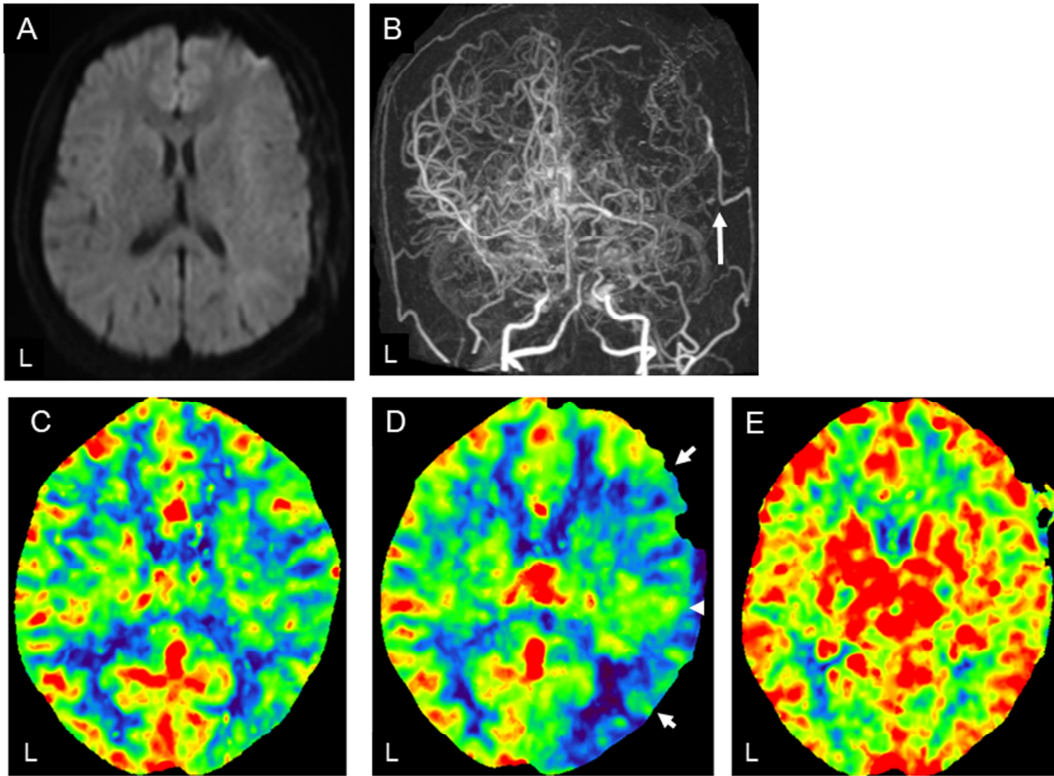
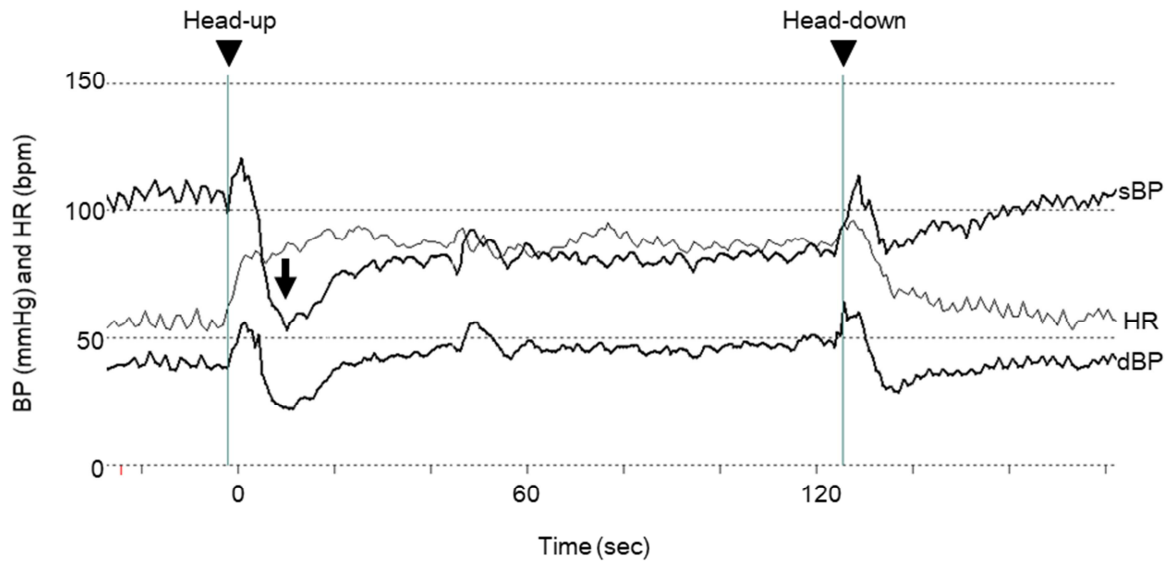


Figure 4



ACCEPTED



**Highlights**

- Laughter-induced TIA via parasympathetic activation.
- Patients with autonomic dysfunction are prone to postoperative hypotension.
- Autonomic dysfunction is a risk factor for postoperative ischemic complication.

**Abbreviations**

BP: blood pressure

CBF: cerebral blood flow

CT: computed tomography

CVRC: cerebral vascular reserve capacity

HR: heart rate

MMD: moyamoya disease

MRI: magnetic resonance imaging

SPECT: single-photon emission computed tomography

TIA: transient ischemic attack