

Received: 2017.05.16
Accepted: 2017.06.22
Published: 2017.10.09

Moyamoya Disease in an 18-Month-Old Female Caucasian Complicated by Cerebral Hyperperfusion Syndrome Following Indirect Revascularization

Authors' Contribution:

Study Design A
Data Collection B
Statistical Analysis C
Data Interpretation D
Manuscript Preparation E
Literature Search F
Funds Collection G

AEF 1 **James Murchison**
E 2 **John M. Wilson**
AE 2 **Coby Ray**
EF 2 **Jessica Ginsberg**
ABCDE 3 **Laszlo Nagy**

1 Baylor Scott and White Medical Center, Temple, TX, U.S.A.

2 Texas Tech University Health Sciences Center School of Medicine, Lubbock, TX, U.S.A.

3 Department of Pediatrics, Texas Tech University Health Sciences Center School of Medicine, Lubbock, TX, U.S.A.

Corresponding Author: James Murchison, e-mail: James.Murchison@bswhealth.org
Conflict of interest: None declared

Patient: Female, 18-month-old
Final Diagnosis: Moyamoya disease
Symptoms: Seizures
Medication: —
Clinical Procedure: —
Specialty: Neurosurgery

Objective: Rare co-existence of disease or pathology

Background: Cerebral hyperperfusion syndrome is a rare complication of indirect revascularization due to moyamoya disease, but has not been reported previously in the pediatric population. We present a case of an 18-month-old girl with moyamoya disease that was treated with bilateral pial synangiosis and had complications consistent with cerebral hyperperfusion syndrome. This case report discusses the pathophysiological mechanisms involved in cerebral hyperperfusion in moyamoya syndrome.

Case Report: An 18-month-old female Caucasian presented with seizures and weakness of the left side. Angiography confirmed bilateral cerebral moyamoya disease that was worse on the right side. Indirect revascularization with pial synangiosis was first performed on the right side to allow for healing. Five months later, pial synangiosis was then performed on the left side. Postoperatively, the patient experienced increased intracranial pressure (ICP), suggesting cerebral hyperperfusion syndrome. She was treated with a repeat lumbar puncture, a lumbar drain, and a lumbar shunt.

Conclusions: This report demonstrates a case of cerebral hyperperfusion syndrome as a complication of moyamoya disease in a pediatric patient. Although the patient progressed well after placement of a lumbar shunt, this case demonstrates the occurrence of cerebral hyperperfusion syndrome as a complication of revascularization in pediatric patients and highlights the need for further research in this area.

MeSH Keywords: Moyamoya Disease • Neurosurgery • Pseudotumor Cerebri

Full-text PDF: <https://www.amjcaserep.com/abstract/index/idArt/905325>



970



—



4



10



Background

Moyamoya disease includes spontaneous occlusion of the vessels of the Circle of Willis, and was first described in Japan in 1957, but later named in 1969 after the Japanese term for 'puff of smoke,' to describe the imaging appearance seen on angiography [1,2]. In Japan, moyamoya disease has a very low incidence of 0.35 per 100,000, and its incidence is even lower in the United States, at 0.086 per 100,000 [3,4]. Treatment for moyamoya disease is surgical and involves either direct or indirect revascularization [5].

Cerebral hyperperfusion syndrome is a complication of the revascularization procedures required for the treatment of moyamoya disease [6]. Hyperperfusion syndrome results in symptoms of increased intracranial pressure (ICP), most likely due to the sudden increase in cerebral blood flow. In patients treated for moyamoya disease, the complication of hyperperfusion syndrome has been reported mainly in adult patients and those treated with a direct revascularization procedure [6,7].

We present a case of an 18-month-old girl with moyamoya disease that was treated with bilateral pial synangiosis with complications consistent with cerebral hyperperfusion syndrome. This case report discusses the pathophysiological mechanisms involved in cerebral hyperperfusion and moyamoya syndrome.

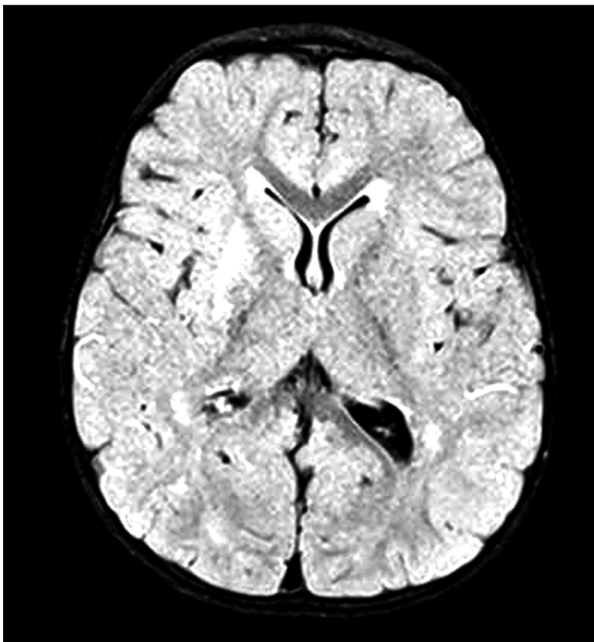


Figure 1. Axial fluid-attenuated inversion recovery magnetic resonance imaging (MRI) on the first presentation of a patient with moyamoya disease. The image shows hyper intense foci in right basal ganglia as a result of decreased perfusion from moyamoya disease.

Case Report

An 18-month-old Caucasian female presented with seizures and weakness of the left side during late October. Diagnostic imaging with angiography confirmed bilateral moyamoya disease that was worse on the right side (Figures 1, 2). Due to the small diameter of the superficial temporal arteries, direct revascularization was not an option for the patient.

Indirect revascularization with pial synangiosis was first performed on the right side in December of the same year. Angiography was performed postoperatively and showed viable collaterals and increased rate of occlusion of the right internal carotid artery (ICA) following the procedure. Also following the first procedure, the patient developed a sub-galea fluid collection over the incision site, but this resolved spontaneously.

Pial synangiosis was then performed on the left side in May of the following year, to allow for healing and maturation of first procedure. Angiography performed postoperatively showed viable collateral vessels. After the second procedure, the patient again developed a fluid collection, but this time, over the second incision site, which eventually leaked and became infected with *Pseudomonas aeruginosa*. This infected fluid collection required surgical washout and treatment with intravenous (IV) cefepime. During the washout procedure, ultrasound imaging was used and showed viable collateral vessels associated with the left-sided anastomosis, four weeks after the procedure (Figure 3A, 3B).

In addition to the fluid collection, the patient also experienced new left-sided headaches, which, together with the repeated fluid collections, were due to elevated intracranial pressure (ICP). The patient was diagnosed with cerebral hyperperfusion

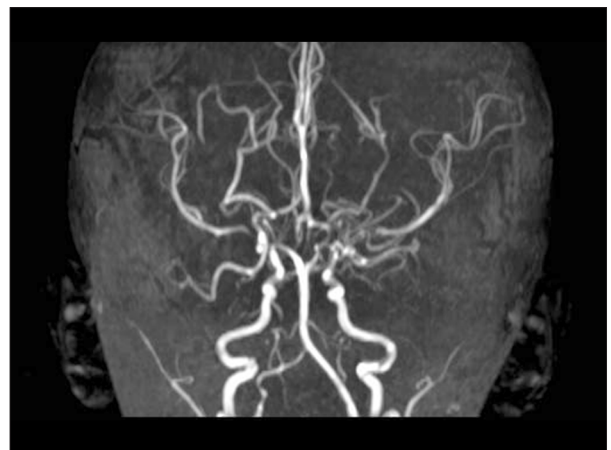


Figure 2. Three-dimensional (3D) magnetic resonance angiography (MRA) shows bilateral moyamoya disease that is more severe on the right side

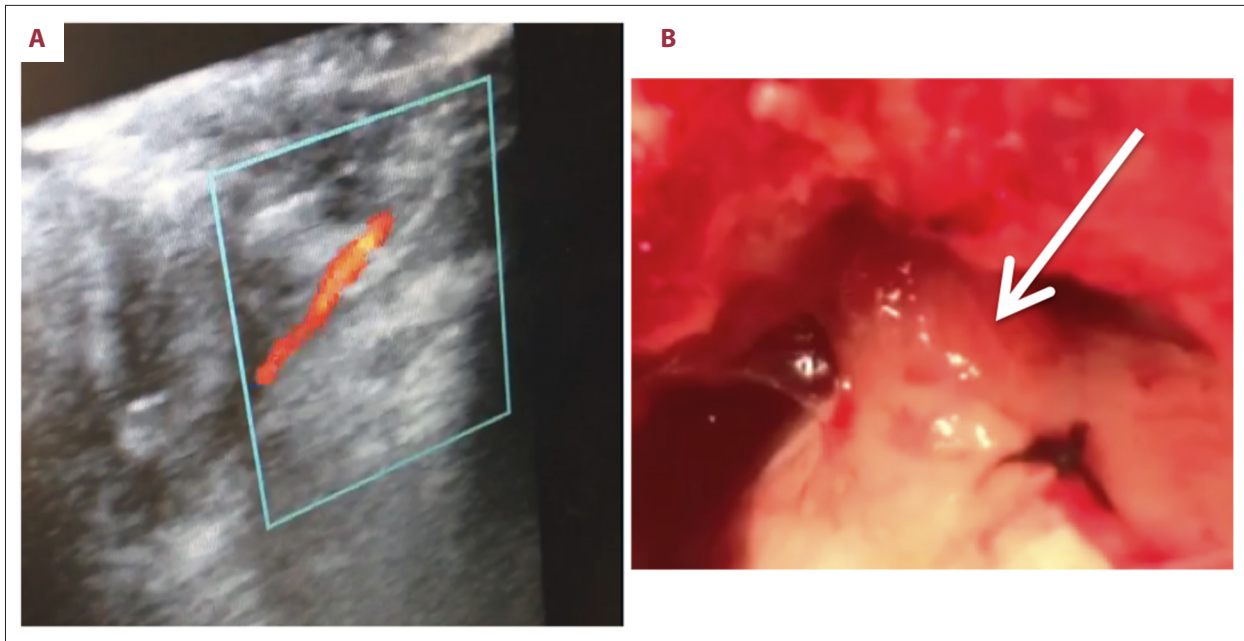


Figure 3. Pial syngangiosis during washout showing viable collateral vessels on the left side. (A) Ultrasound of pial syngangiosis during washout showing viable collateral vessels on the left side. (B) Photographic image of the intraoperative pial syngangiosis on the left side during washout. The arrow indicates the vessel.

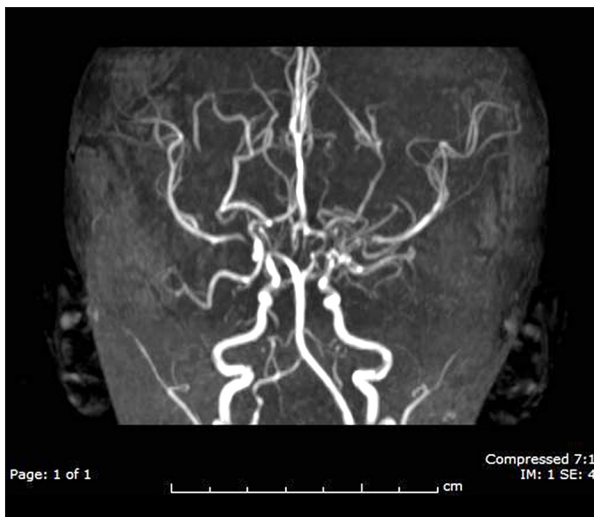

Figure 4. Three-dimensional (3D) magnetic resonance angiography (MRA) following bilateral pial syngangiosis demonstrates viable collaterals on both sides.

syndrome based on the symptoms, intraoperative findings, and ultrasound imaging findings. Because the patient did not have elevated blood pressure, she was initially treated with repeated lumbar punctures and lumbar drain rather pressure-lowering medication. The clinical expectation was that she had a transient condition, but the patient continued to have elevated ICP on monitoring (>25 mm Hg) and required a permanent lumbar shunt. The patient has been followed-up regularly in the outpatient clinic and has been doing well (Figure 4).

Discussion

Treatment for moyamoya disease is surgical and involves either a direct or indirect revascularization [5]. Direct revascularization involves anastomosis to the middle cerebral artery (MCA) and provides immediate benefit [5]. Indirect revascularization requires the mobilization of vascularized tissue and their placement in contact with the pia to allow new vessels to form and can take between three and four months for benefit to develop [5]. New surgical techniques for moyamoya disease now involve a combination of both indirect and direct revascularization [5].

Cerebral hyperperfusion syndrome is a complication of the revascularization procedures that are required for the treatment of moyamoya disease [6]. Cerebral hyperperfusion syndrome has a multifactorial etiology that includes impaired autoregulation of cerebral blood flow, damage to the blood-brain barrier, free radical damage, and baroreceptor dysfunction [8]. In patients treated for moyamoya disease, the complication of cerebral hyperperfusion syndrome has been reported mainly in adult patients and those treated with direct revascularization procedures, but not in children and those treated with an indirect revascularization [6,9]. The treatment of cerebral hyperperfusion syndrome usually involves strict blood pressure control [9]. In this case, the patient's intracranial pressure (ICP) remained elevated in spite of well-controlled blood pressure and was ultimately treated with a lumbar shunt.

This case is an example of a pediatric patient with moyamoya disease who developed cerebral hyperperfusion syndrome following indirect revascularization, which we believe to be a previously unreported association [9]. Recognition of the possible complication of cerebral hyperperfusion syndrome in this population is important for their postoperative care. We suggest more studies be done to determine the possible risk factors and causes of this complication in the pediatric population with moyamoya disease.

A further finding of interest in this case was the increased progression of vascular occlusion following the revascularization procedure on the right side. A possible reason for the increased progression of vascular occlusion may be a decrease in the production of angiogenic factors due to improved blood flow to the brain parenchyma from the revascularization procedure [10]. Previous studies have used imaging with transcranial Doppler (TCD) to diagnose moyamoya disease, and TCD

could be used in the follow-up of patients following revascularization procedures [10]. Future studies should be performed that include measurement and comparison of flow using TCD of the affected vessel and collaterals before and after revascularization to investigate the mechanisms of hyperperfusion syndrome and vascular occlusion.

Conclusions

This report has presented a pediatric case of cerebral hyperperfusion syndrome as a complication of moyamoya disease. Although the patient progressed well after placement of a lumbar shunt, this case demonstrates the occurrence of cerebral hyperperfusion syndrome as a complication of revascularization in pediatric patients and highlights the need for further research in this area.

References:

1. Takeuchi K, Shimizu K: Hypoplasia of the bilateral internal carotid arteries. *Brain Nerve*, 1957; 9: 37–43
2. Suzuki J, Takaku A: Cerebrovascular “moyamoya” disease. Disease showing abnormal net-like vessels in base of brain. *Arch Neurol*, 1969; 20(3): 288–99
3. Wakai K, Tamakoshi A, Ikezaki K et al: Epidemiological features of moyamoya disease in Japan: findings from a nationwide survey. *Clin Neurol Neurosurg*, 1997; 99(Suppl. 2): S1–5
4. Uchino K, Johnston SC, Becker KJ, Tirschwell DL: Moyamoya disease in Washington State and California. *Neurology*, 2005; 65(6): 956–58
5. Smith JL: Understanding and treating moyamoya disease in children. *Neurosurg Focus*, 2009; 26(4): E4
6. Hayashi K, Horie N, Suyama K, Nagata I: Incidence and clinical features of symptomatic cerebral hyperperfusion syndrome after vascular reconstruction. *World Neurosurg*, 2012; 78(5): 447–54
7. Wang K-C, Phi JH, Lee JY et al: Indirect revascularization surgery for moyamoya disease in children and its special considerations. *Korean J Pediatrics*, 2012; 55(11): 408–13
8. Farooq MU, Goshgarian C, Min J, Gorelick PB: Pathophysiology and management of reperfusion injury and hyperperfusion syndrome after carotid endarterectomy and carotid artery stenting. *Exp Transl Stroke Med*, 2016; 8(1): 7
9. Scott RM, Smith JL, Robertson RL et al: Long-term outcome in children with moyamoya syndrome after cranial revascularization by pial synangiosis. *J Neurosurg*, 2004; 100(2 Suppl Pediatrics): 142–49
10. Ruan LT, Duan YY, Cao TS et al: Color and power Doppler sonography of extracranial and intracranial arteries in Moyamoya disease. *J Clin Ultrasound*, 2006; 34(2): 60–69