

CASE REPORT

Scorpion bite-induced ischaemic stroke

Rakesh Reddy C,¹ Nandakishore Bompelli,¹ Vikram Khardenavis,² Anirudda Deshpande³¹Department of Internal Medicine, Aditya Hospital, Warangal, Telangana, India²Department of Medicine, Miraj Medical College, Miraj, Maharashtra, India³Department of Neurology, Vinayaka Neuro Multispecialty Clinic, Warangal, India**Correspondence to**

Dr Anirudda Deshpande, dr.anirudda.deshpande@gmail.com

Accepted 15 September 2017

SUMMARY

We report a 54-year-old woman with scorpion bite. After 3 hours of admission, the patient developed sudden onset tachycardia with hypotension. Cardiac evaluation showed raised creatine kinase MB isoenzyme was elevated; ECG and two-dimensional echocardiography findings were suggestive of myocarditis. Subsequently, she developed transient ventricular tachycardia before developing abrupt onset, right hemiplegia, global aphasia and progressive worsening of sensorium 12 hours after the bite. MRI of brain revealed massive left middle cerebral artery (MCA) territory infarct. The magnetic resonance angiography showed non-visualisation of left internal carotid artery (ICA) and MCA. Coagulation parameters were normal. Sudden complete occlusion of left ICA was probably secondary to cardioembolic phenomenon leading to massive infarct. Despite aggressive medical and supportive measures, she clinically worsened rapidly to Glasgow Coma Scale of 3/15 over next 6 hours and succumbed to her illness the next day.

BACKGROUND

Scorpion bite-induced ischaemic infarct is rare. The mechanism of ischaemia has been attributed to disseminated intravascular coagulation (DIC) due to the coagulins present in the venom, Autonomic storm due to excess catecholamine surge leading to vasospasm of vessels. In absence of the above, cardioembolic strokes secondary to autonomic storm/catecholamine excess induced ventricular/atrial fibrillation/tachycardia could be another plausible explanation for ischaemic infarct.

Our patient did not have haematological findings suggestive of DIC. Complete non-visualisation of her unilateral left internal carotid artery (ICA) and middle cerebral artery (MCA) cannot be attributed to catecholamine-induced vasospasm either. Hence, we propose acute cardioembolic occlusion of left ICA as the cause of stroke. This mechanism has been rarely reported as the cause of infarct in patients with scorpion bite in the past.

CASE PRESENTATION

A 54-year-old woman from rural India, with no premorbid illnesses, presented with history of scorpion bite to tip of digit 3 of left hand, in the morning just after getting up from sleep. The Indian red scorpion was immediately captured and killed. She was immediately shifted to the hospital. Her vitals were stable. She was immediately administered prazosin, intravenous antihistaminics, intravenous atropine, analgesics, anxiolytic (diazepam), anti-inflammatory medications and intravenous fluids. Routine blood tests including coagulation parameters were normal. There were no abnormal findings on her systemic examination.

Three hours after admission, the patient developed dyspnoea at rest associated with palpitation. There was sinus tachycardia (heart rate 128 per min regular). She also had hypotension

(BP was 70 systolic). The possibility of myocarditis was thought of. ECG showed sinus tachycardia with short RR interval and ST segment elevations in V1-V3 (figure 1). Creatine kinase MB isoenzyme levels were elevated and quantitative Troponin-T was normal. Two-dimensional echocardiography did not show any features suggestive of myocarditis.

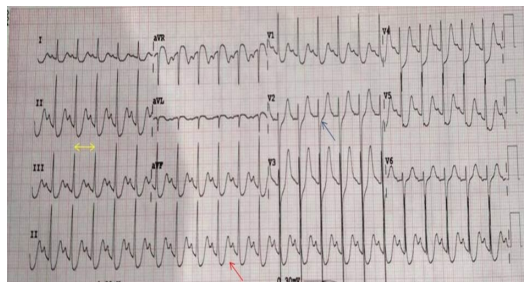


Figure 1 ECG showing sinus tachycardia with short RR interval, ventricular premature complexes and raised ST segment.

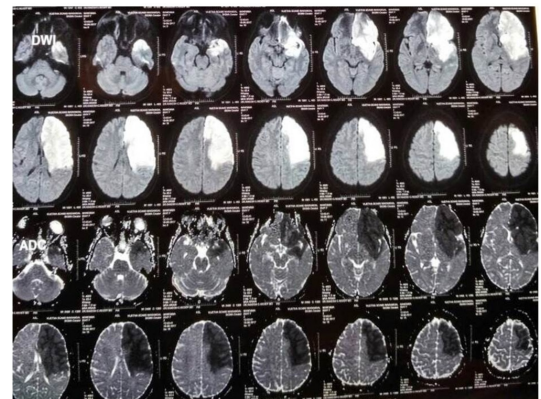
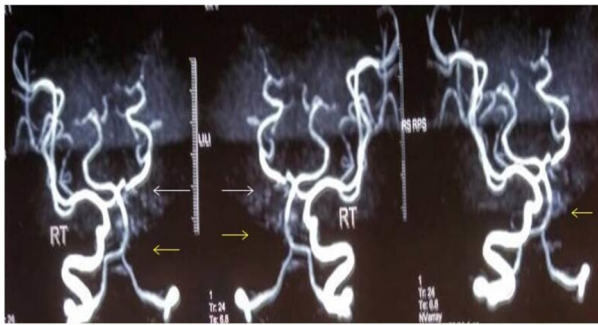

Figure 2 MRI of brain showed large middle cerebral artery territory ischaemic stroke involving the cortical and subcortical areas.



To cite: Reddy C R, Bompelli N, Khardenavis V, et al. *BMJ Case Rep* Published Online First: [please include Day Month Year]. doi:10.1136/bcr-2017-221606



Non-visualisation of left internal carotid artery (yellow arrow) and left middle cerebral artery (white arrow)

Figure 3 Magnetic resonance angiography showed complete non-visualisation of left internal carotid artery and middle cerebral artery.

The symptoms were therefore attributed to sudden catecholamine surge, a known entity in scorpion bite.

Eight hours after this event, the patient developed paucity of movements on the right half of the body with global aphasia associated with increased drowsiness. To rule out stroke, MRI of brain with magnetic resonance angiography (MRA) was done.

MRI of brain showed large MCA territory ischaemic stroke involving the cortical and subcortical areas (figure 2). MRA showed complete non-visualisation of left ICA and MCA (figure 3).

After loading dose of aspirin (325 mg), the patient was started on dual antiplatelets (Aspirin 150+ Clopidogrel 75), antioedema measures (intravenous mannitol, furosemide). Bilateral carotid Doppler showed diffuse atheromatous changes in left ICA with no significant stenosis.

Over the next few hours, she again developed sudden onset hypotension with ventricular tachycardia and cardiac arrest. She was revived with cardiac pulmonary resuscitation for 15 min with Cardio-version (360J) subsequently. Postresuscitation, the patient was comatose with Glasgow Coma Scale of 3/15. Pupils were 4 mm equal, fixed and dilated.

Two hours later, she went into sudden cardiac arrest and could not be revived.

INVESTIGATIONS

Included in 'Case Presentation' section.

TREATMENT

Included in 'Case Presentation' section.

OUTCOME AND FOLLOW-UP

The patient succumbed to her illness.

DISCUSSION

Indian red scorpion (*Mesobuthus tumulus*) bite is usually more commonly associated with cardiovascular complications, but neurological complications, of which intracranial haemorrhages and cerebral infarction are common.¹ Scorpion venom consists of free amino acids, serotonin, hyaluronidase and enzymes that act on trypsinogen.²

The venom alters the voltage-dependent ion channels. The positive charge on the side chains of scorpion venom helps them attach to voltage-gated sodium or potassium channel. The channel selectivity of the toxin varies from one species to

other producing the toxin. The presynaptic opening of sodium channel with inhibition of calcium dependant potassium channels triggers the 'autonomic storm'.³

Clinical features such as raised blood pressure, increased heart rate, myocardial dysfunction, pulmonary oedema are attributed to alpha receptor stimulation.^{4,5} Increased catecholamine levels cause accumulation of endothelins and hence vasoconstriction.^{6,7}

Pathophysiology of stroke in scorpion poisoning has been attributed to various mechanisms:

1. Autonomic storm induced sudden surge in blood pressure causing rupture of perforators.
2. Myocarditis induced cardioembolic stroke.
3. Venom induced DIC causing increased platelet aggregation.
4. (Venom induced vasculitis caused by endothelial damage.
5. Hypotension induced watershed infarcts.
6. Catecholamine excess induces increased endothelin resulting in vasoconstriction.^{8,9}

The most likely mechanism of infarct could have been cardioembolic in our case because:

1. The cerebral vascular event was preceded by myocarditis and tachyarrhythmia.
2. There is selective unilateral complete occlusion of ICA and MCA on the left side only, which is less common in vasospasm. Unilateral endothelial damage-induced platelet aggregation causing thrombosis also is a less probable mechanism in this case.

The case fatality rate in case of scorpion bite is between 3% and 22%¹⁰ and despite of best of efforts, our patient succumbed to her illness.

Learning points

- ▶ Scorpion bite-associated stroke is uncommon. It may manifest as intracranial bleed or ischaemic infarct.
- ▶ Voltage-dependent ionic channels are the target of scorpion venom.
- ▶ Case fatality can significantly increase in presence of complications and multisystem involvement.

Contributors RRC and NB made substantial contributions to the conception and design of the work, acquisition, analysis and interpretation of the data. VK and AD were involved in drafting the work and revising it critically for important intellectual content. AD approved the final version to be published.

Competing interests None declared.

Patient consent Obtained.

Provenance and peer review Not commissioned; externally peer reviewed.

© BMJ Publishing Group Ltd (unless otherwise stated in the text of the article) 2017. All rights reserved. No commercial use is permitted unless otherwise expressly granted.

REFERENCES

1. Del Brutto OH. Neurological effects of venomous bites and stings: snakes, spiders, and scorpions. *Handb Clin Neurol* 2013;114:349–68.
2. Basu A, Gomes A, Gomes A, et al. Histamine, 5-HT & hyaluronidase in the venom of the scorpion *Lychas laevifrons* (Pock). *Indian J Med Res* 1990;92:371–3.
3. Quintero-Hernández V, Jiménez-Vargas JM, Gurrola GB, et al. Scorpion venom components that affect ion-channels function. *Toxicol* 2013;76:328–42. 23 June 2017.
4. Ellenhorn MJ, Schonwald S, Ordog G, et al. Ellenhorn's medical toxicology. In: *Diagnosis and treatment of human poisoning*. Baltimore: Williams and Wilkins, 1997:1738. Natural toxins.
5. Bahloul M, Ben Hamida C, Chtourou K, et al. Evidence of myocardial ischaemia in severe scorpion envenomation. *Intensive Care Med* 2004;30:461–7.
6. Bawaskar HS, Bawaskar PH. Management of the cardiovascular manifestations of poisoning by the Indian red scorpion (*Mesobuthus tamulus*). *Heart* 1992;68:478–80.

7. Gueron M, Adolph RJ, Grupp IL, *et al.* Hemodynamic and myocardial consequences of scorpion venom. *Am J Cardiol* 1980;45:979–86.
8. Thacker AK, Lal R, Misra M. Scorpion bite and multiple cerebral infarcts. *Neurol India* 2002;50:100.
9. Eze C, Onwuekwe I, Ekenze O. Stroke as a rare consequence of scorpion sting and scorpion ingestion: a case report from South East Nigeria. *Annals of Tropical Medicine and Public Health* 2014;7:202.
10. Isbister GK, Bawaskar HS. Scorpion Envenomation. *N Engl J Med Overseas Ed* 2014;371:457–63. 371.

Copyright 2017 BMJ Publishing Group. All rights reserved. For permission to reuse any of this content visit <http://group.bmj.com/group/rights-licensing/permissions>.

BMJ Case Report Fellows may re-use this article for personal use and teaching without any further permission.

Become a Fellow of BMJ Case Reports today and you can:

- ▶ Submit as many cases as you like
- ▶ Enjoy fast sympathetic peer review and rapid publication of accepted articles
- ▶ Access all the published articles
- ▶ Re-use any of the published material for personal use and teaching without further permission

For information on Institutional Fellowships contact consortiasales@bmjgroup.com

Visit casereports.bmj.com for more articles like this and to become a Fellow